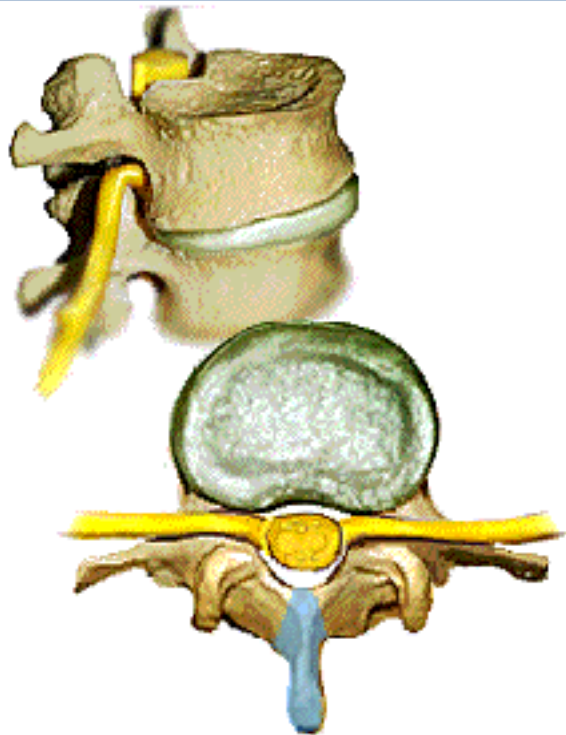


# Κατάγματα & Εξαρθρήματα της Σπονδυλικής Στήλης

Διευθ: Καθ. ΚΝ. Μαλίζος

# ΑΝΑΤΟΜΙΑ ΣΠΟΝΔΥΛΙΚΗΣ ΣΤΗΛΗΣ

## SIDE AND TOP VIEWS OF THE SPINE



● CHANGE VIEW

## Inside the spine

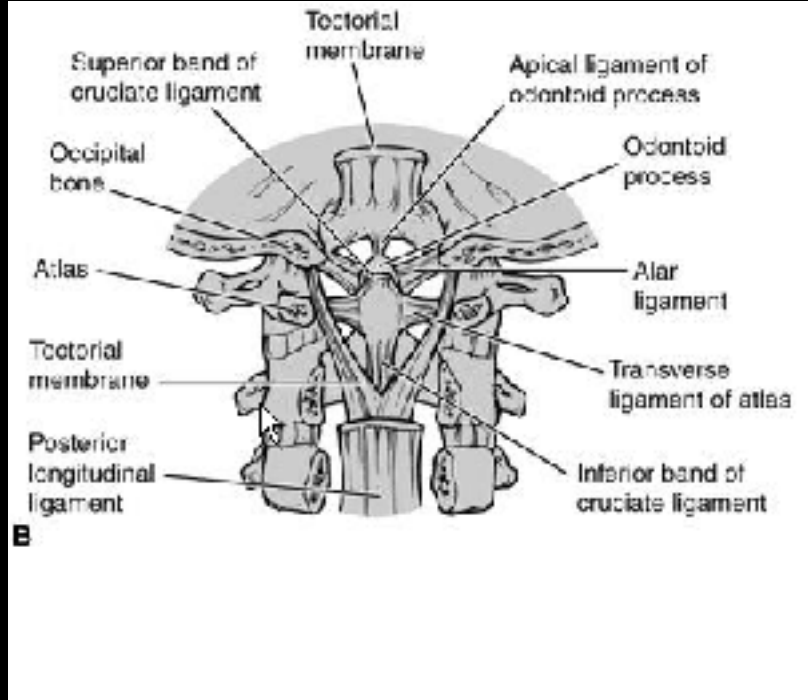
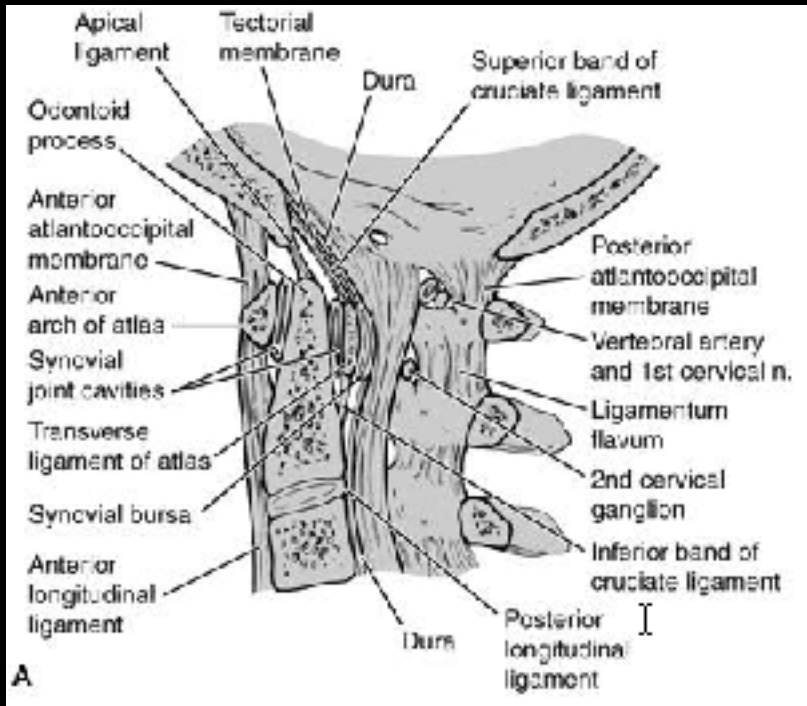
Select a part of the spine to see where it is and what it does.

- CERVICAL
- THORACIC
- LUMBAR
- SACRUM
- COCCYX
- NERVE ROOT
- SPINAL CORD
- VERTEBRAL CANAL
- DISC
- VERTEBRA BODY
- PEDICLE
- LAMINA
- TRANSVERSE PROCESS
- SUPERIOR ARTICULAR FACET
- SPINOUS PROCESS

## SPINOUS PROCESS

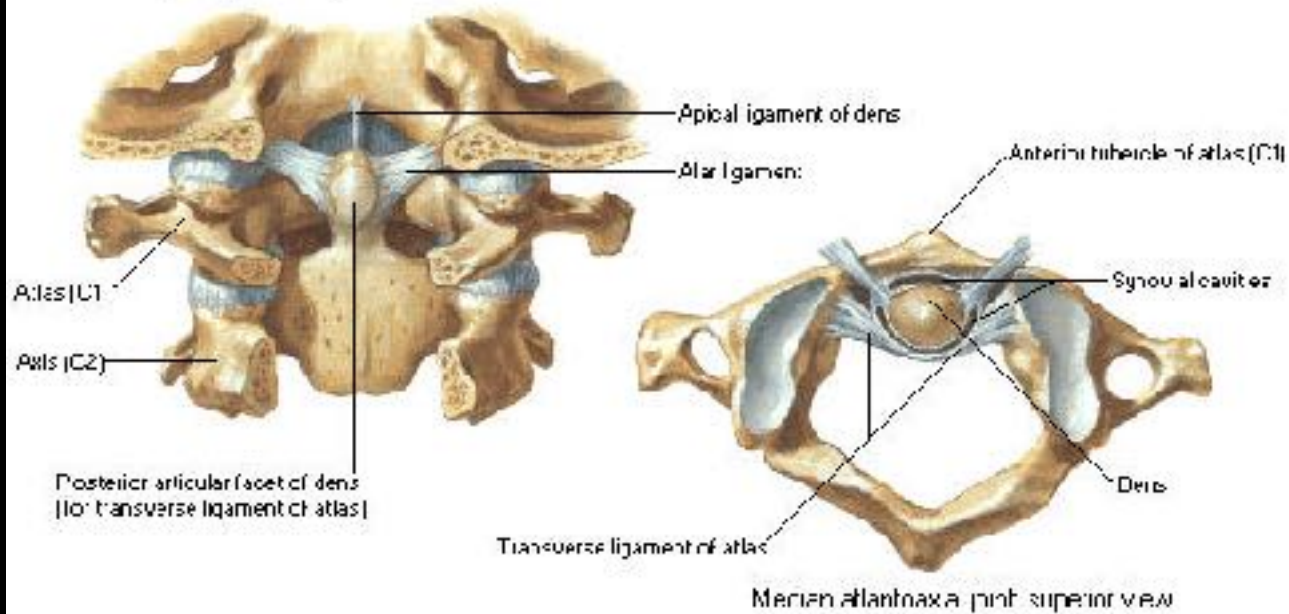
The spinous process protrudes from the back of the vertebrae. Muscles and ligaments that move and stabilize the vertebrae attach to the spinous processes.

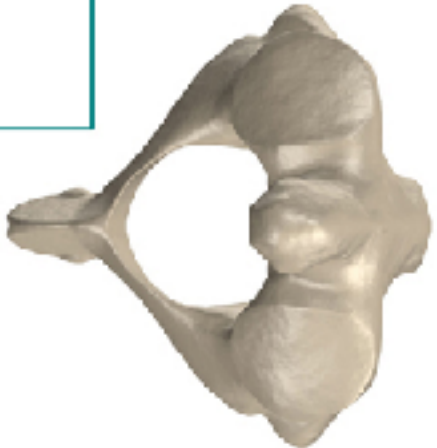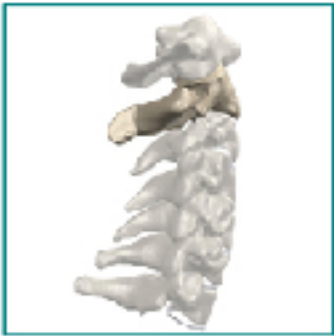
# ANATOMIA



## Internal Craniocervical Ligaments [Continued]

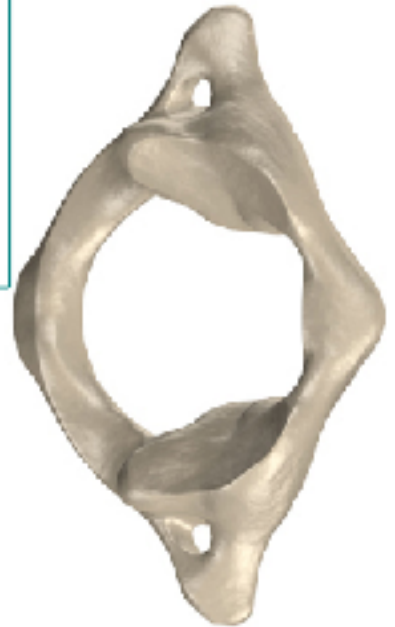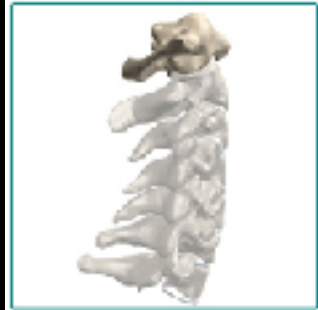Cruciate ligament removed to show deepest ligaments: posterior view





**Axis**

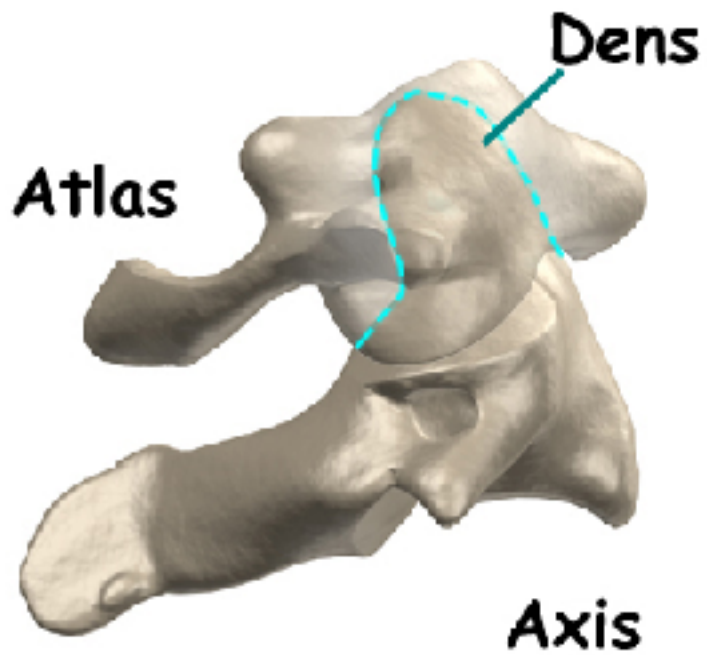
©MMG 2002



**Atlas**

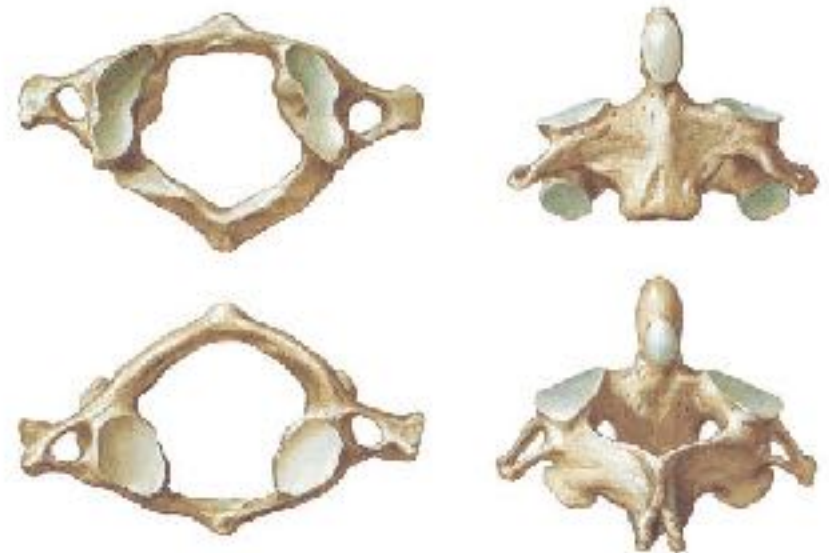©MMG 2002

# ANATOMIA



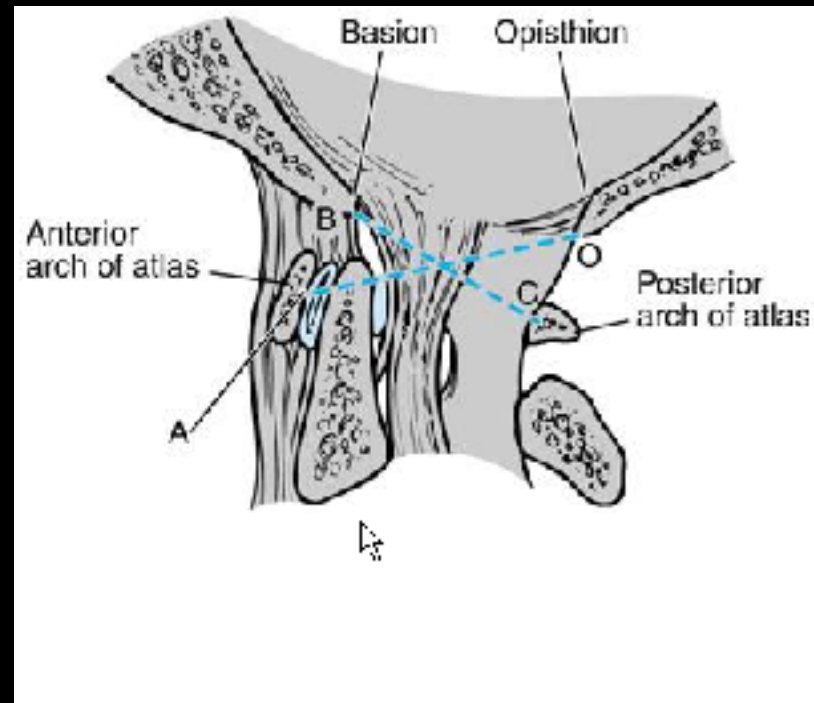
© MMG 2003

**Cervical Vertebrae**  
Atlas and Axis

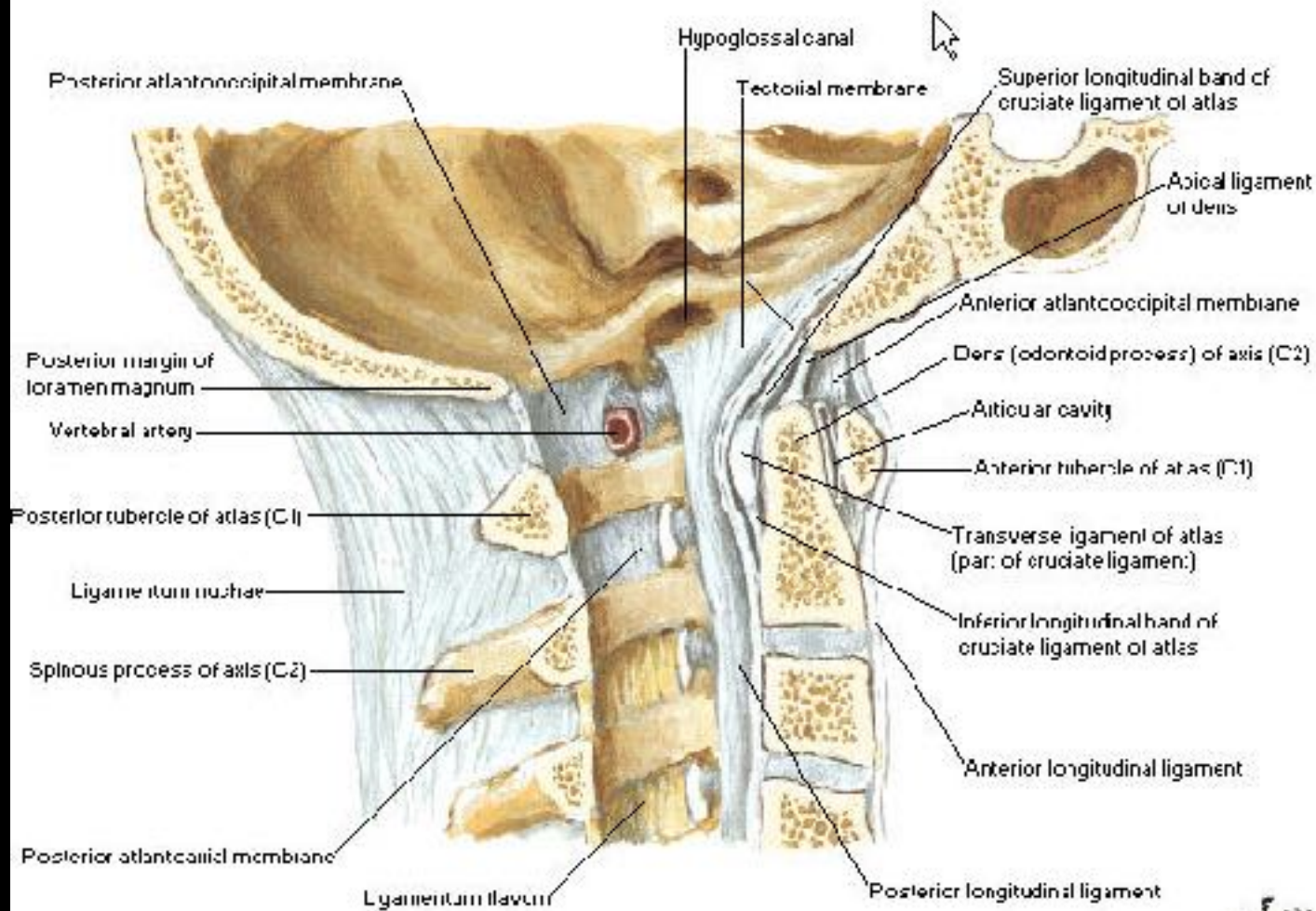


*Joan*  
Wright

# ANATOMIA

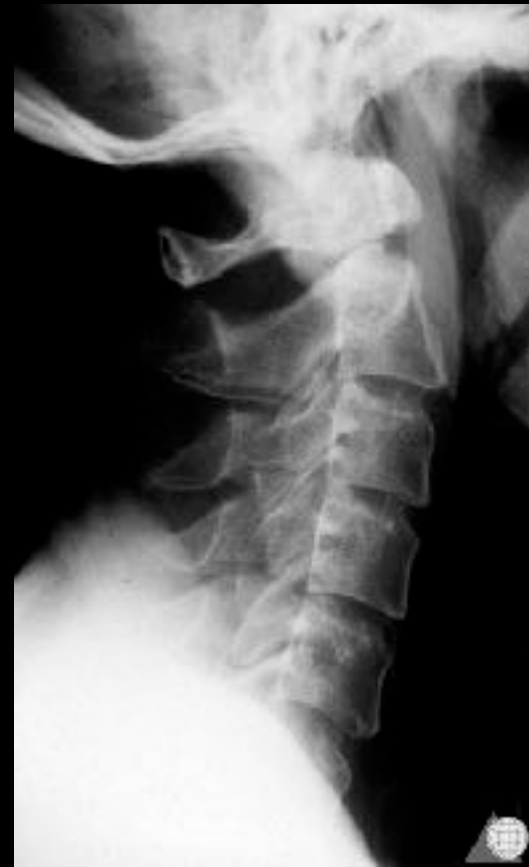
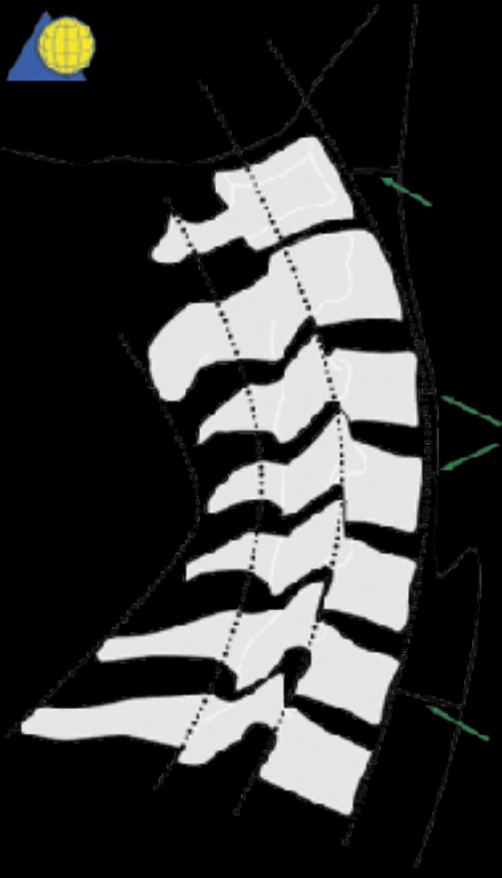
# Atlantooccipital Junction

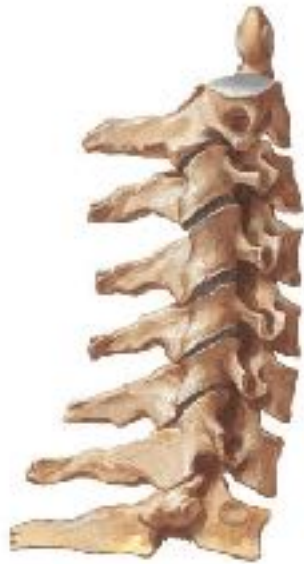



# ANATOMIA

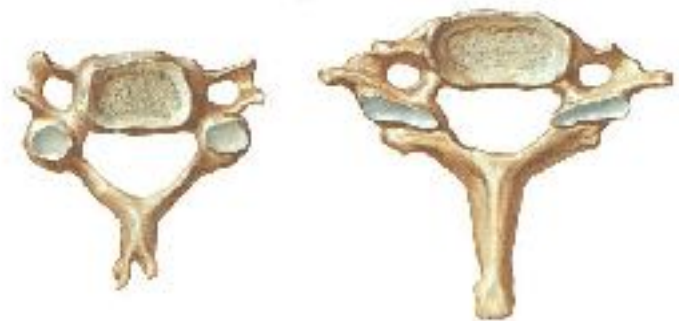

**Cervical Vertebrae [C2 - T1], Assembled**  
Right Lateral View



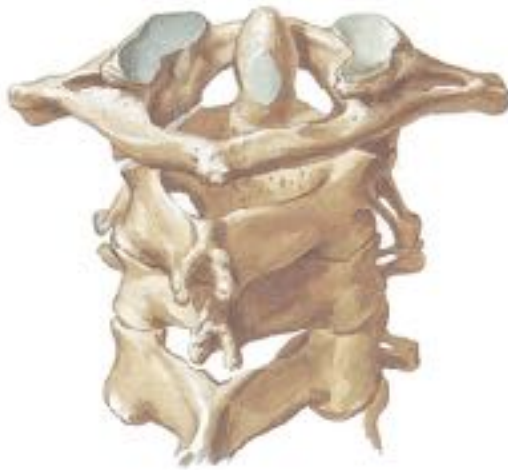*W. H. Schaefer*  
1886

**Cervical Vertebrae [C4 and C7]**  
Superior Views



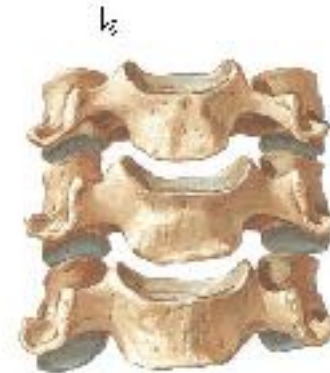*W. H. Schaefer*  
1886

**Cervical Vertebrae [C1-4], Assembled**  
Posterosuperior View



*Handwritten signature*

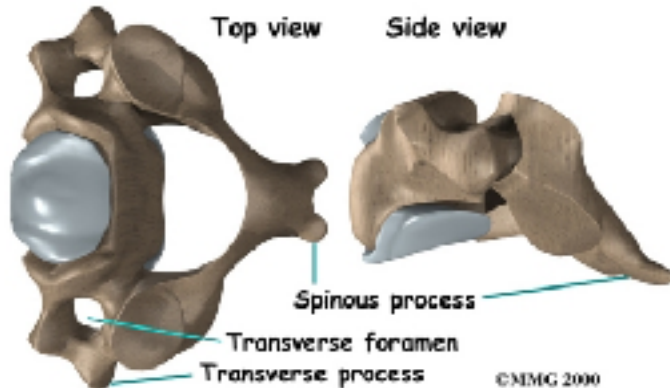
**Cervical Vertebrae [C3-5], Assembled**  
Anterior View



*Handwritten signature*

**Third cervical vertebra**

Top view      Side view



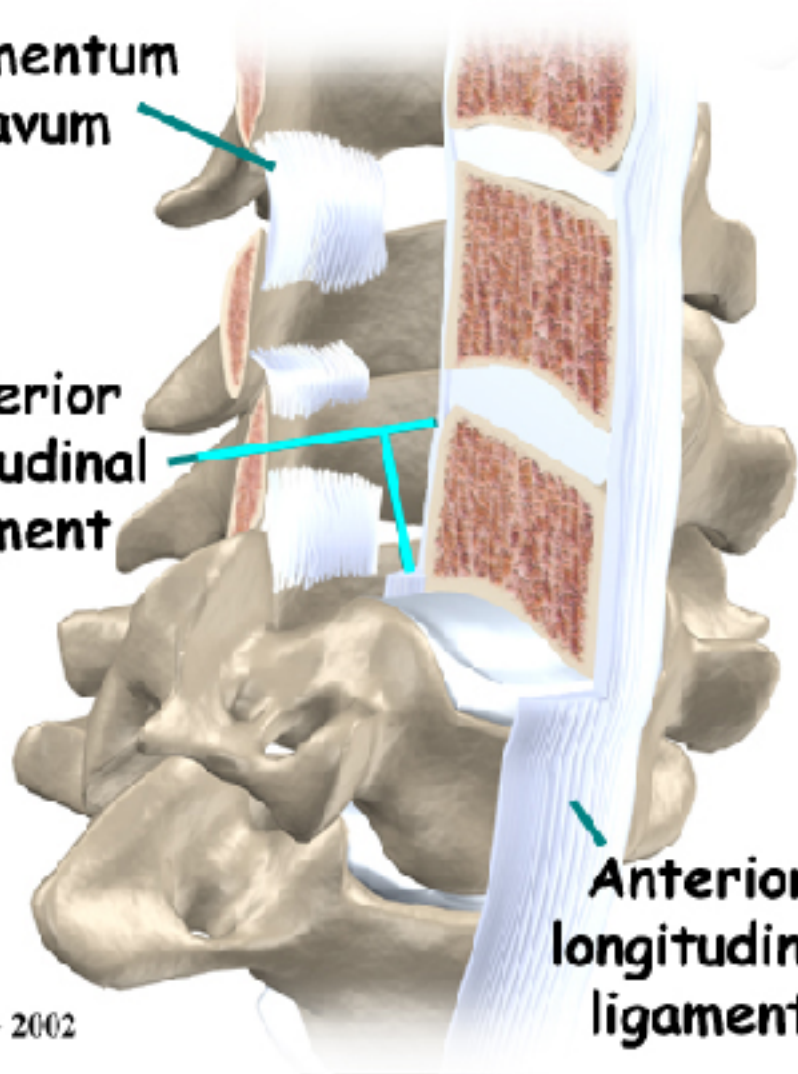
©MMG 2000

**Ligamentum  
flavum**

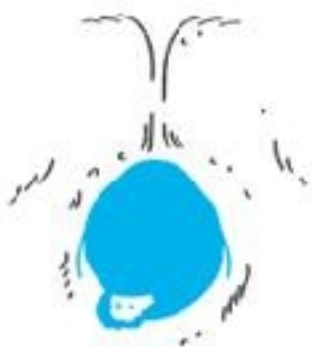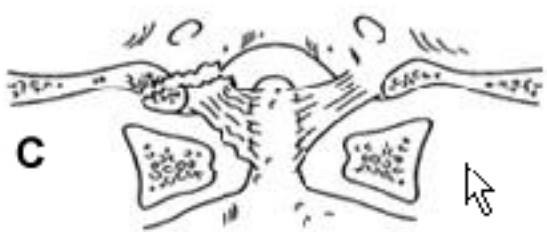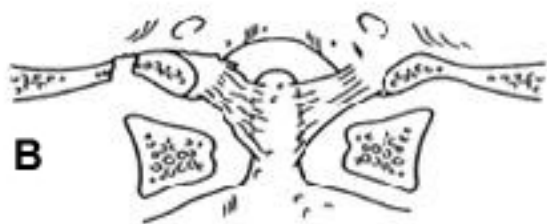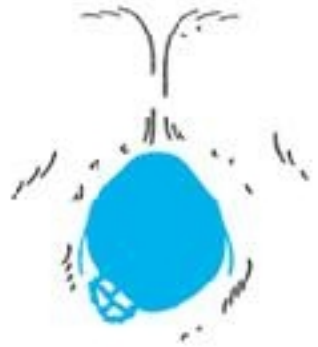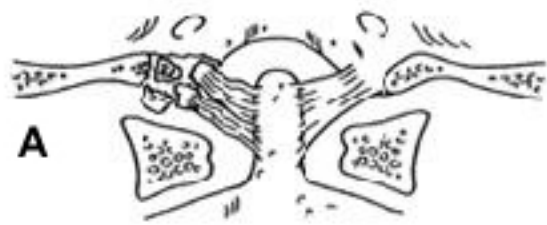**Posterior  
longitudinal  
ligament**

**Anterior  
longitudinal  
ligament**

©MMG 2002



**ΚΑΤΑΓΜΑΤΑ ΑΝΩΤΕΡΗΣ  
ΑΥΧΕΝΙΚΗΣ ΜΟΙΡΑΣ  
(C0-C2)**

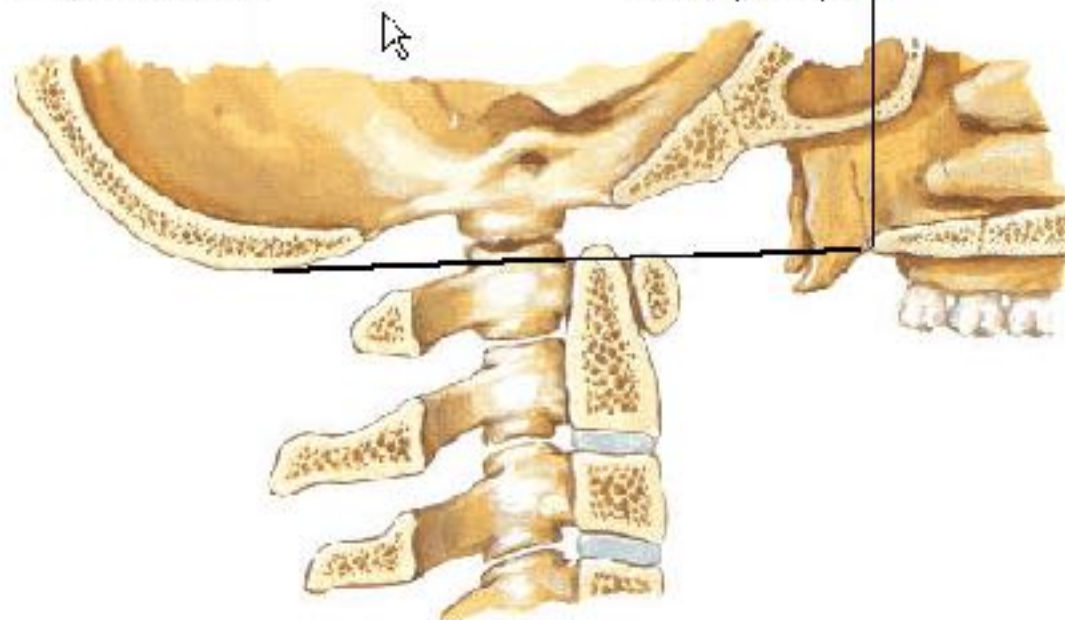


# Atlantooccipital Junction

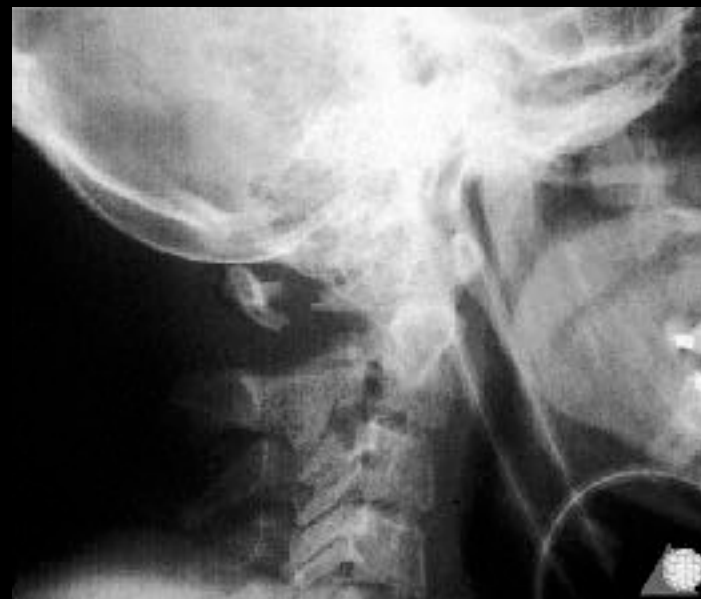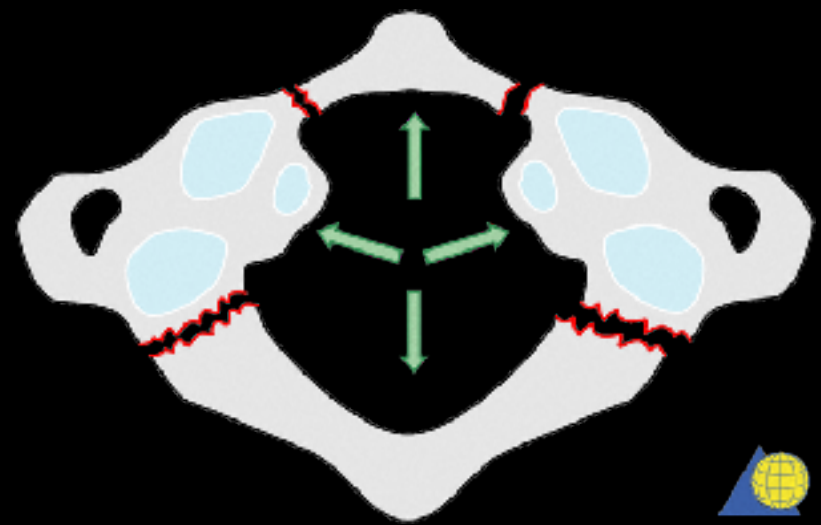
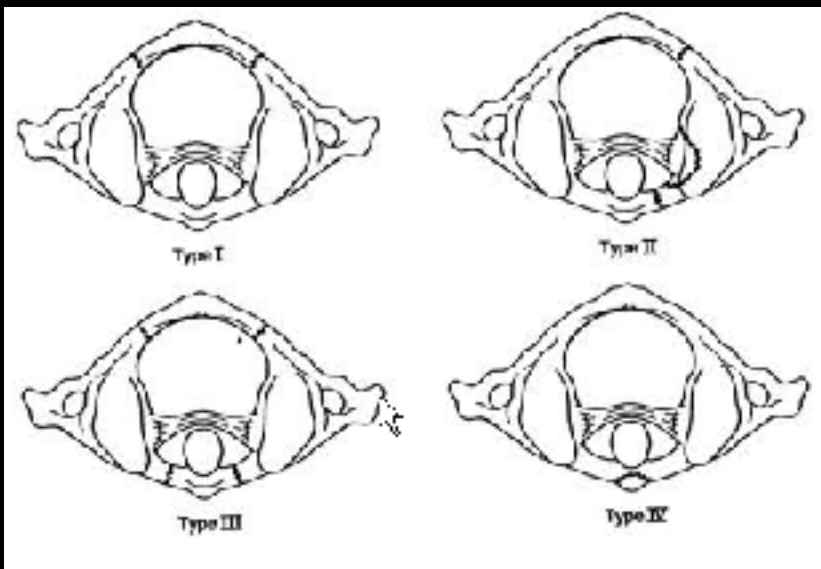
## McGregor's Line

Lowest level of occipital bone

Posterior tip of hard palate



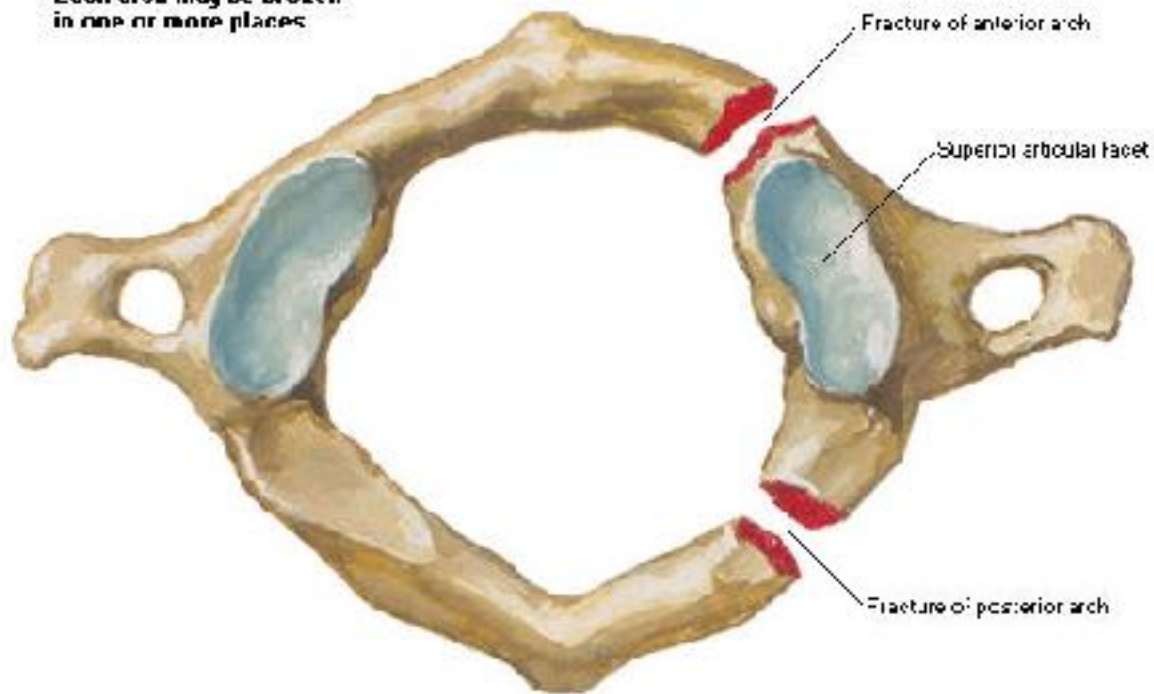
McGregor's line, from posterior tip of hard palate to lowest point of occipital bone. Average normal position of tip of dens is 1.02 mm above this line with standard deviation of plus or minus 2.6 mm as measured on a standard lateral radiograph. Tip > 4.5 mm above line is considered to indicate basilar impression.

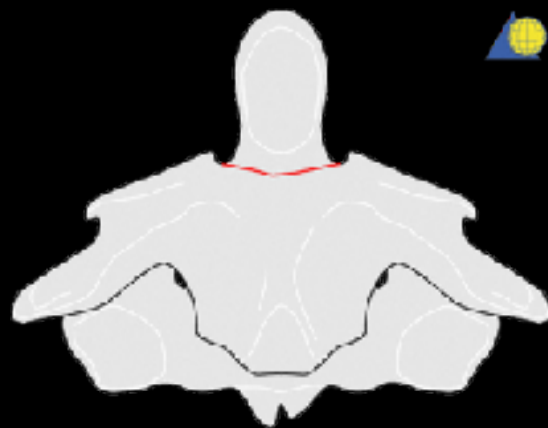
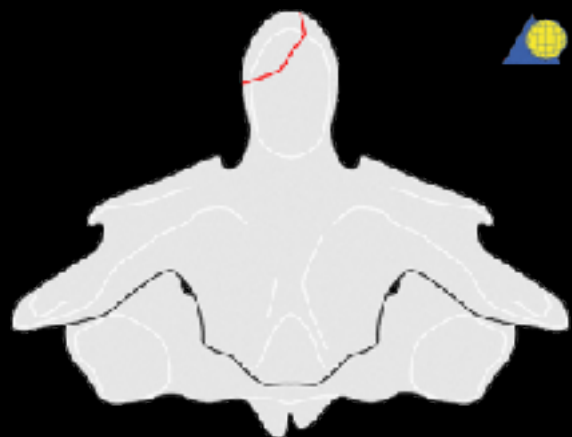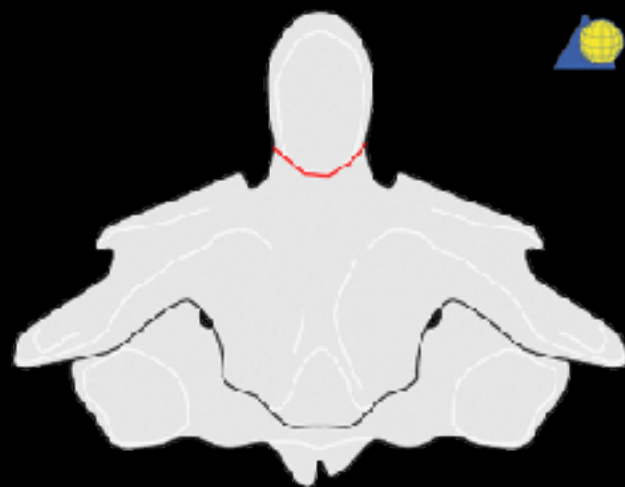
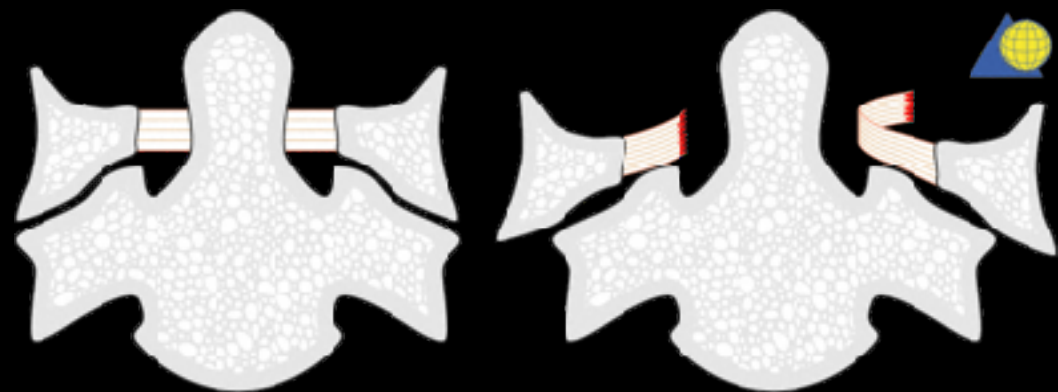


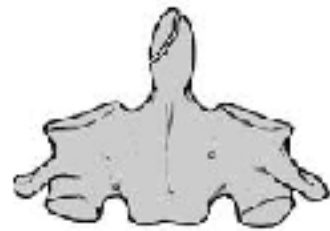


## Fractures of Atlas Jefferson Fracture

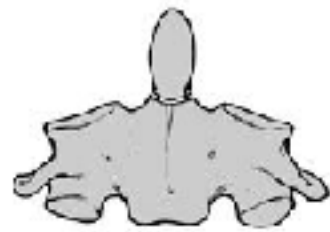
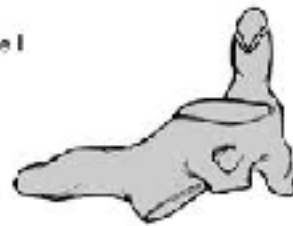
Each arch may be broken  
in one or more places



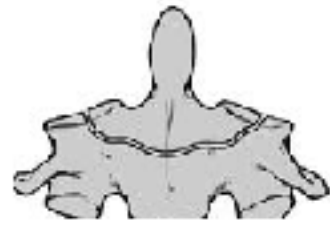
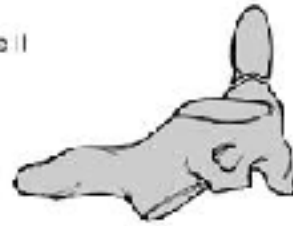



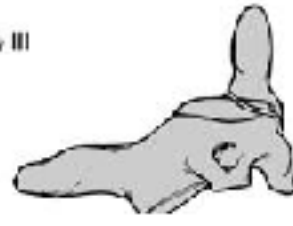
Type I



Type II

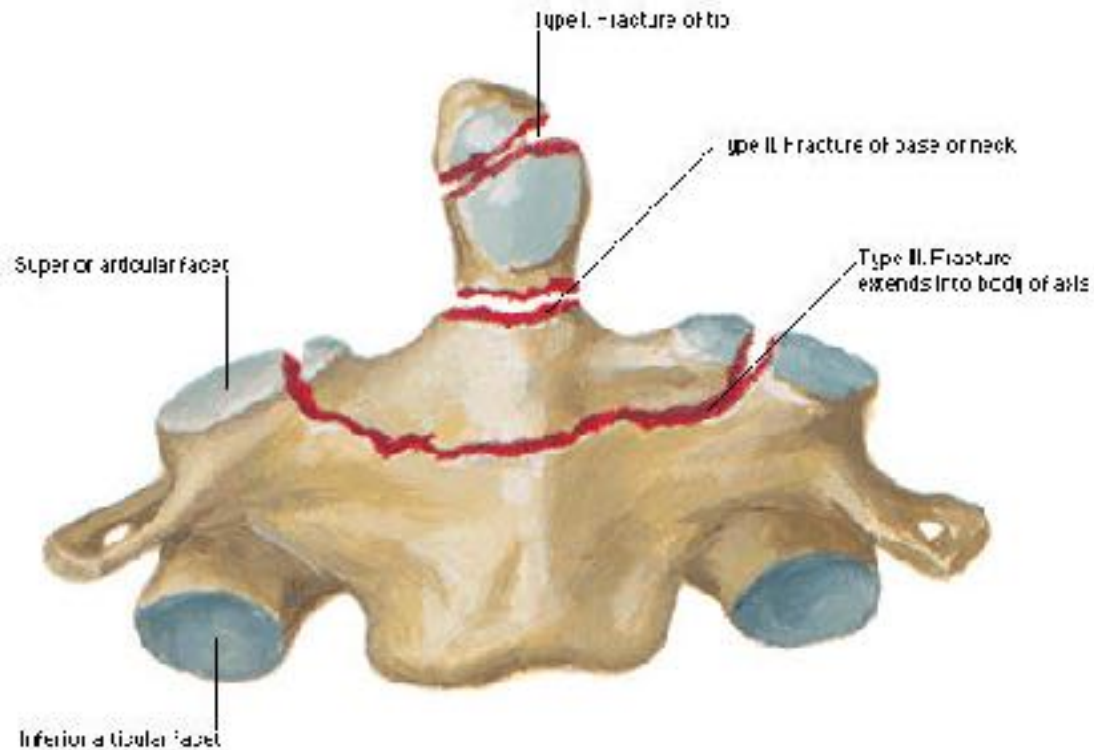


Type III



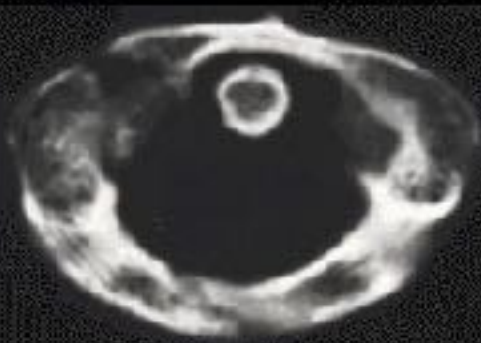
# Fractures of Axis

## Fractures of Dens - Anterior View

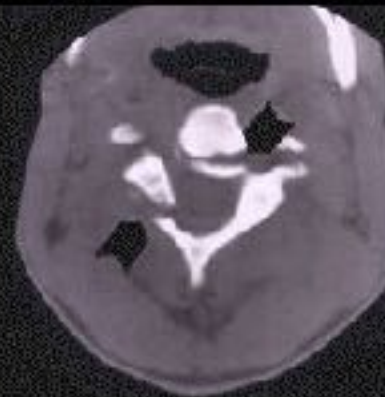


## Fractures of Atlas and Axis

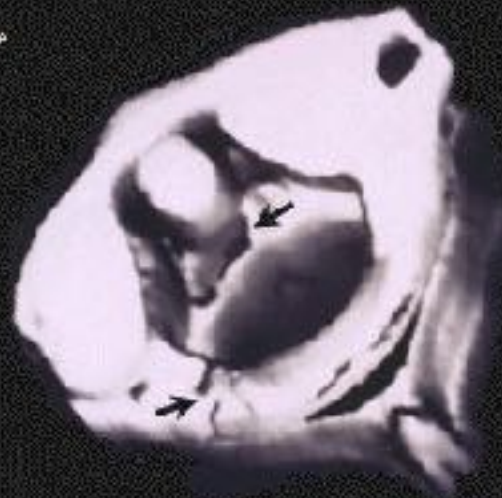CT Images - Axial Sections and Reconstruction, C1-2 Level



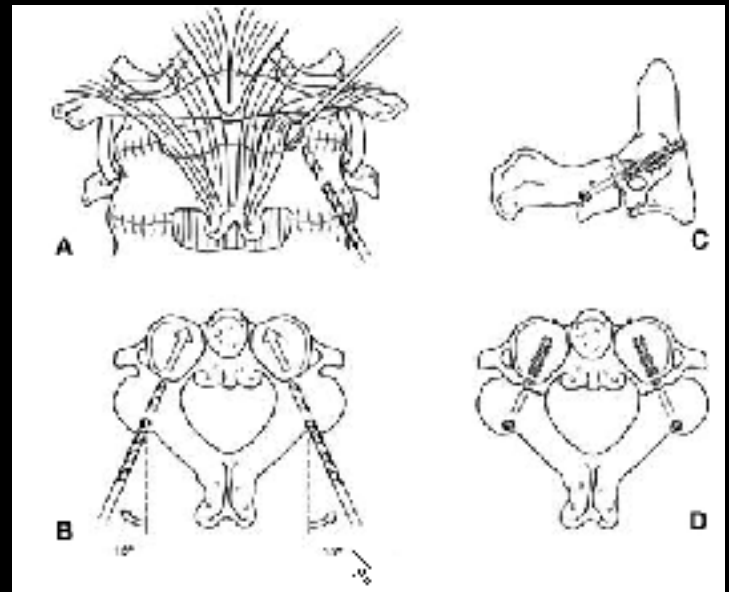
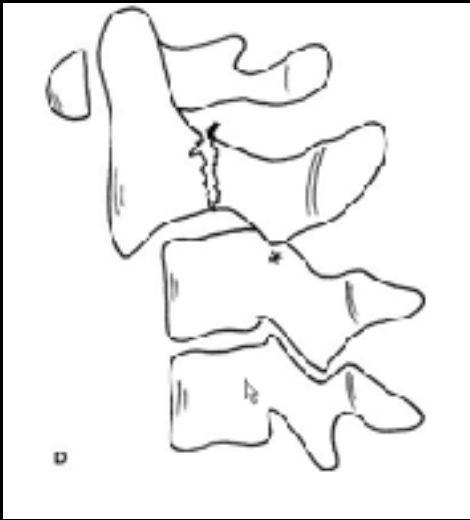
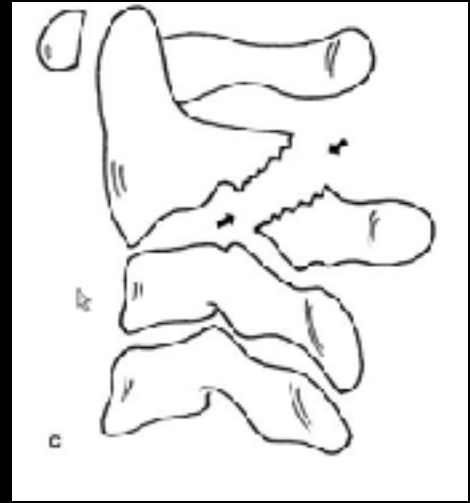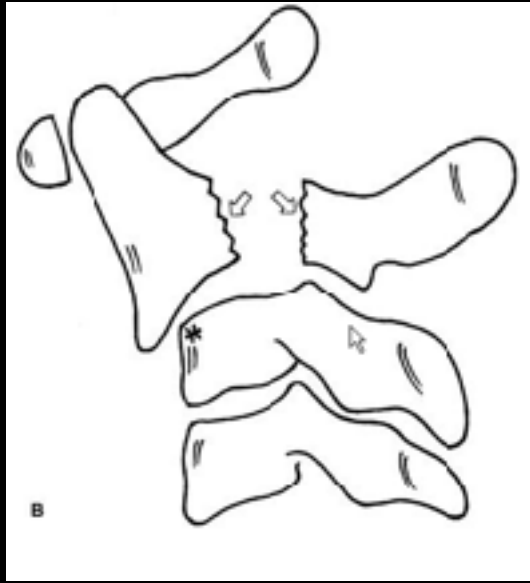
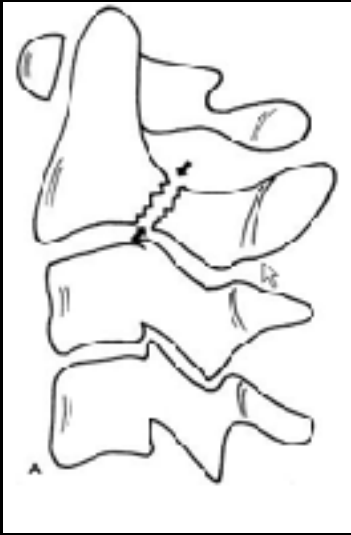
Jefferson Fracture



Hangman Fracture (bottom arrow)

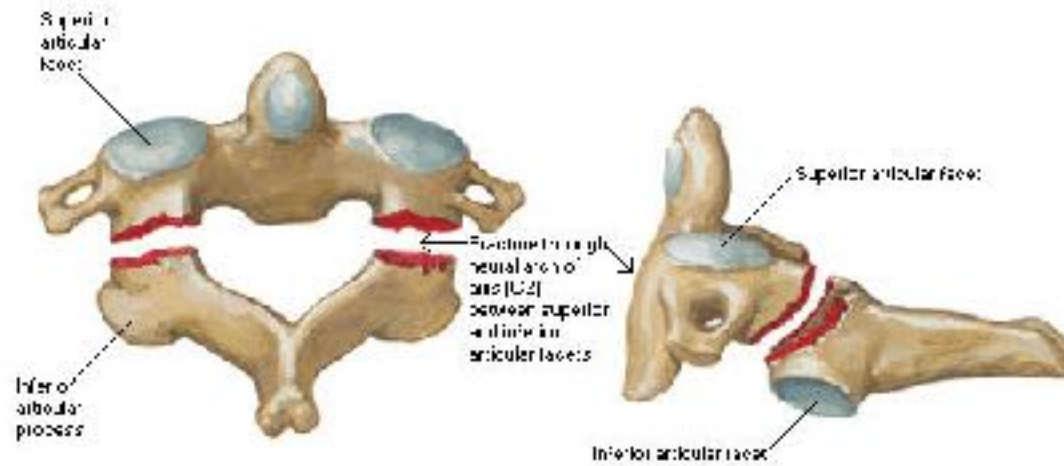


Three-line isional CT scan of type II fracture of dens combined with Jefferson fracture

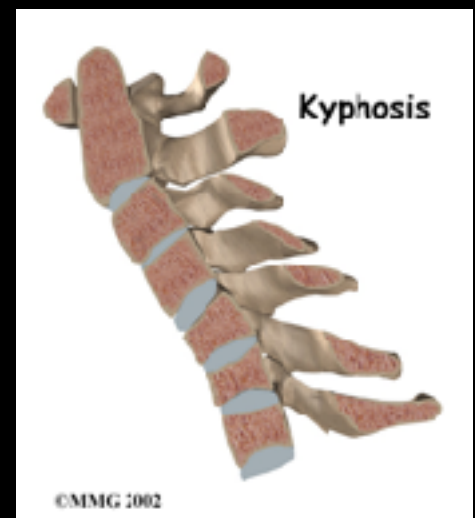
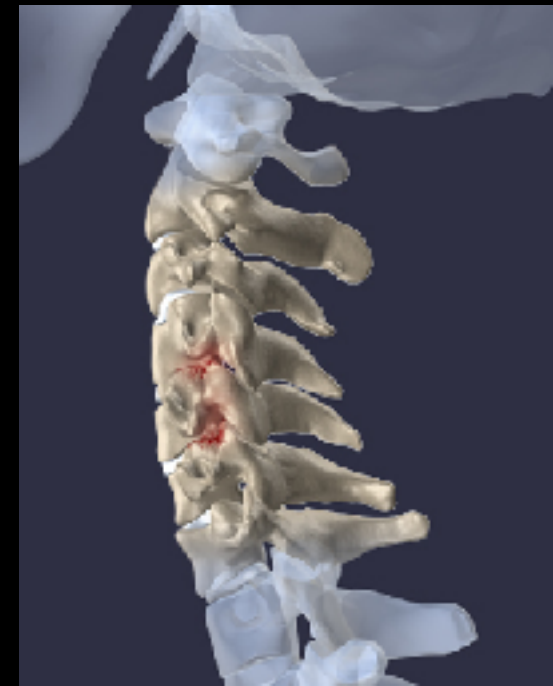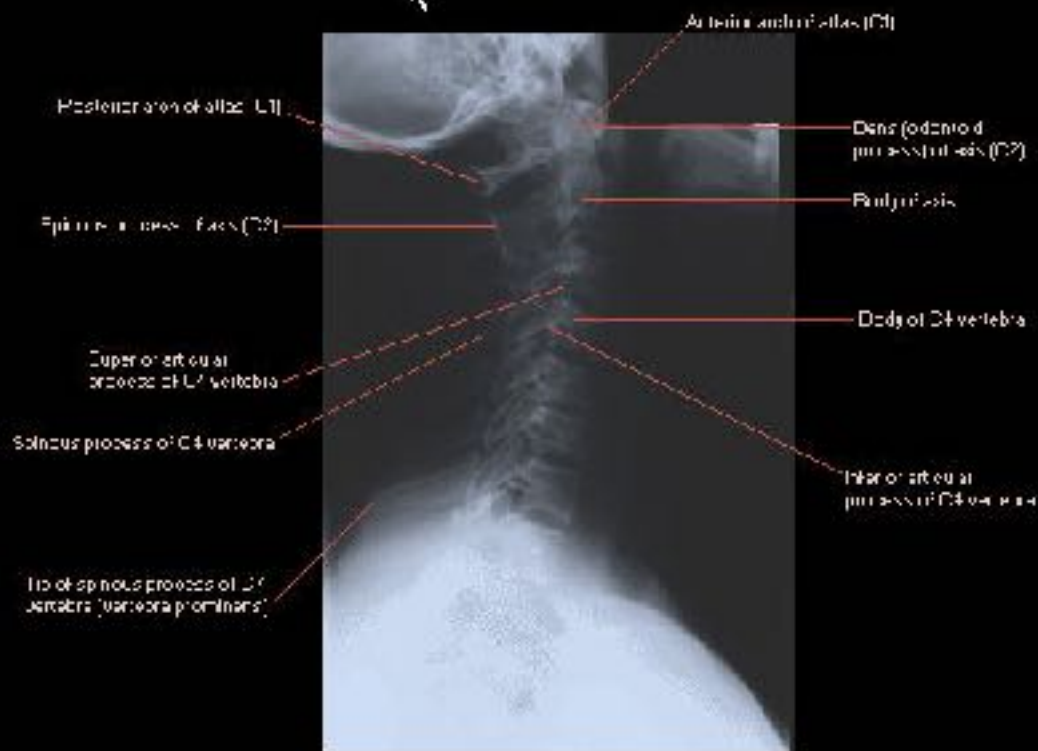


# Fractures of Atlas and Axis

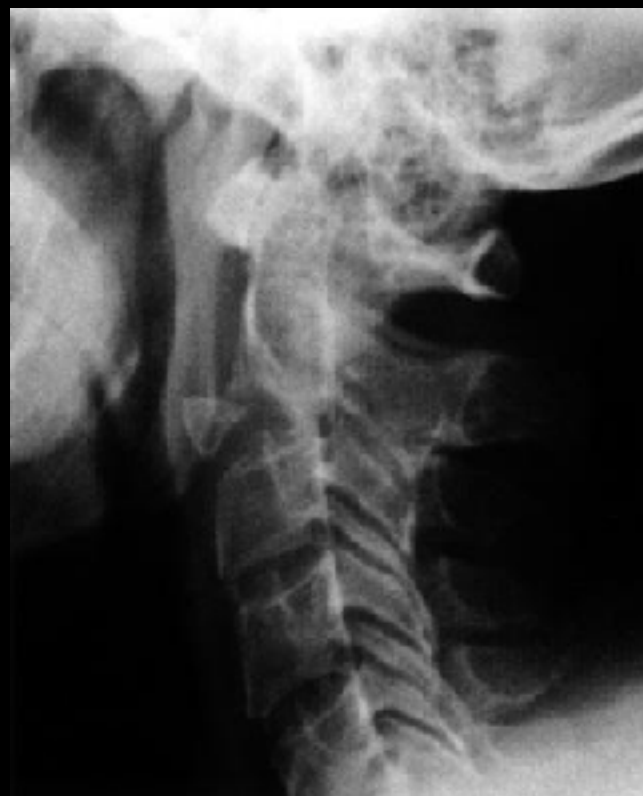## Hangman Fracture



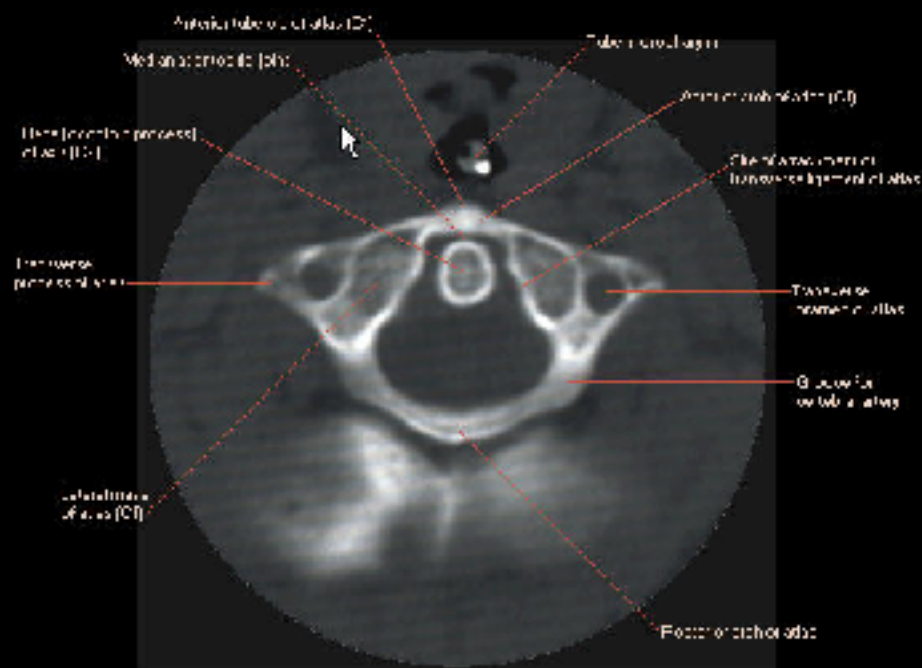
## Cervical Vertebral Column Radiograph - Right Lateral View





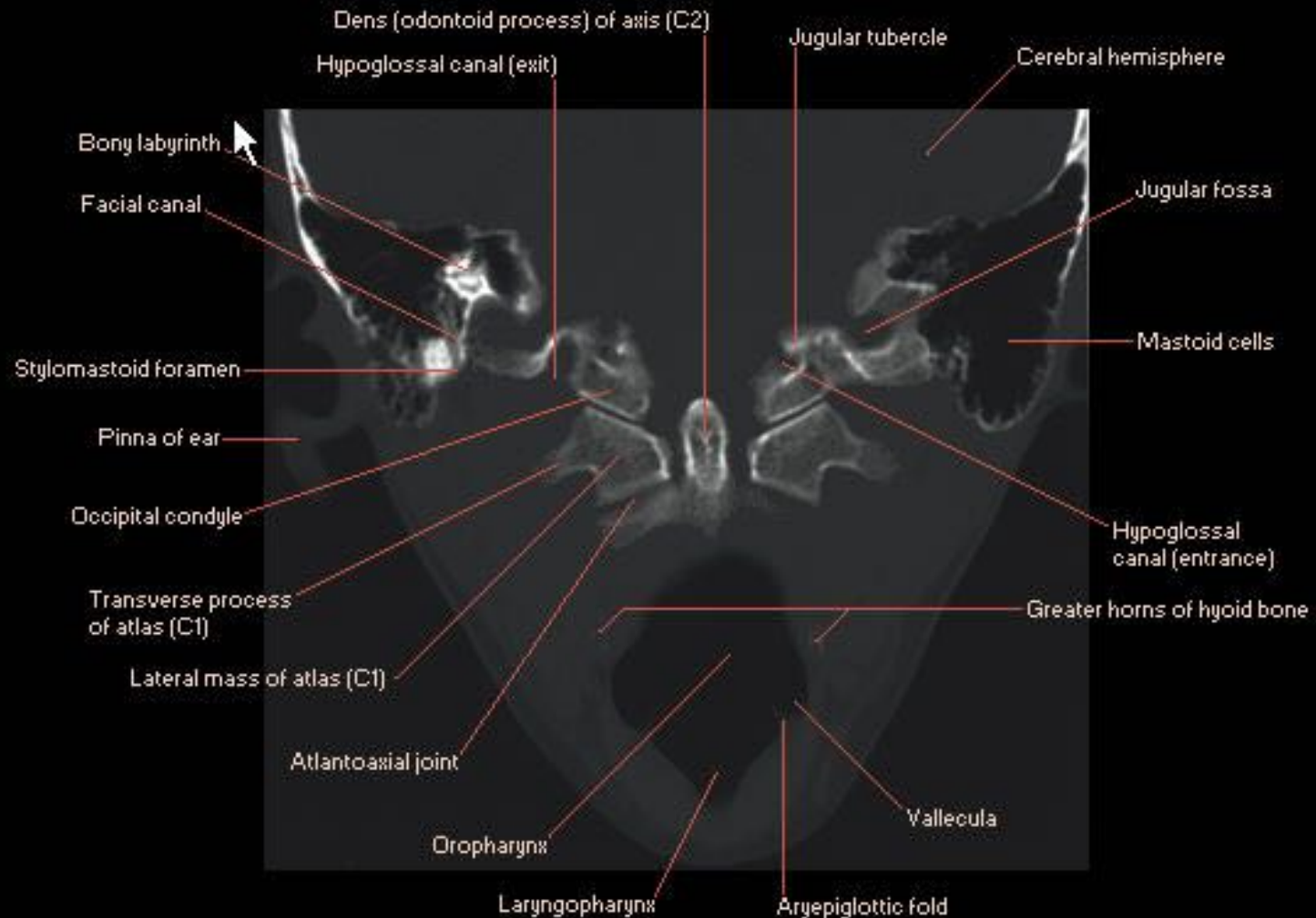


### Median Atlantoaxial Joint CT Scan - Axial Section, C1 Level



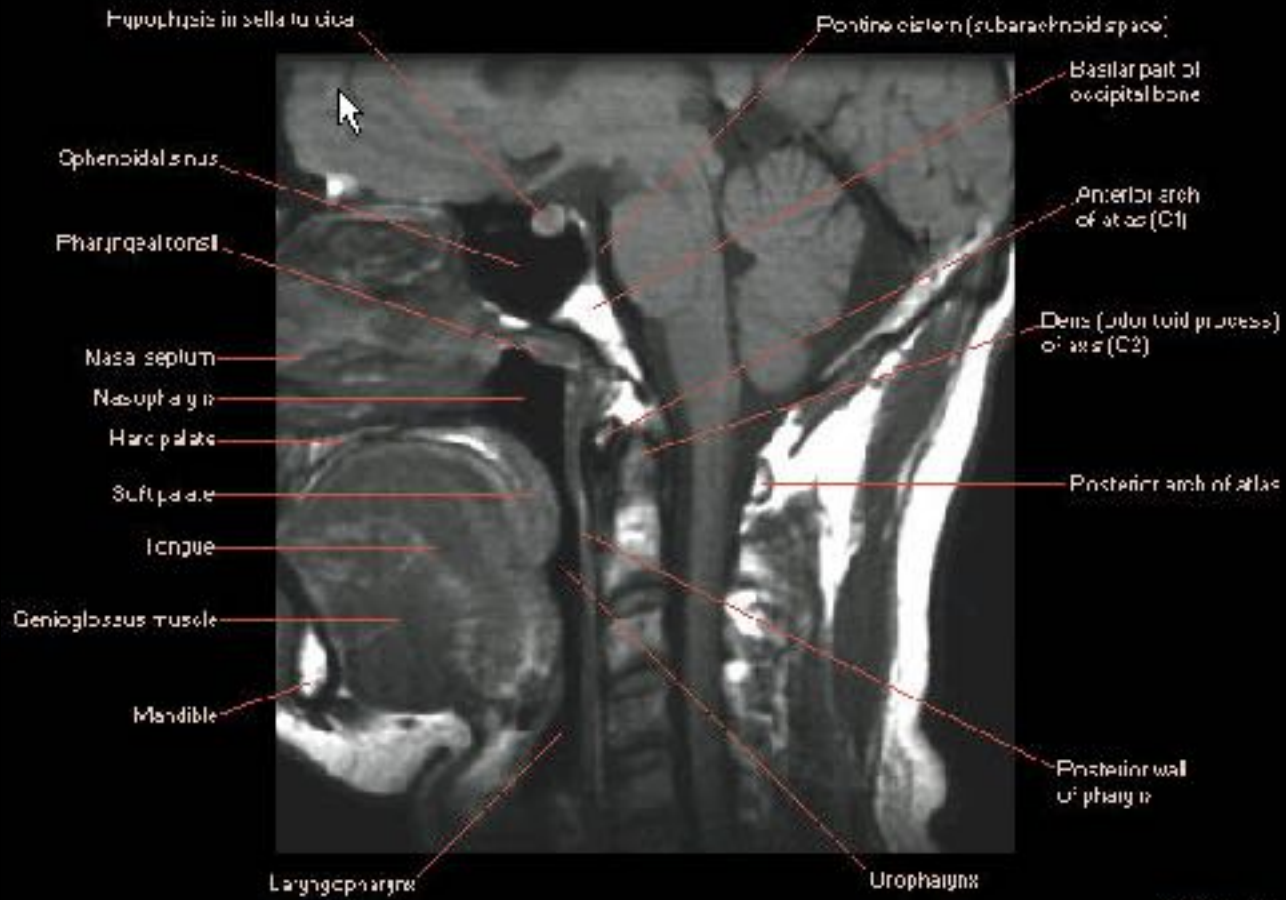
# Cranial Base - Craniovertebral Joints

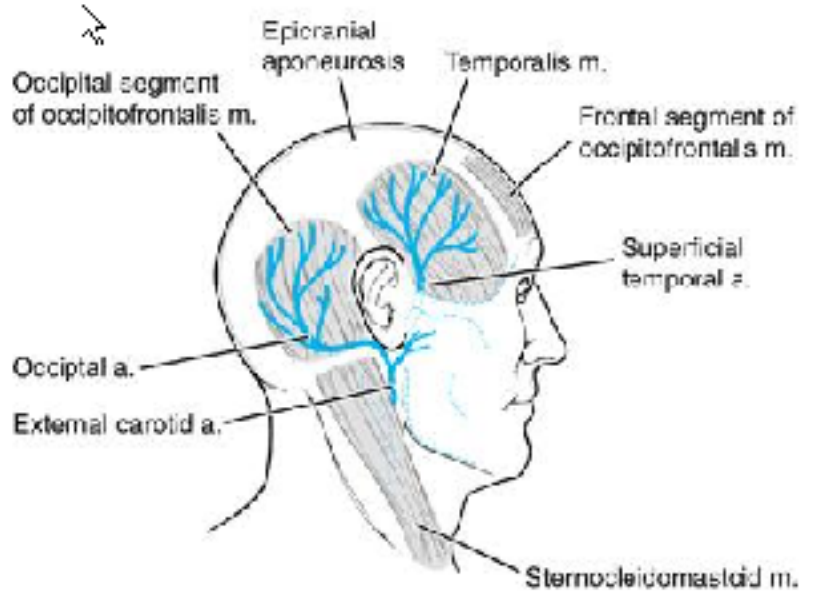
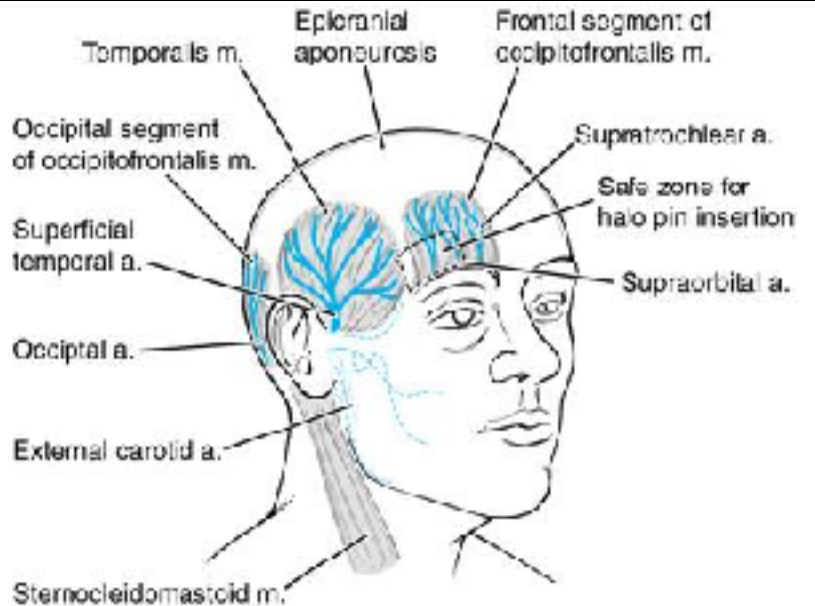
## CT Scan - Coronal Section



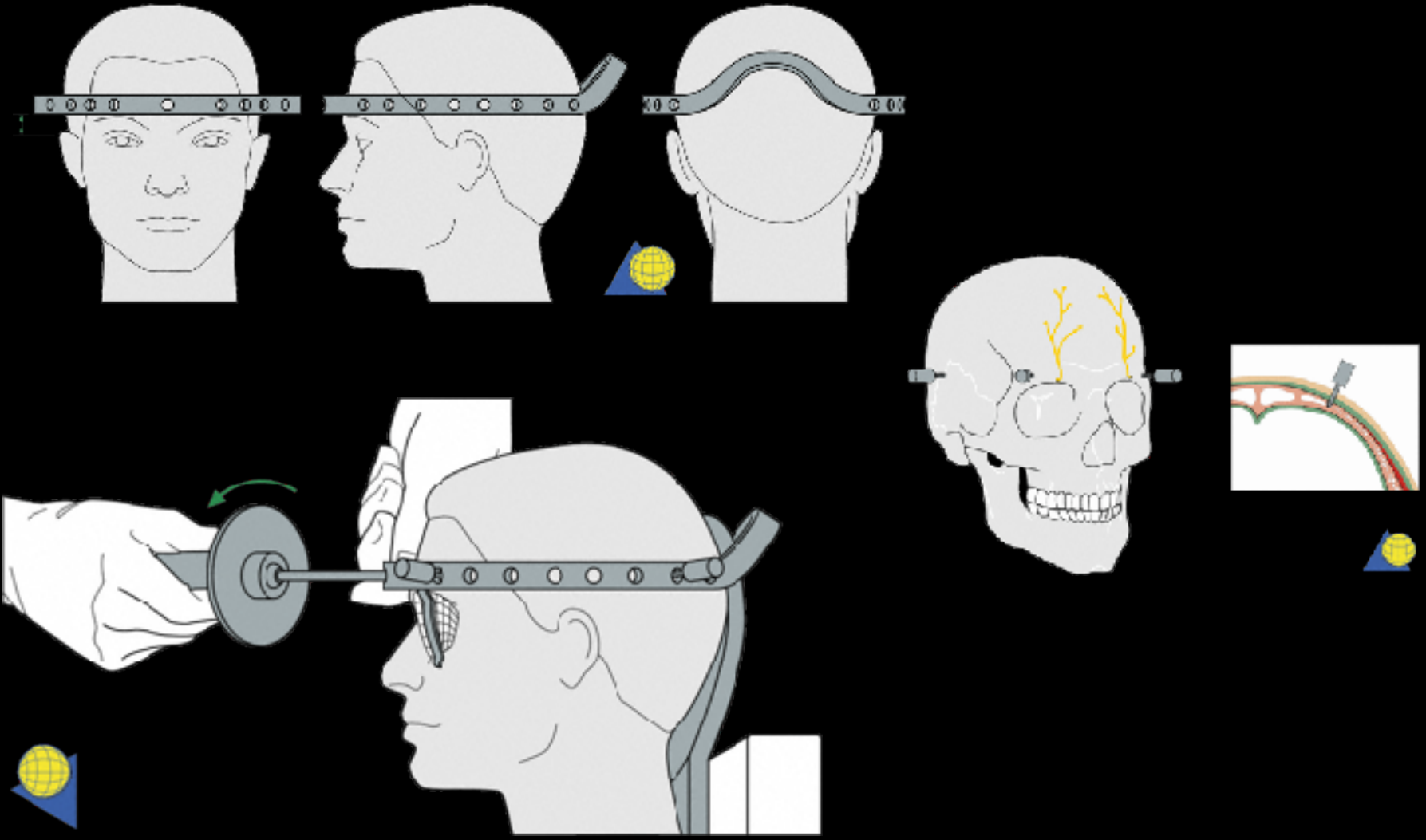
# Nasal Septum, Pharynx and Craniovertebral Joints

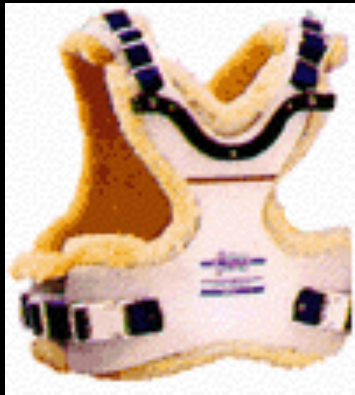## MRI - Midsagittal Section





# HALO VEST





# STANDARD NEUROLOGICAL CLASSIFICATION OF SPINAL CORD INJURY

		MOTOR Key muscles		Light touch		Pin prick		SENSORY Key muscles	
	R	L		R	L	R	L		
C2									
C3									
C4									
C5			Elbow flexors						
C6			Wrist extensors						
C7			Elbow extensors						
C8			Finger flexors						
T1			Finger abductors						
T2									
T3									
T4									
T5									
T6									
T7									
T8									
T9									
T10									
T11									
T12									
L1									
L2			Hip flexors						
L3			Knee extensors						
L4			Ankle dorsiflexors						
L5			Long extensors						
S1			Ankle plantar flexors						
S2									
S3									
S4-5									

Voluntary anal contraction (yes/no)  
 Motor score  
 Totals        
 Max: (50) (50) (100)

Arm and sensation  
 Pin prick score (max: 112)  
 Light touch score (max: 112)  
 Totals        
 Max: (56) (56) (56) (56)

**NEUROLOGICAL LEVEL**  
 The most rostral segment with normal function  
 SENSORY   R L  
 MOTOR   R L

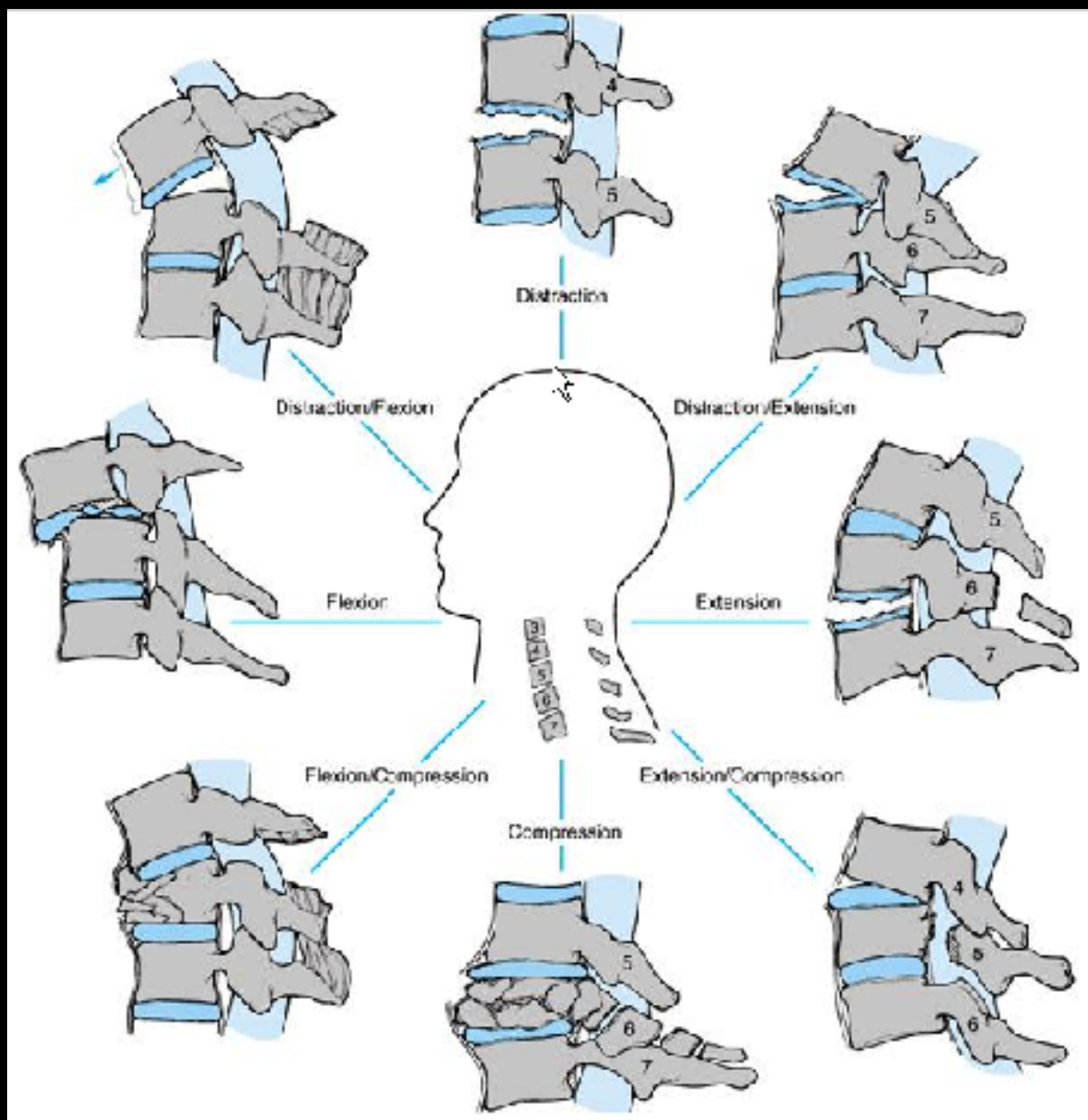
**COMPLETE OR INCOMPLETE?**   
 (complete = presence of any sensory or motor function in lowest sacral segment)

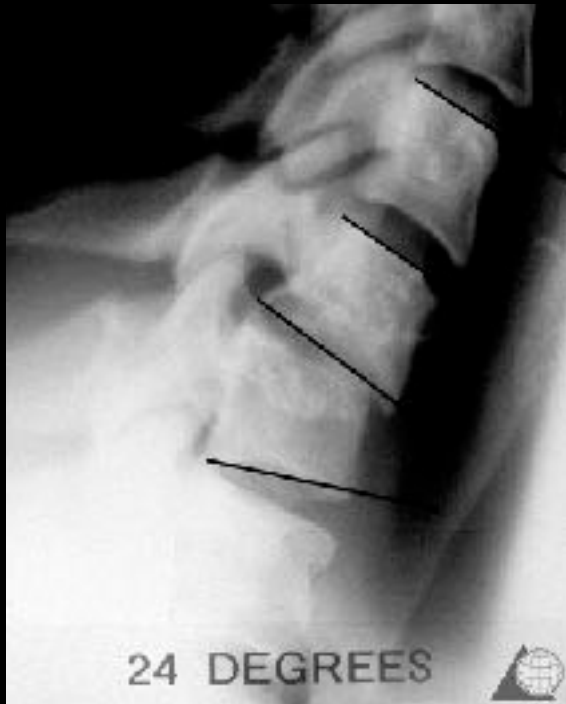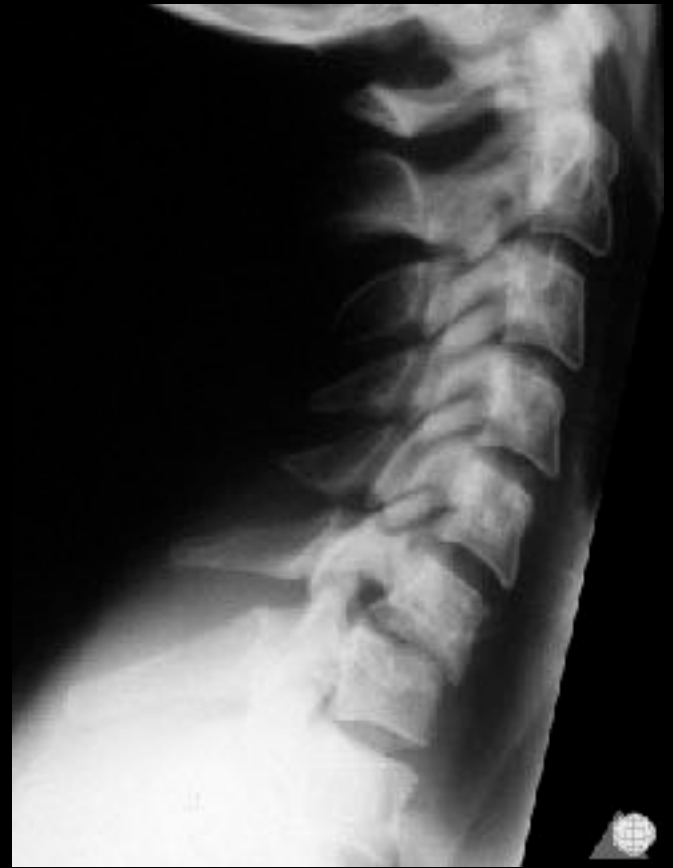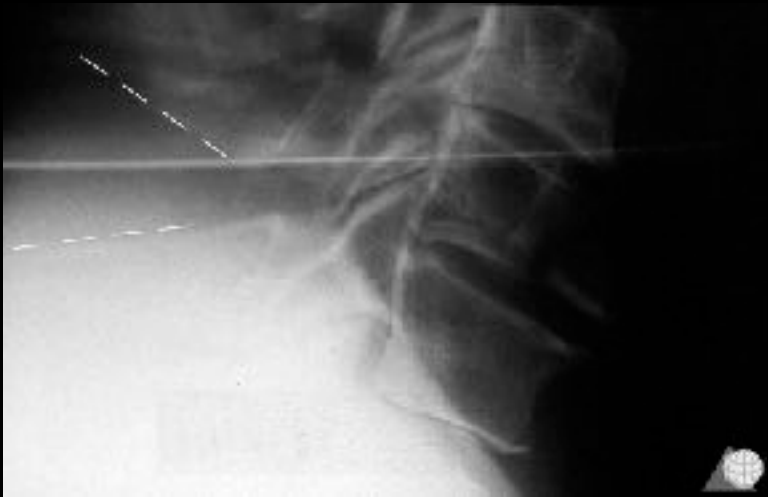**ZONE OF PARTIAL PRESERVATION**  
 Privately innervated segments  
 SENSORY   R L  
 MOTOR   R L

0 = absent  
 1 = impaired  
 2 = normal  
 NT = not testable

**ΚΑΤΑΓΜΑΤΑ ΚΑΤΩΤΕΡΗΣ  
ΑΥΧΕΝΙΚΗΣ ΜΟΙΡΑΣ  
(C3-C7)**

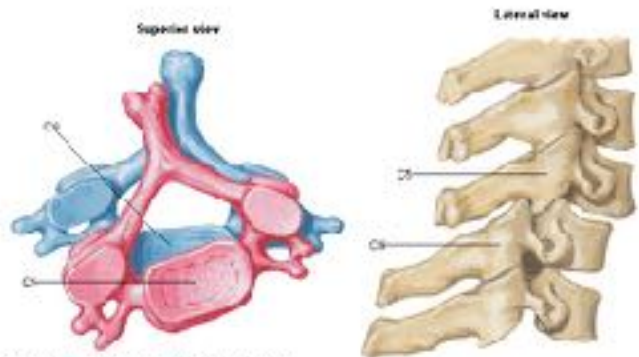




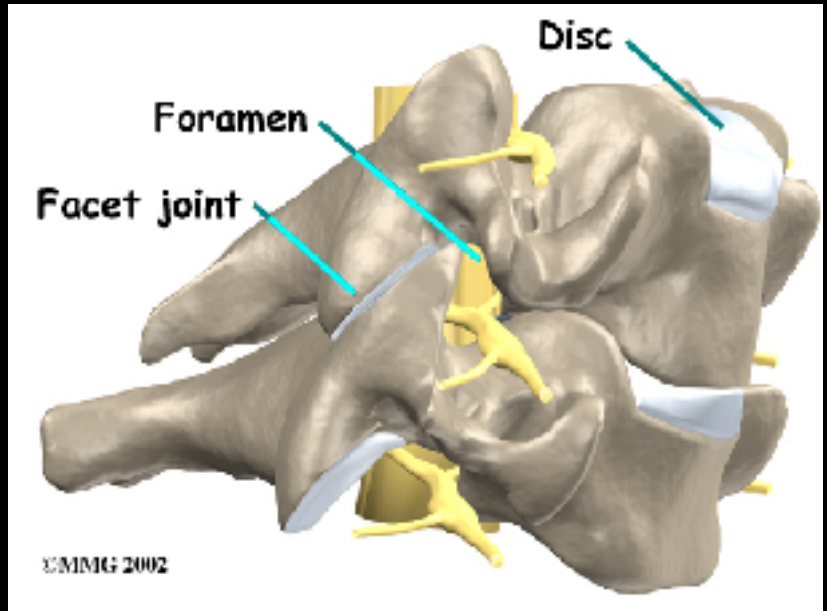


24 DEGREES

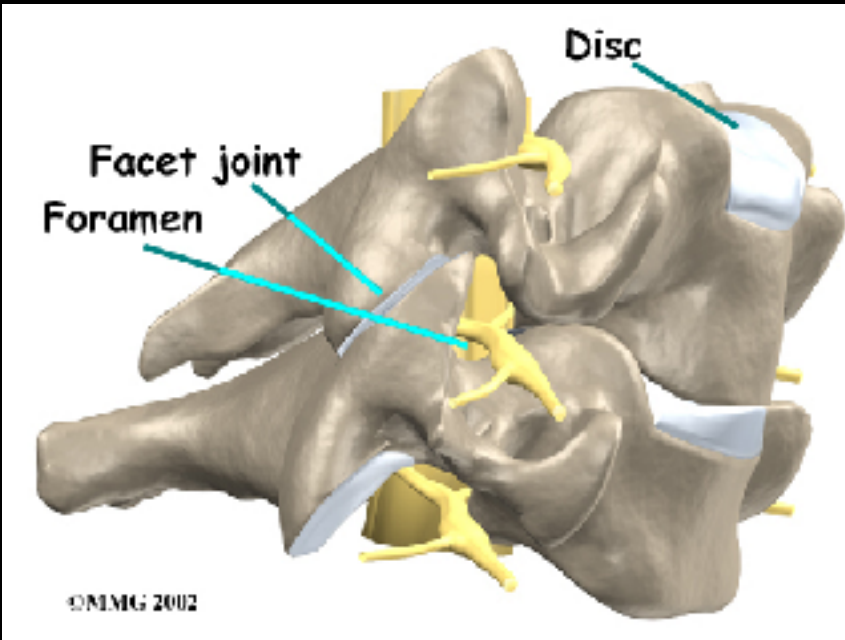
# Dislocation of Cervical Vertebrae



Anterior rotational dislocation of C1 on C2 with unilateral locked facets. Inferior articular process of C2 locked in front of superior articular process of C1.

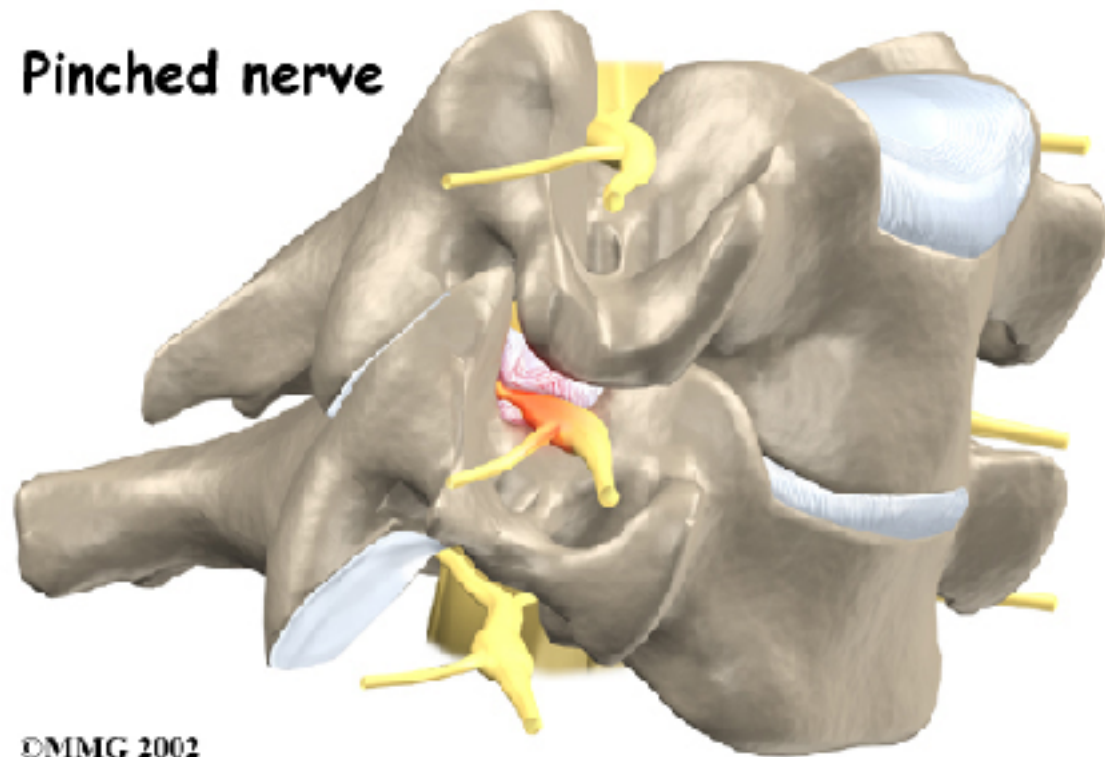


©MMG 2002



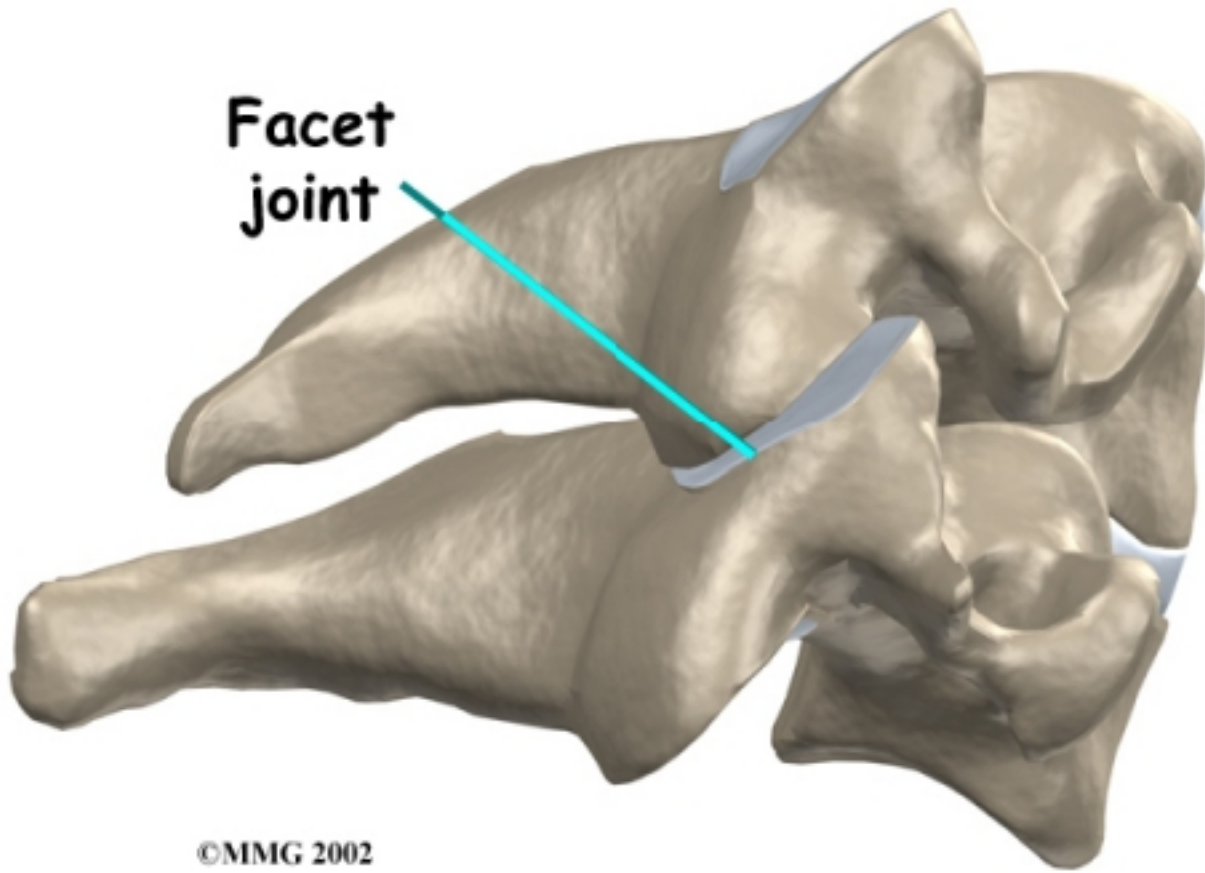
©MMG 2002

## Pinched nerve



©MIMG 2002

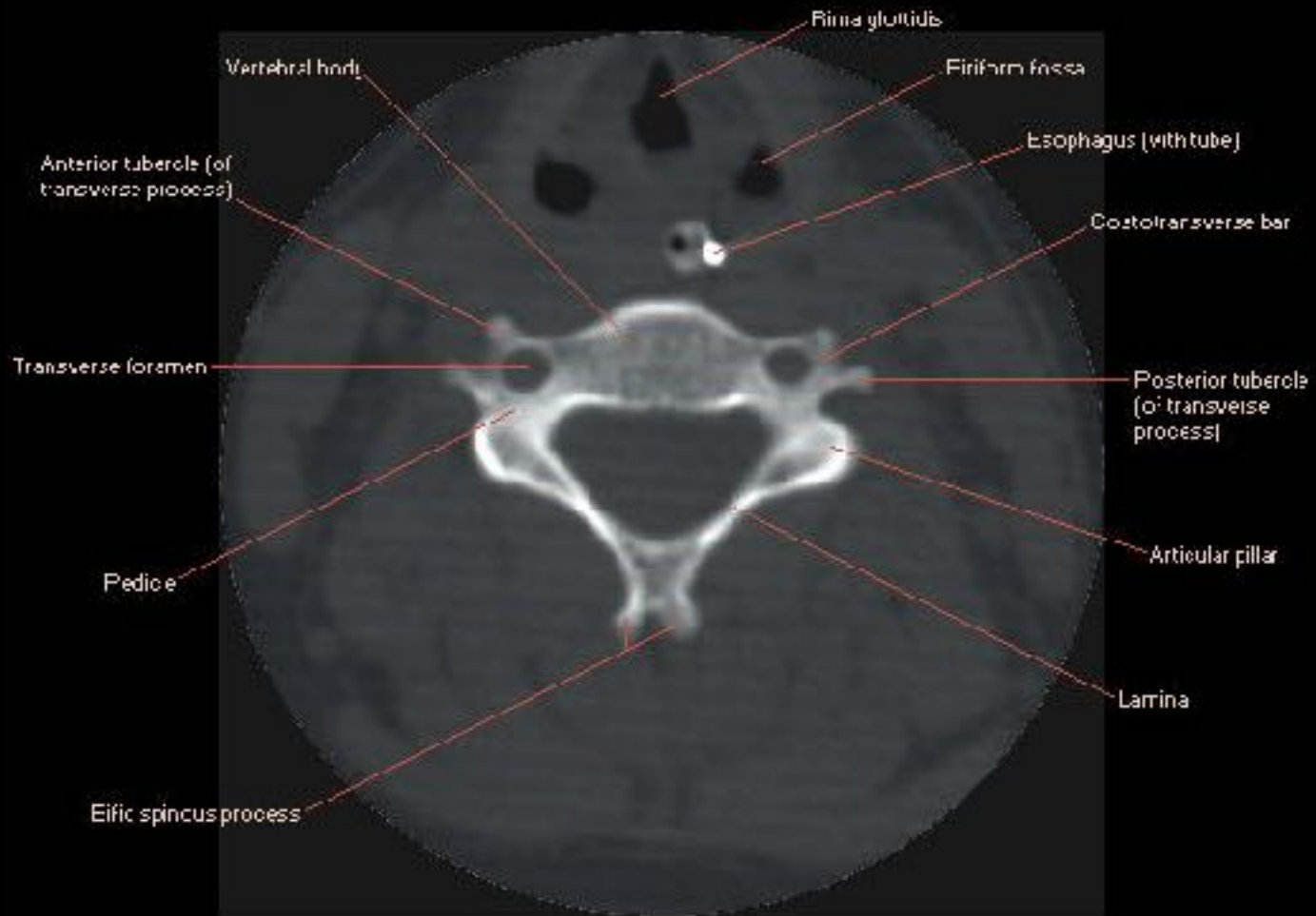
**Facet  
joint**

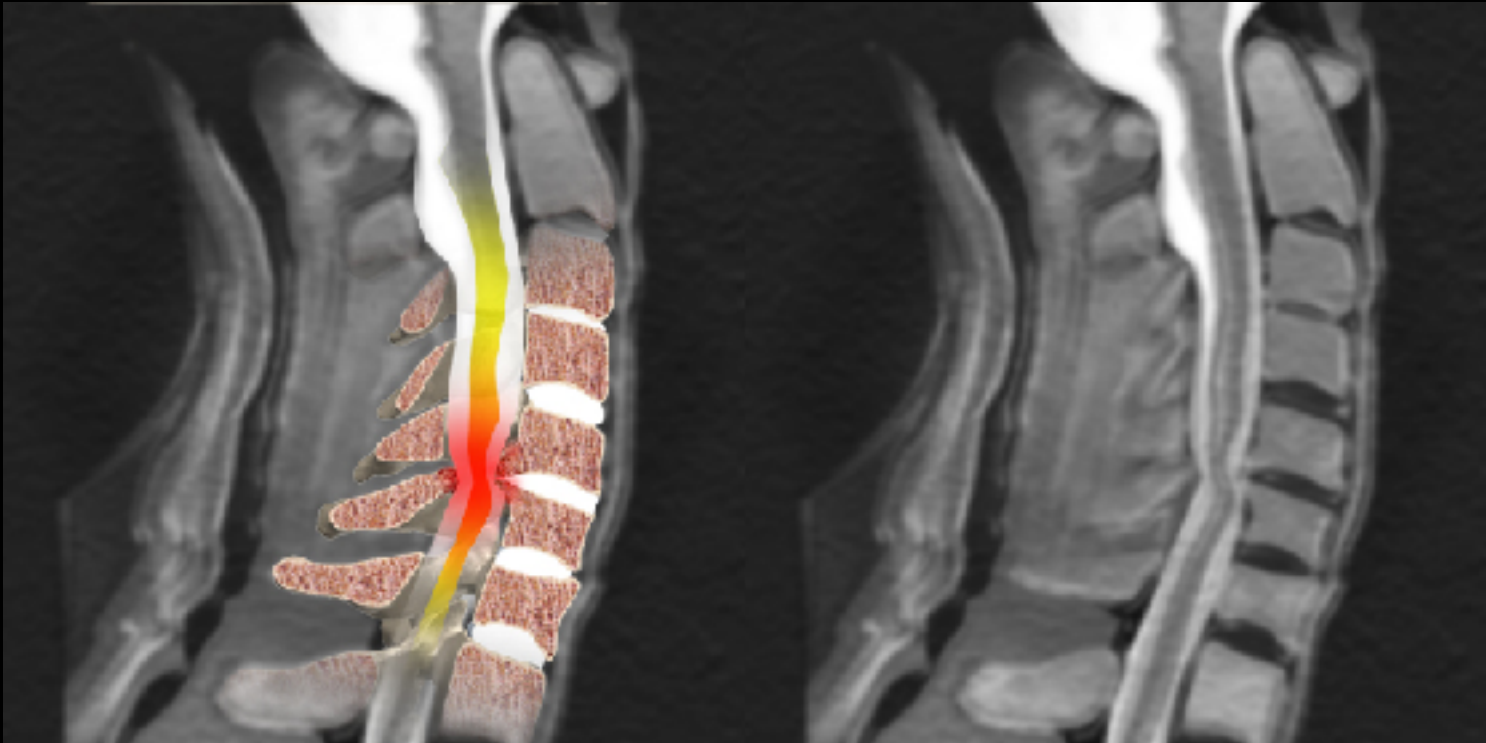


©MMG 2002

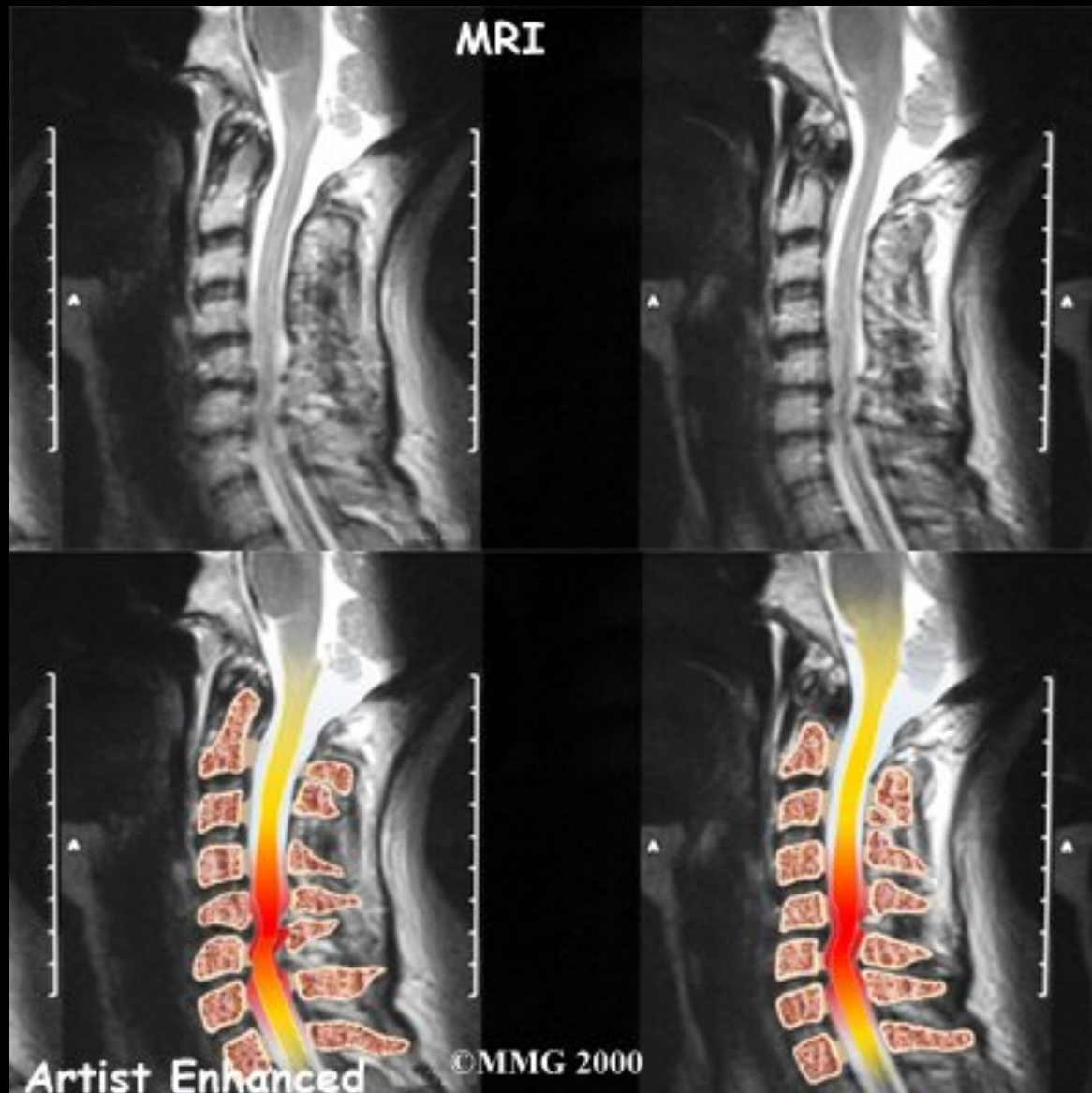
# Cervical Vertebra

## CT Scan - Axial Section, C5 Level





MRI



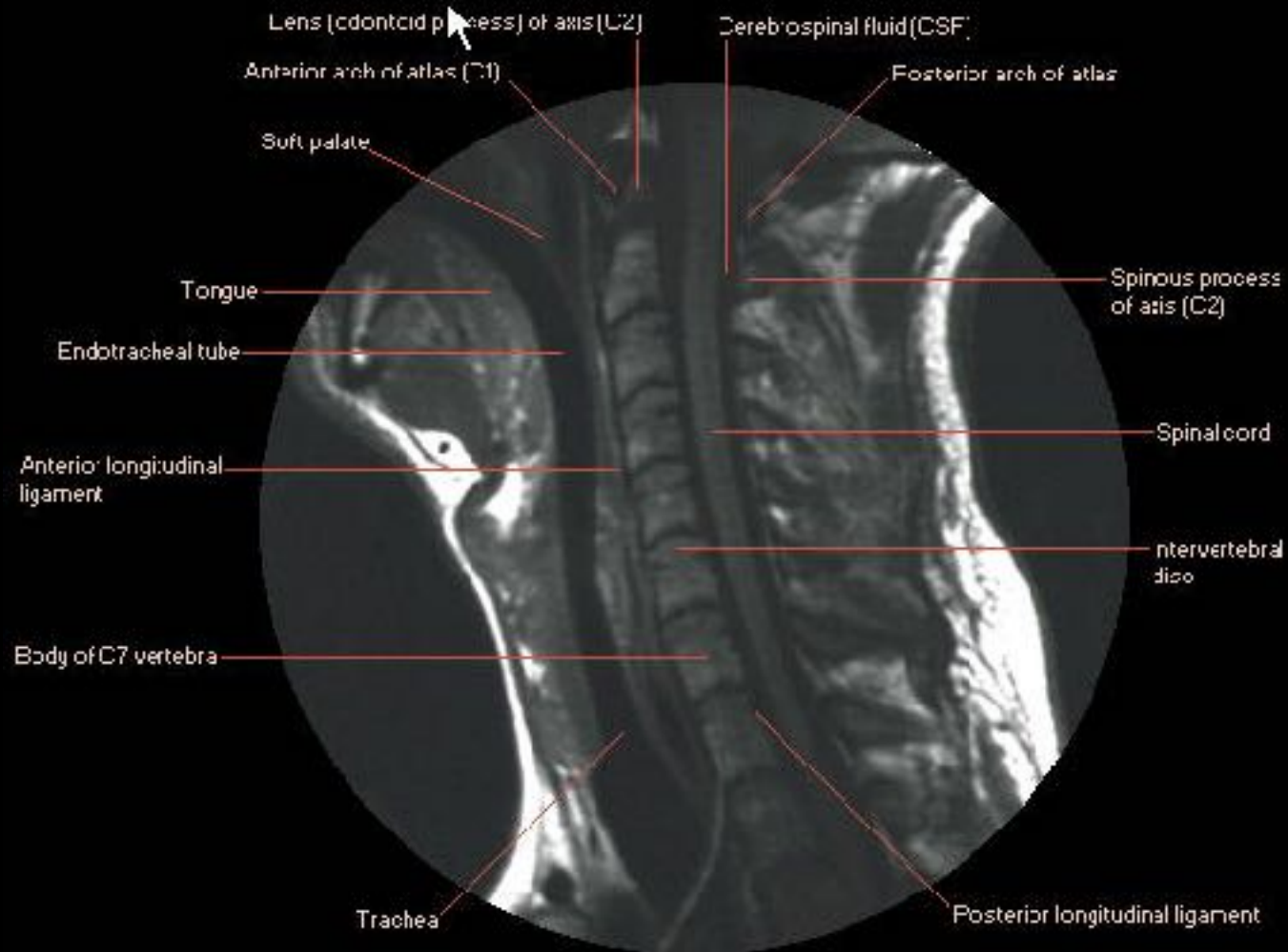
Artist Enhanced

©MMG 2000



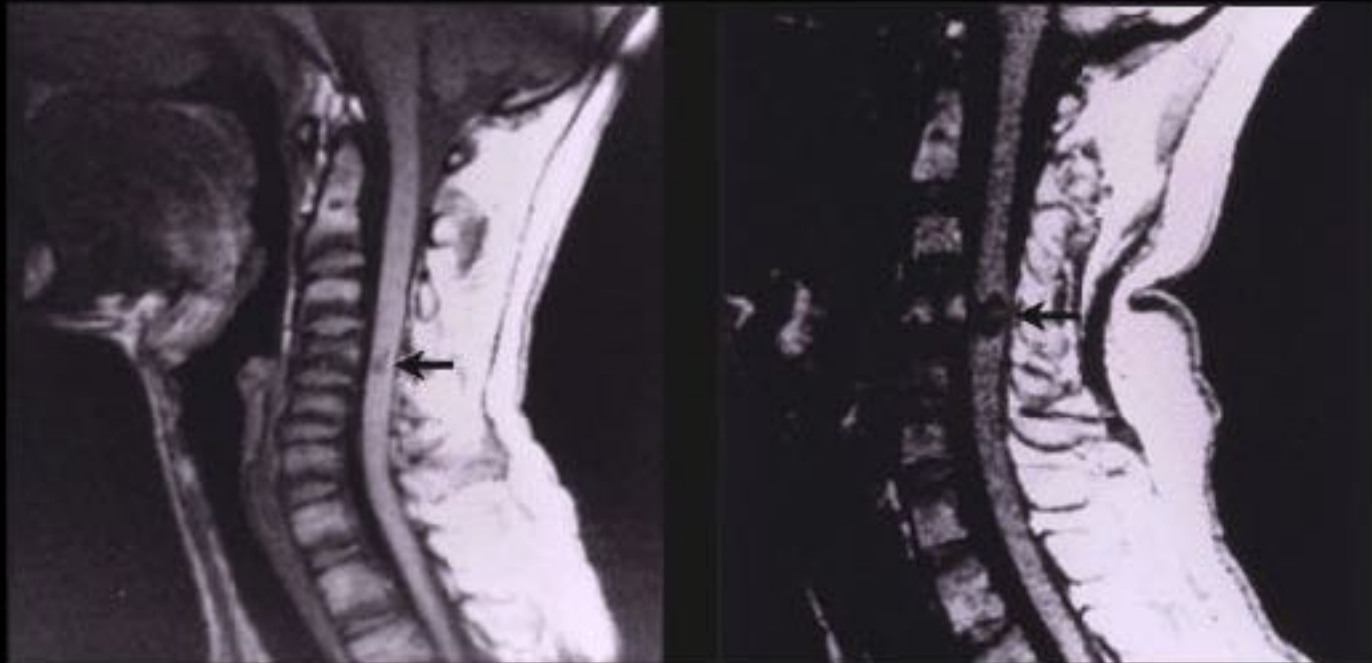
# Cervical Viscera and Spine

## MRI - Midsagittal Section of Neck



## Cervical Spinal Cord Injury

### MRI - Sagittal Sections

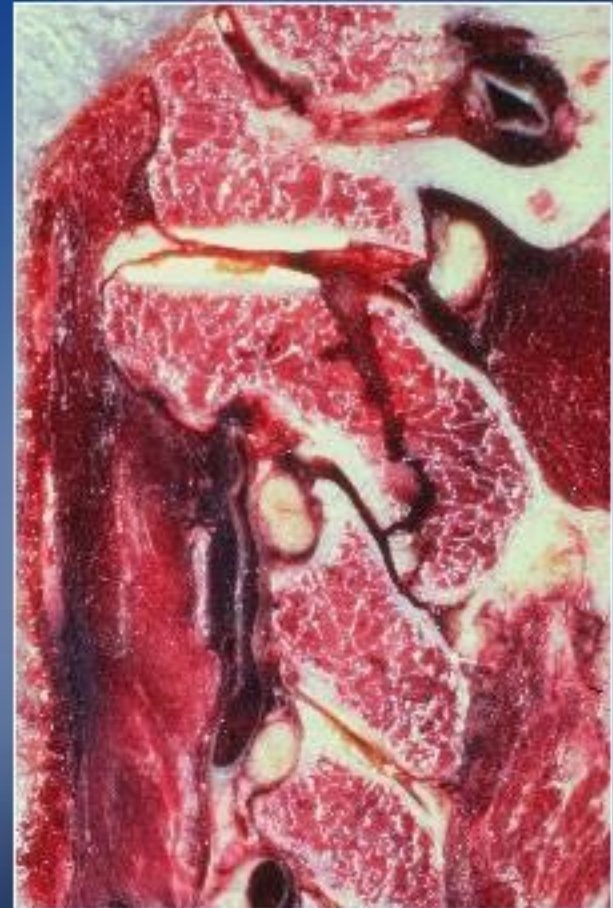
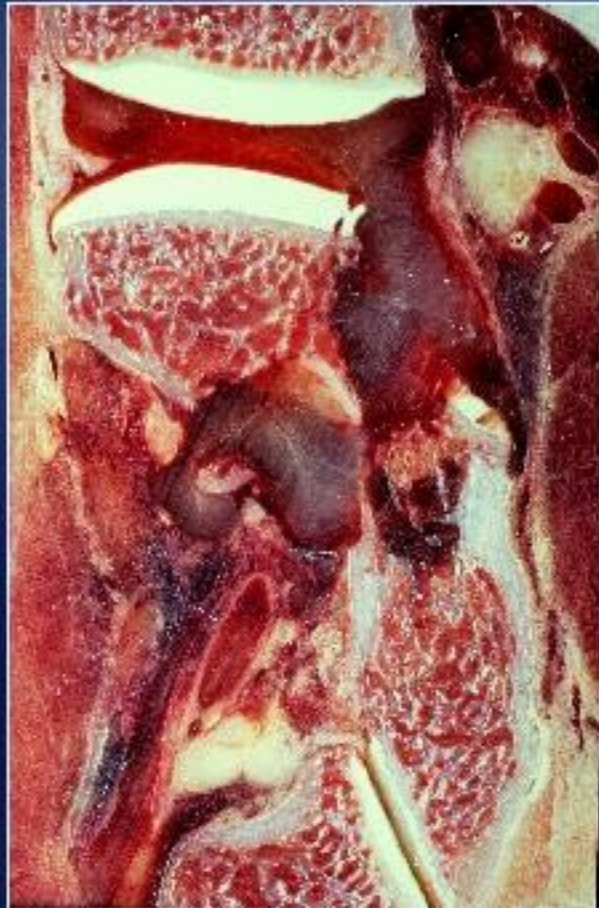
Mild spinal cord injury that resulted in some impairment of sensory and motor functions below level of spinal cord damage

Severe spinal cord injury. Total paralysis and sensory loss distal to spinal cord damage

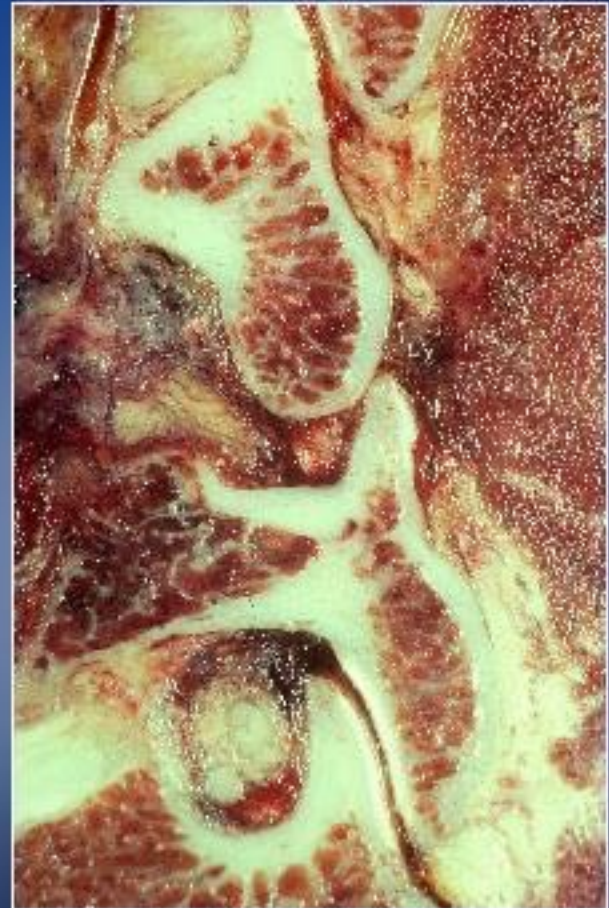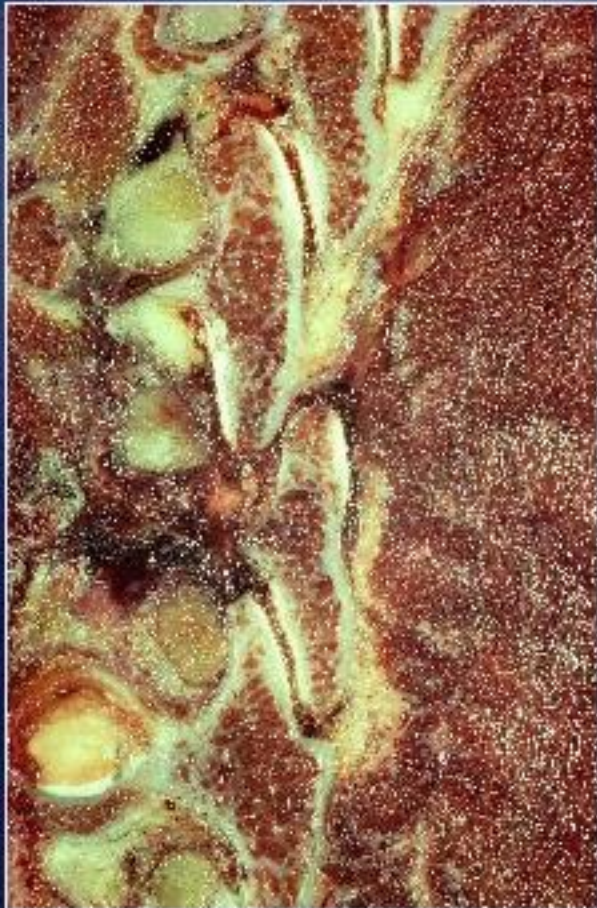# Cervical Spine Injury: "Hangman's Fracture"

Fracture of the Pars Interarticularis of C2

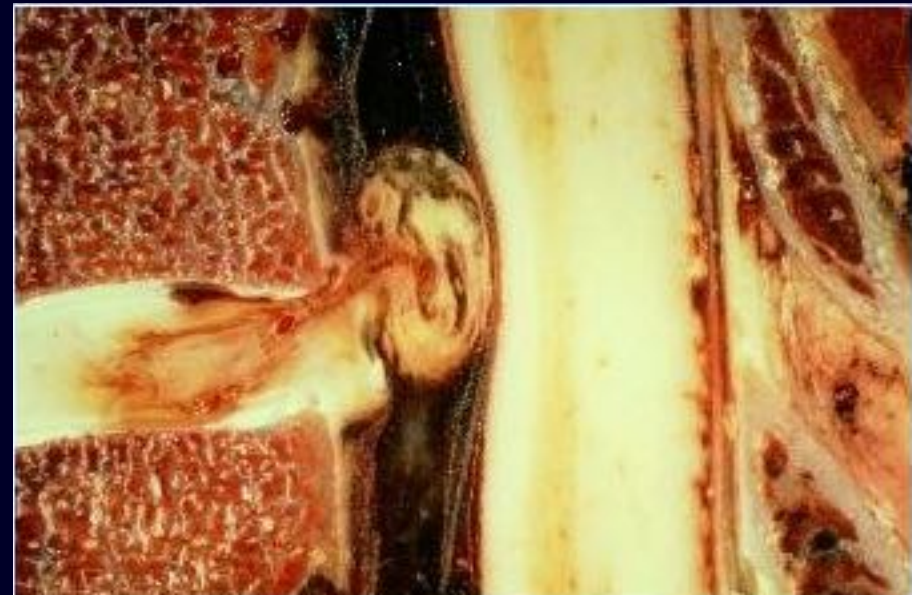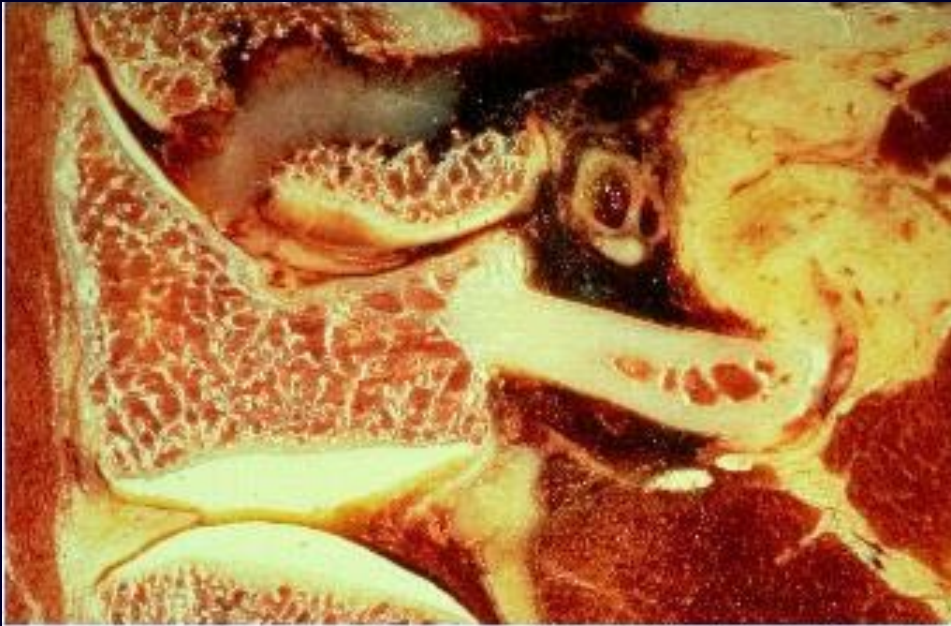


# Cervical Spine Injury: "Locked Facets"

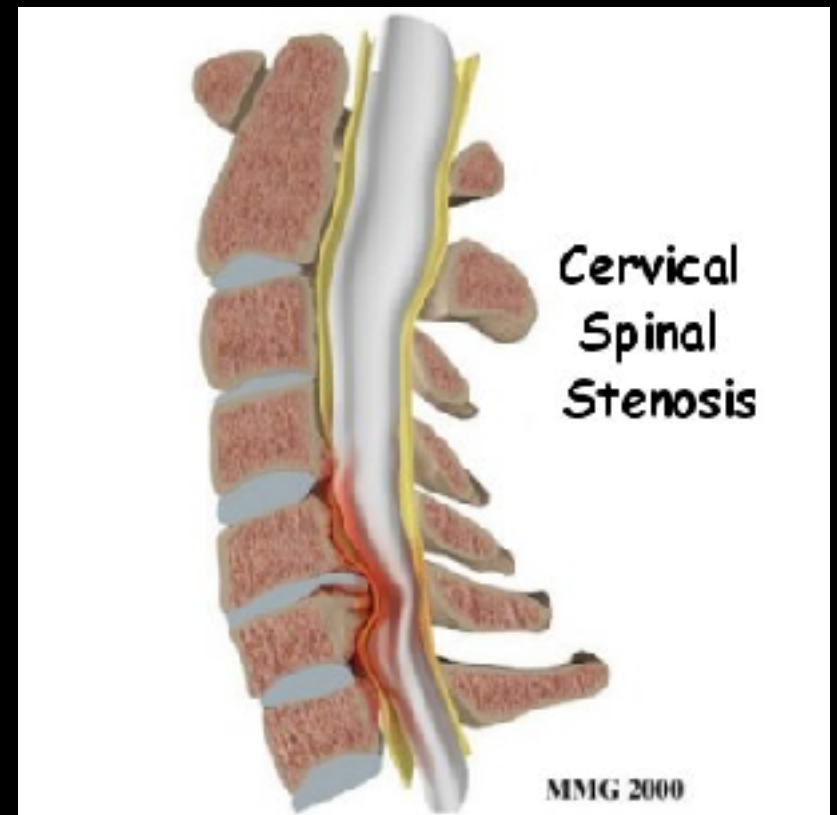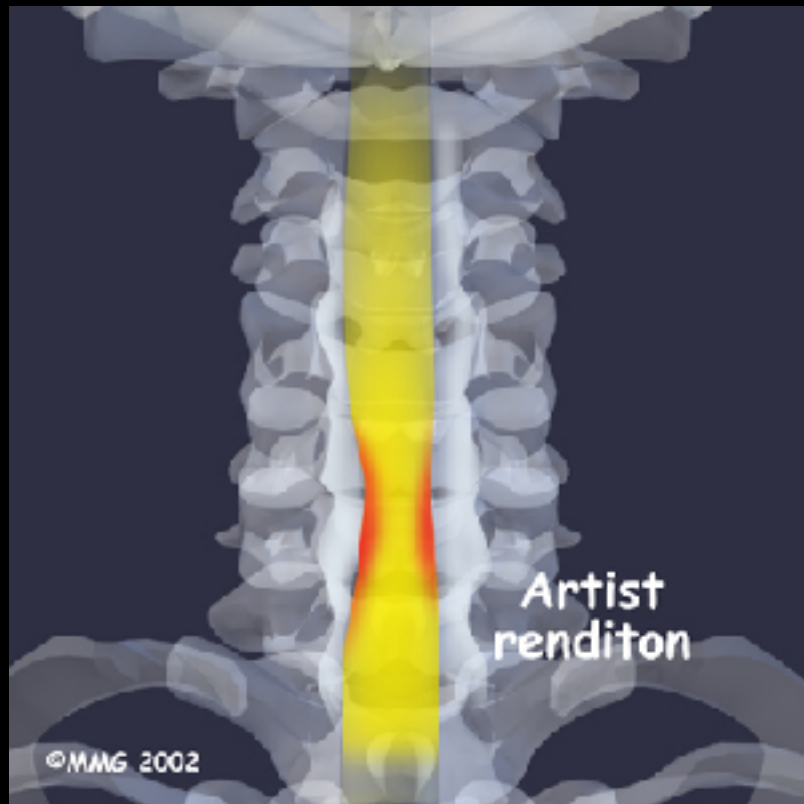
## Facet Joint Dislocation (Impingement)

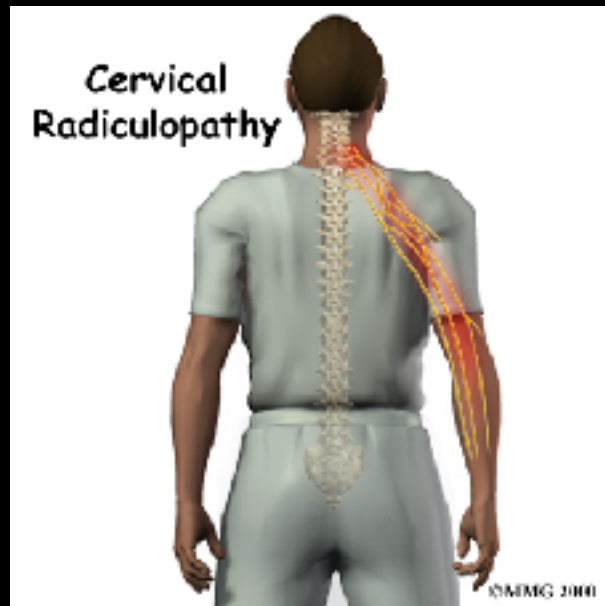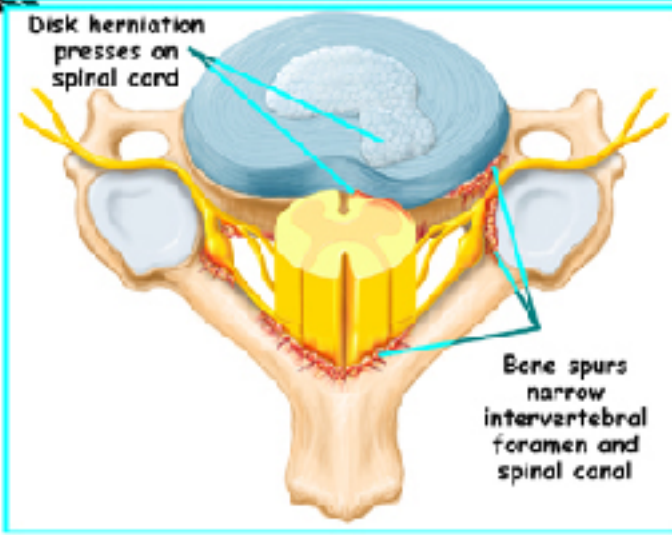
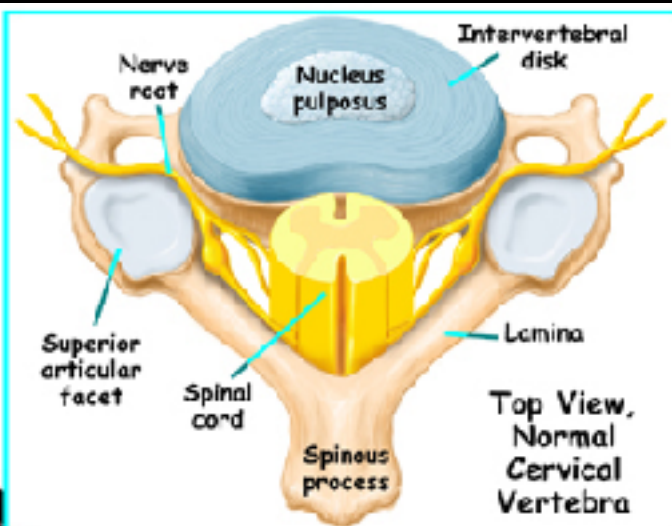


Traumatized Upper Cervical Spine:  
Avulsion of the Occipital Condyle  
Caused by Alar Ligament



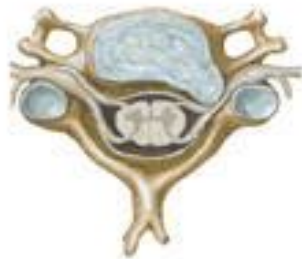Cervical Spine After Flexion Injury.  
Annulus Rupture and Nucleus Extrusion



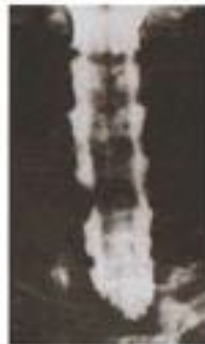

# Compression of Cervical Nerve Roots

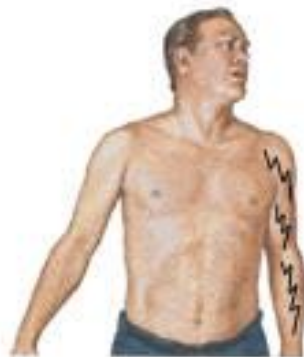## Cervical Radiculopathy



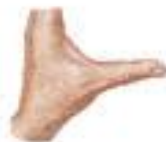Herniated disc compresses nerve root



Myelogram (AP view) shows prominent extradural defect at C6-7



Spurling's maneuver. Hyperextension of neck and rotation away from side of lesion cause radicular pain in arm and neck.



Thumb extension. Extensor pollicis longus. C6



Finger extension. Extensor digitorum. C7



Finger flexion. Flexor digitorum superficialis and profundus. C8

Level	Motor signs (weakness)	Reflex signs	Sensory loss
C5	Deltoid	0	
C6	Biceps brachii	Biceps brachii Weak or absent reflex	
C7	Triceps brachii	Triceps brachii Weak or absent reflex	
C8	Interossei	Horner's Syndrome	



# Dermatomes

## Structures within dermatomes

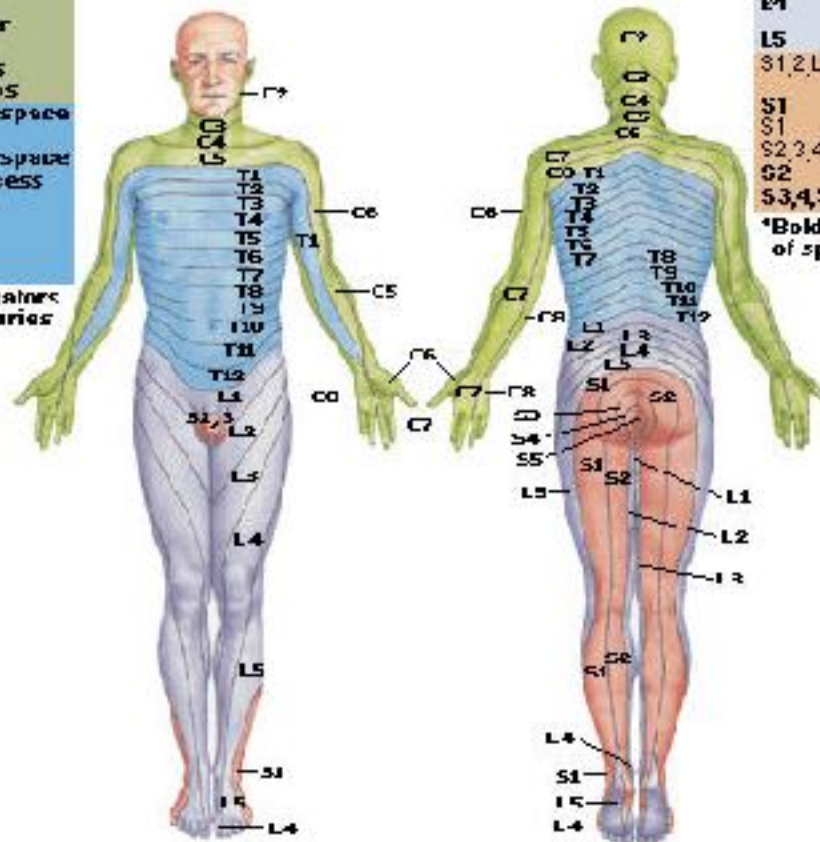
- C5,6,7 Lateral parts of upper limbs
- C5 Clavicles
- C5 Anterolateral shoulder
- C6,7,8 Hand
- C6 Thumb
- C7 Middle finger
- C8 Little finger
- C8,11 Medial sides of upper limbs
- T3 3rd,4th interspace
- T4 Nipple line, 4th,5th interspace
- T6 Xiphoid process
- T10 Umbilicus
- T12 Inguinal or groin regions
- T12 Pubis

\*Bold are key indicators of spinal cord injuries

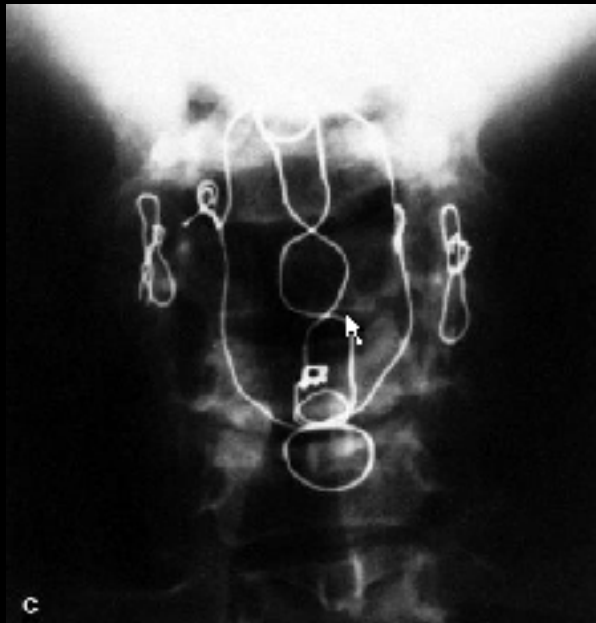
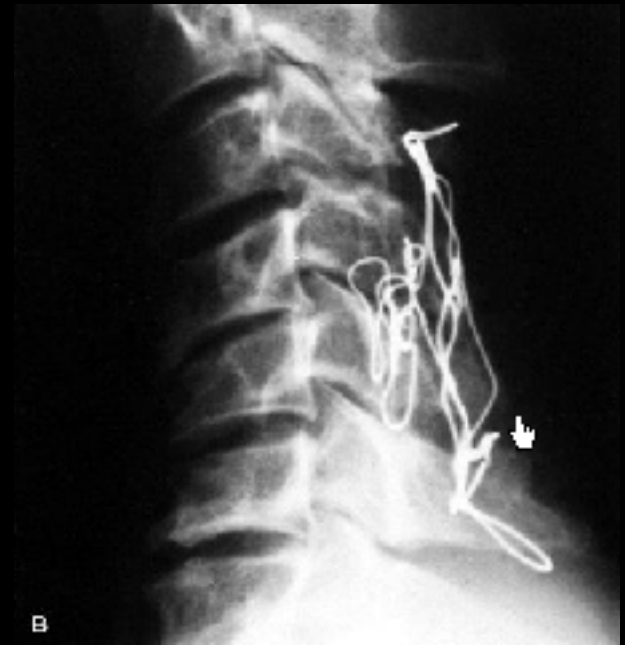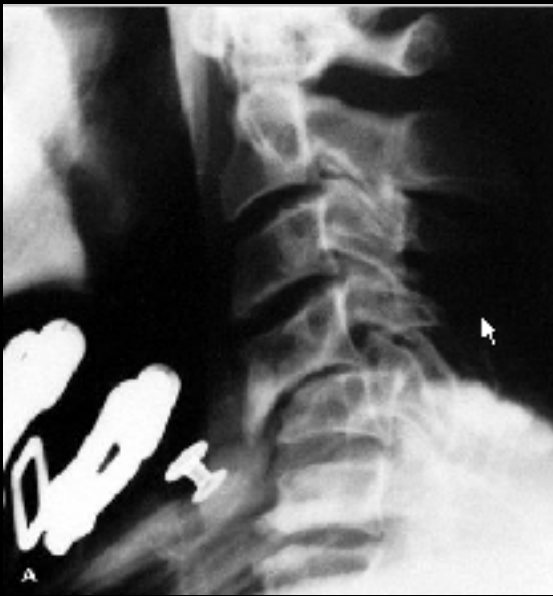## Structures within dermatomes

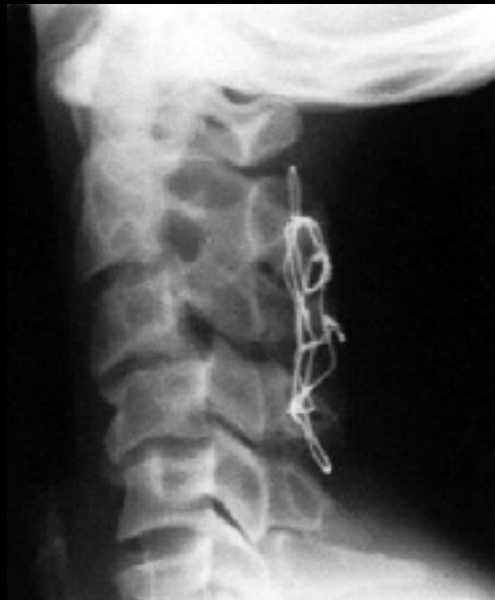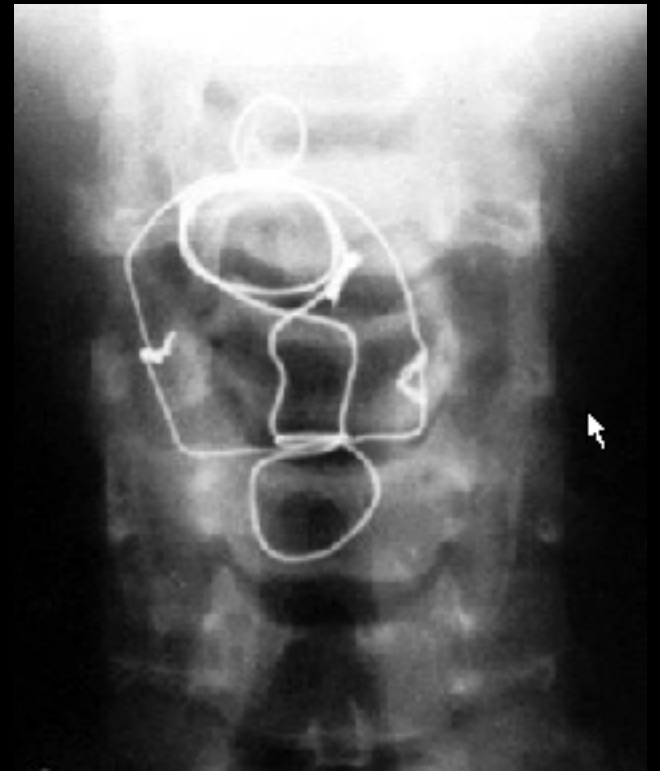
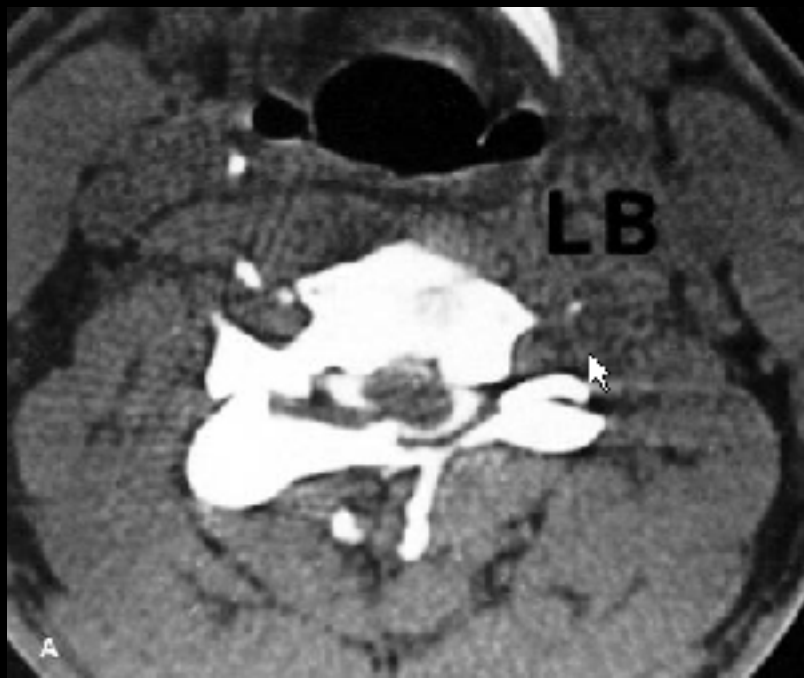- L1,2,3,4 Anterior and inner surfaces of lower limbs
- L2 Medial thigh
- L3 Medial knee
- L4 Medial ankle
- S1,2,3,4 Foot
- L4 Medial side of Great toe
- L5 Dorsum of foot
- S1,2,L5 Posterior and lateral surfaces of lower limbs
- S1 Lateral margin of foot
- S1 Little toe
- S2,3,4 Perianium
- S2 Posteromedial thigh
- S3,4,5 Perianal area

\*Bold are key indicators of spinal cord injuries

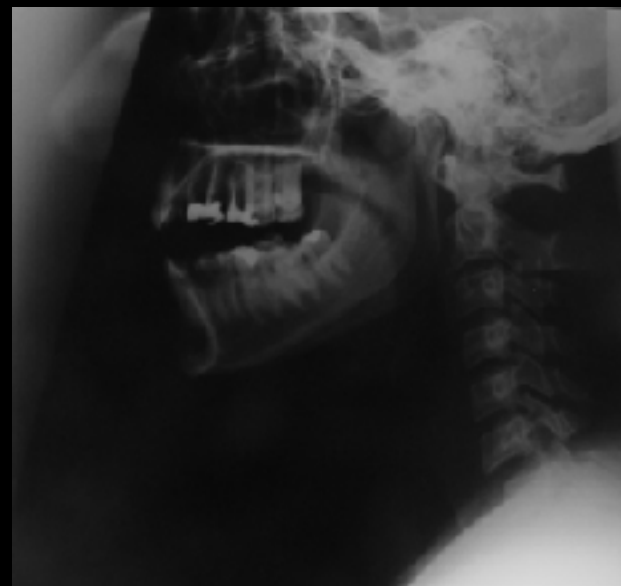
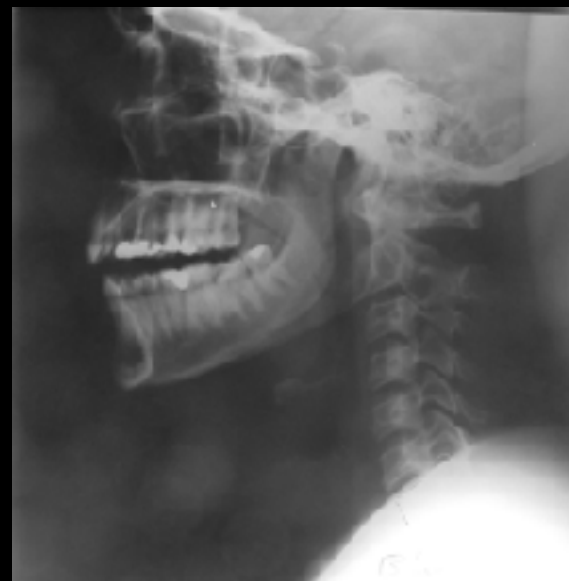
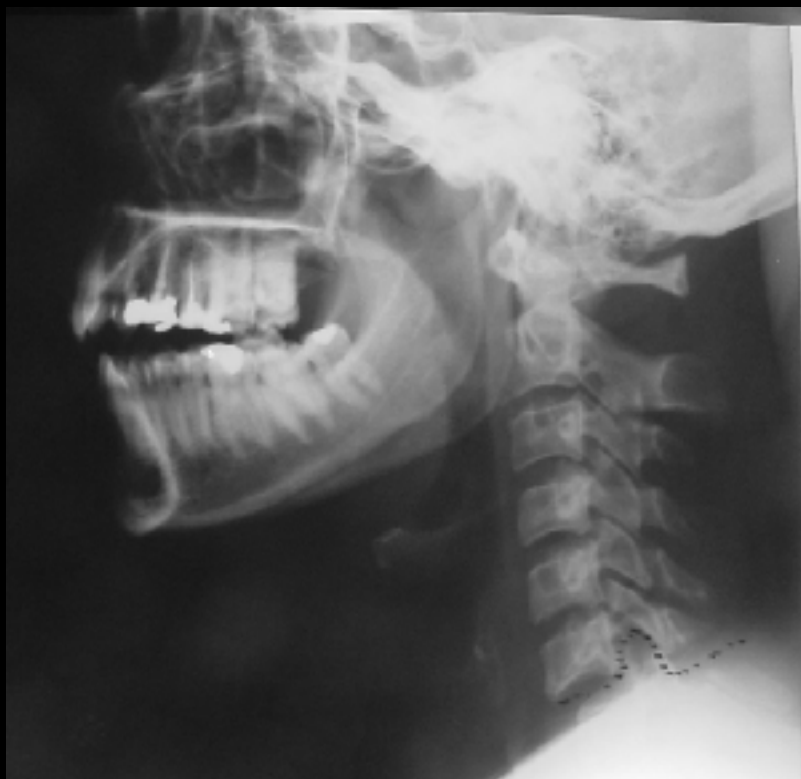Schematic demarcation of dermatomes shown as distinct segments. There is actually considerable overlap between any two adjacent dermatomes

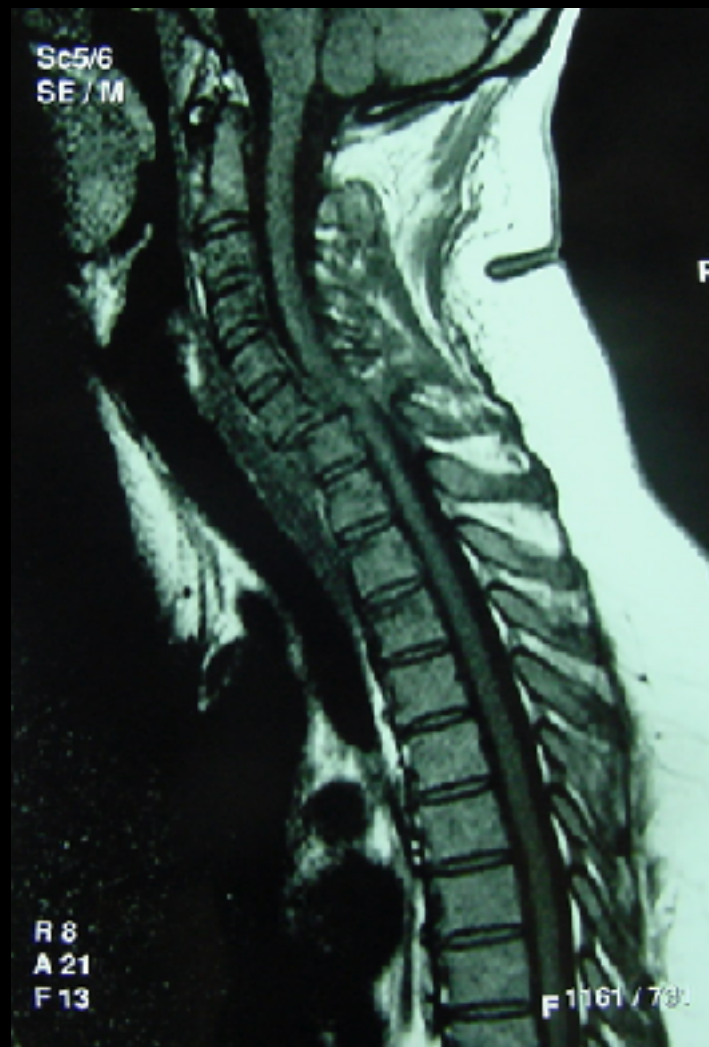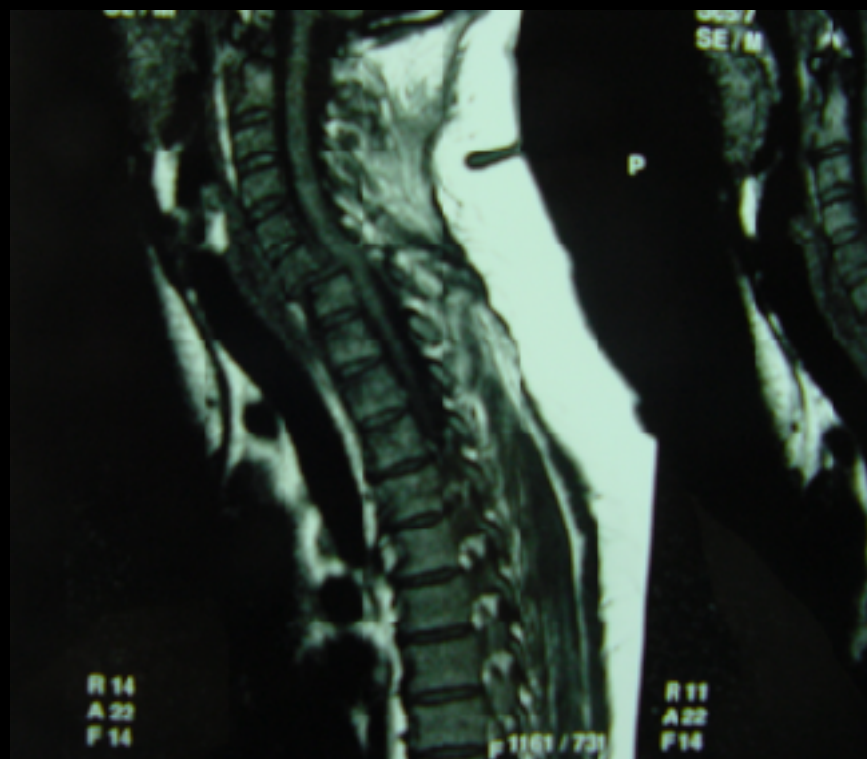




Ορθοπαιδική Κλινική  
Πανεπιστημίου Θεσσαλίας

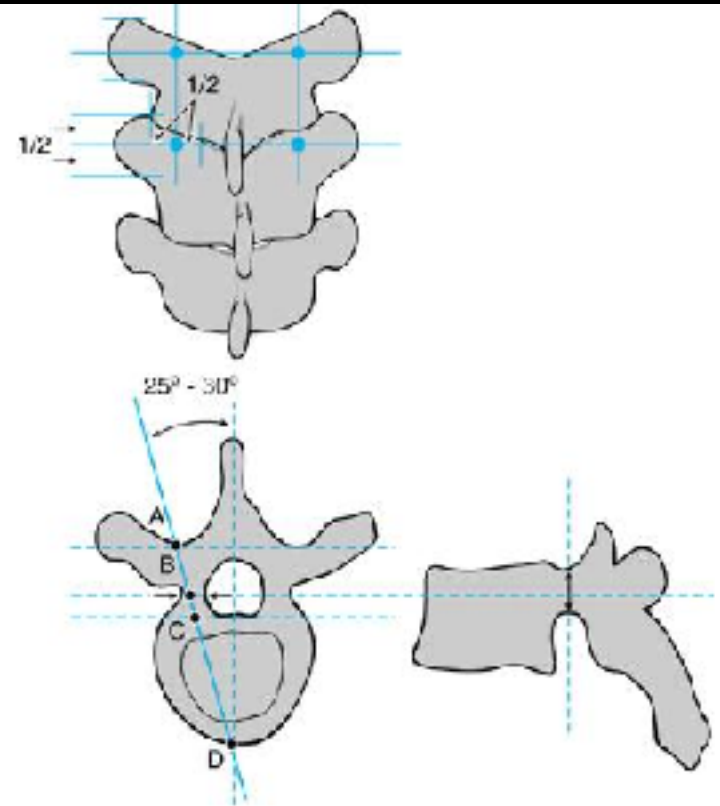
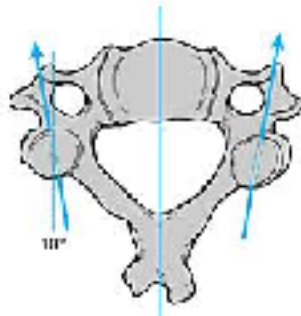
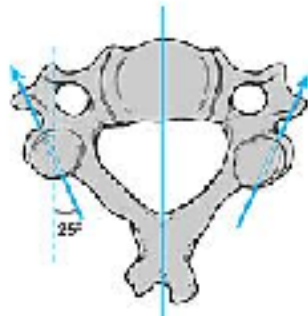
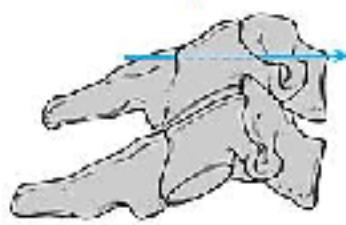
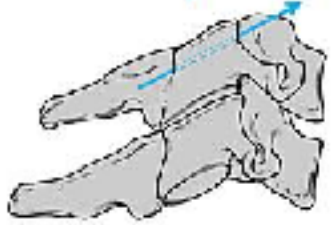
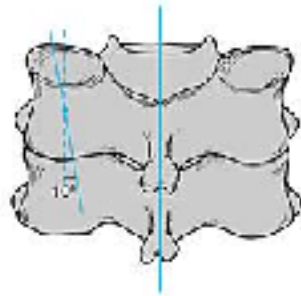
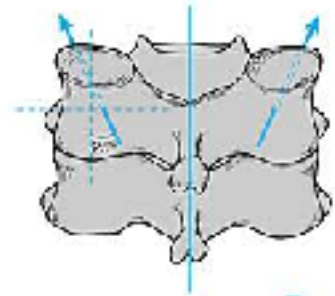


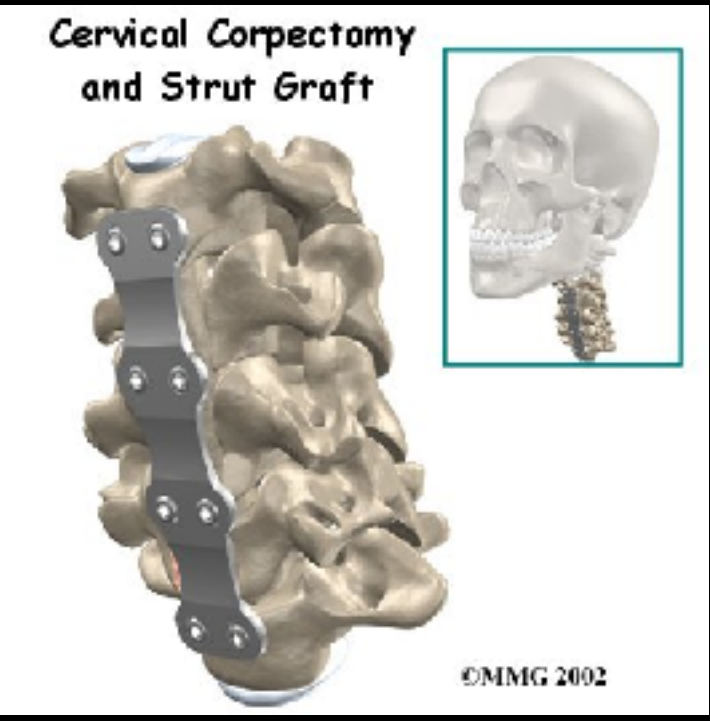
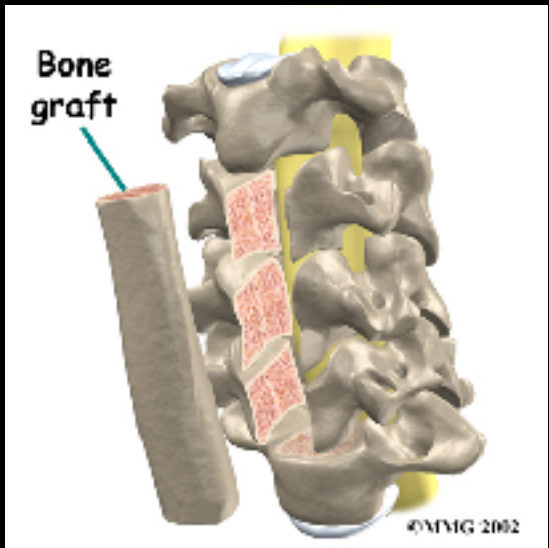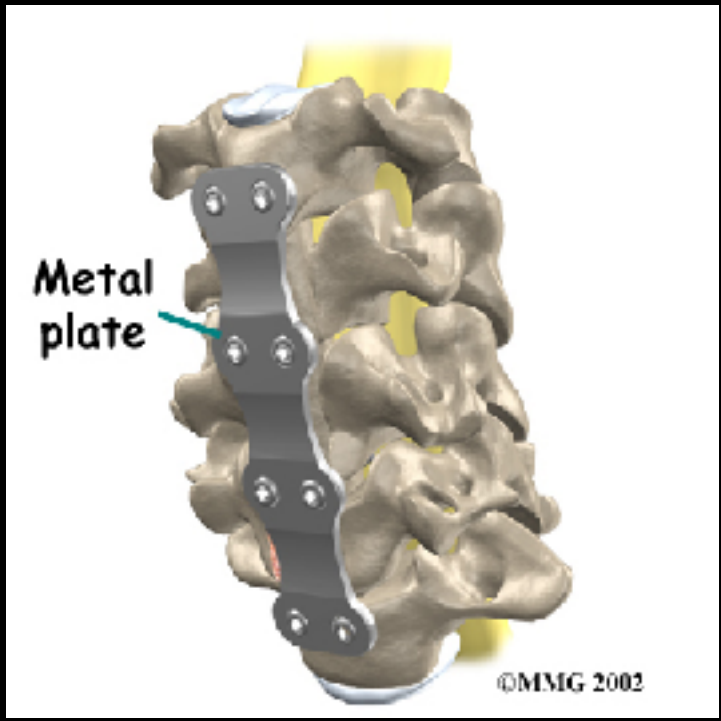
# Ορθοπαιδική Κλινική Πανεπιστημίου Θεσσαλίας



Magenl 25°-30°

Roy-Ca 12-13°



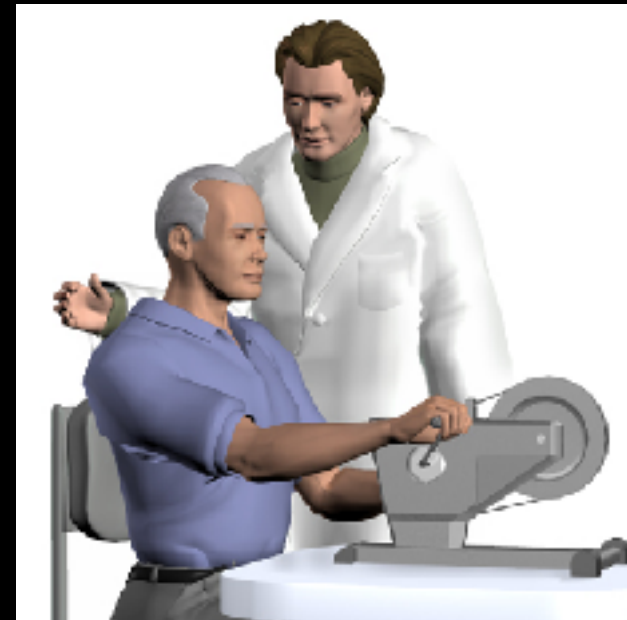

**Soft  
cervical  
collar**

**©MMG 2002**

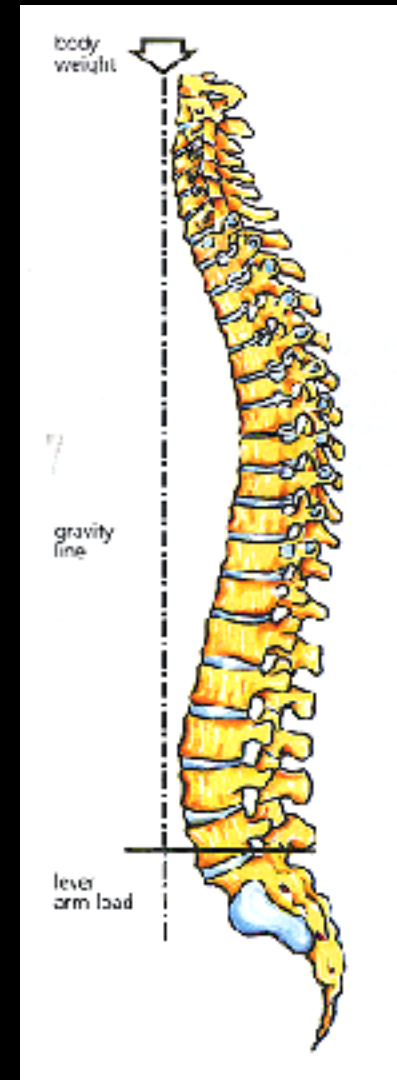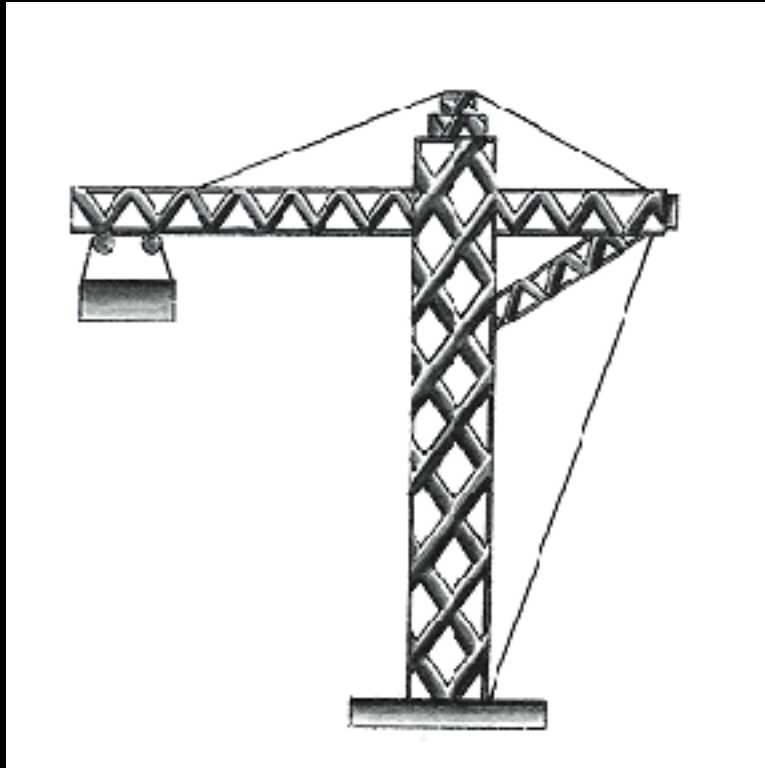


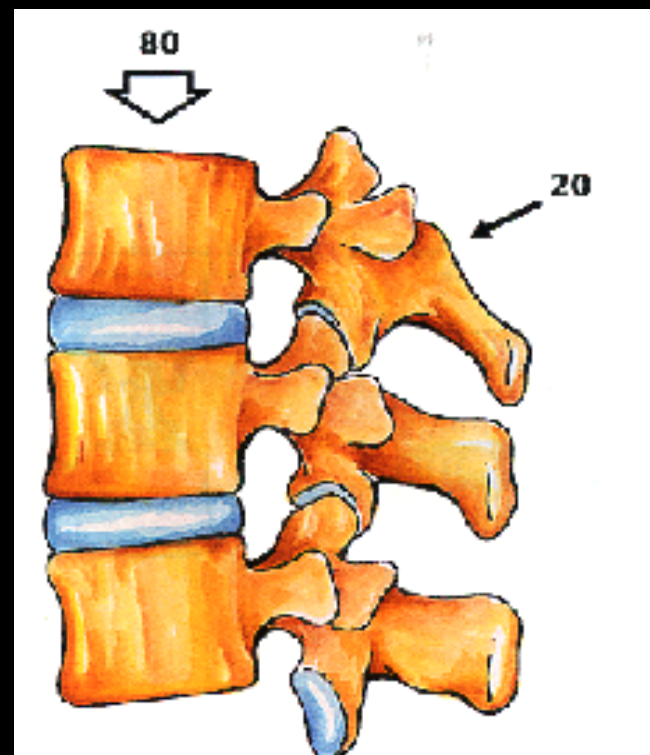
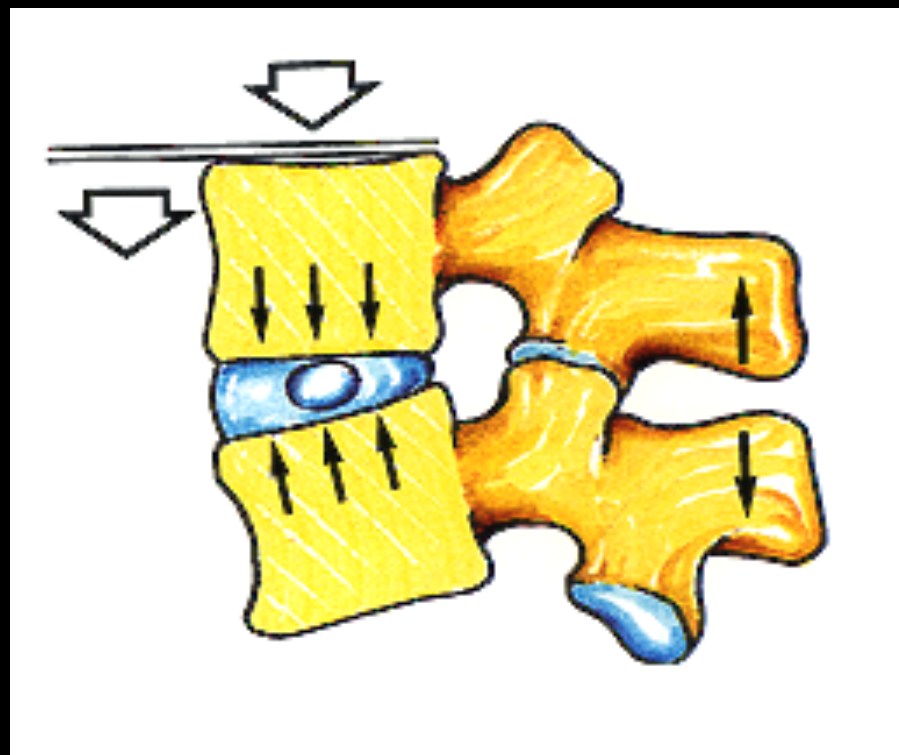


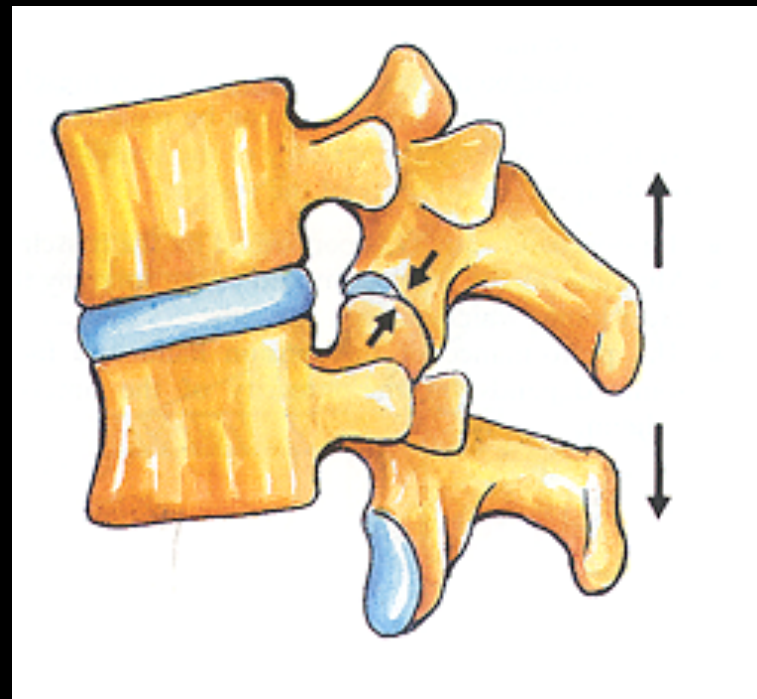
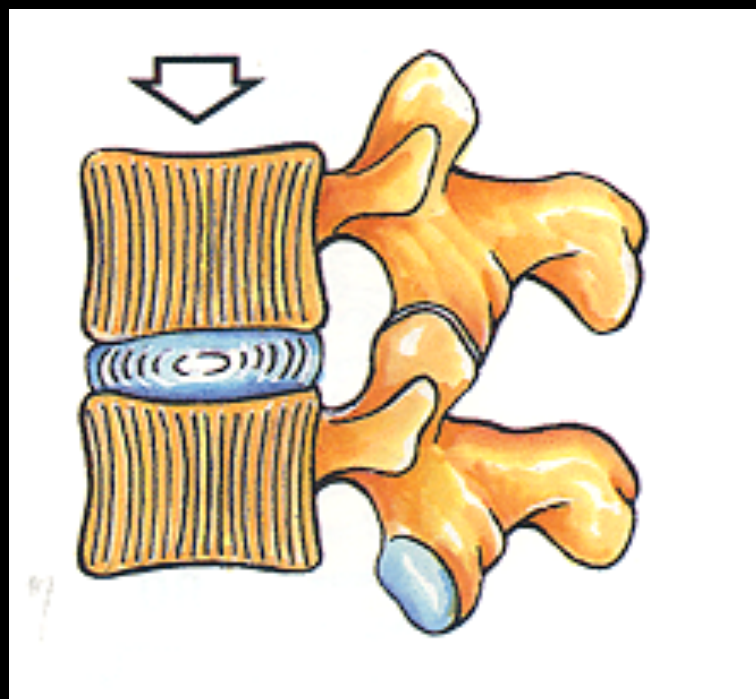


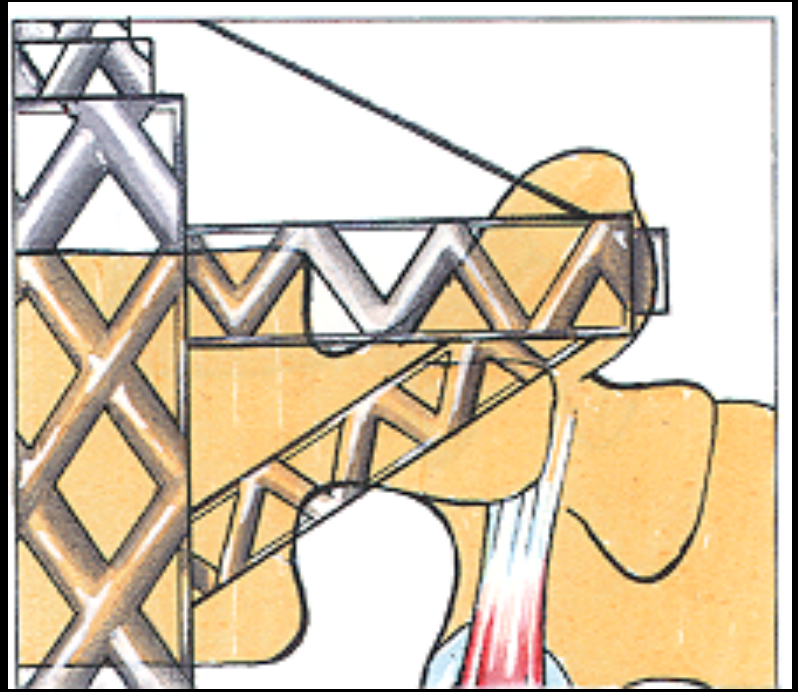
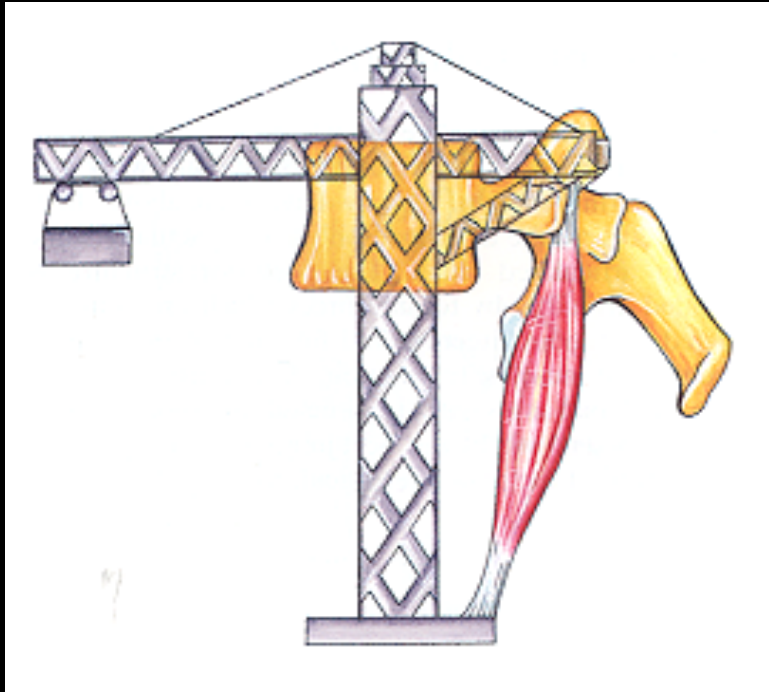
ΚΑΤΑΓΜΑΤΑ ΘΩΡΑΚΟΣΦΥΙΚΗΣ  
& ΟΣΦΥΙΚΗΣ ΜΟΙΡΑΣ  
ΣΠΟΝΔΥΛΙΚΗΣ ΣΤΗΛΗΣ

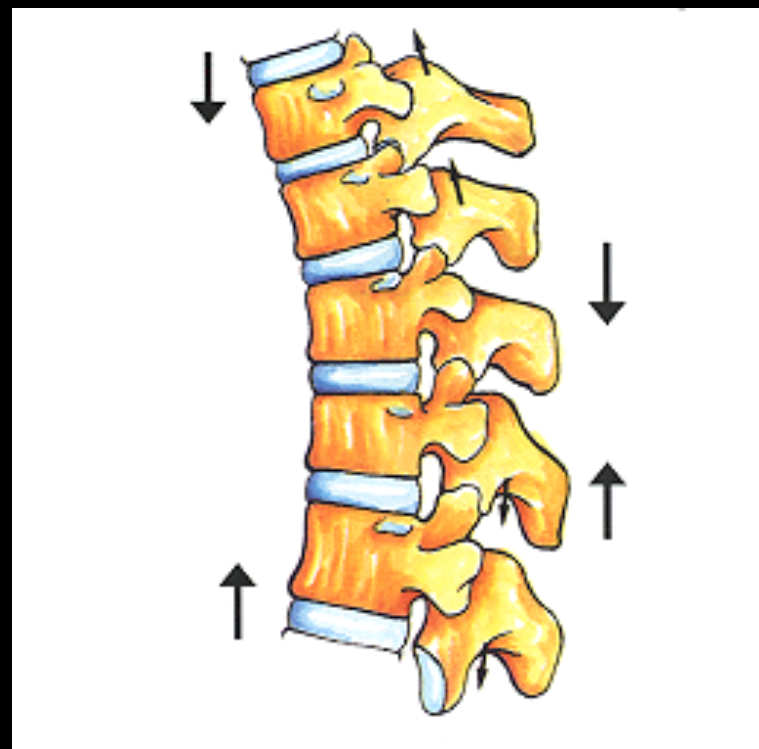
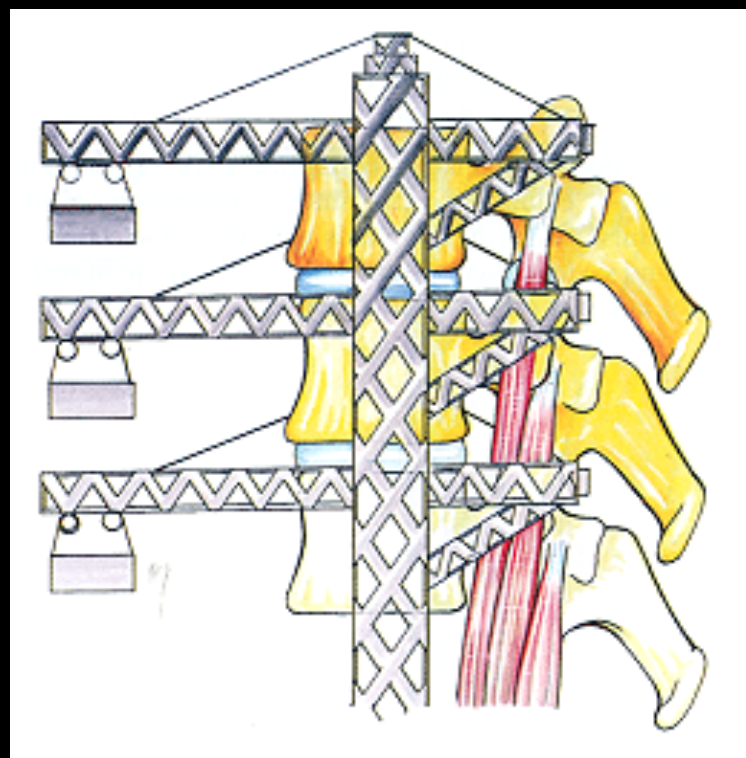
# Γενικές Αρχές Μηχανικής

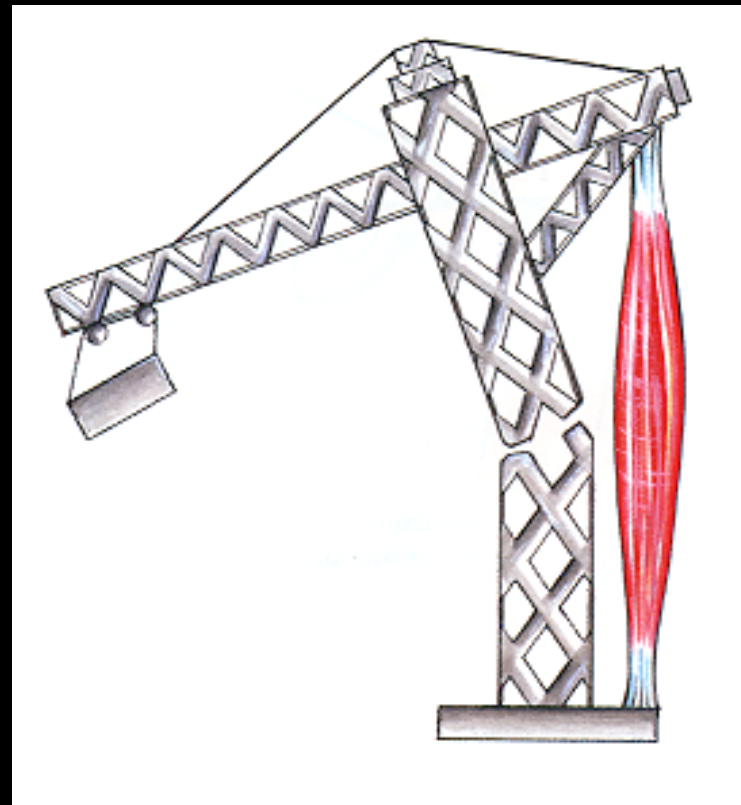
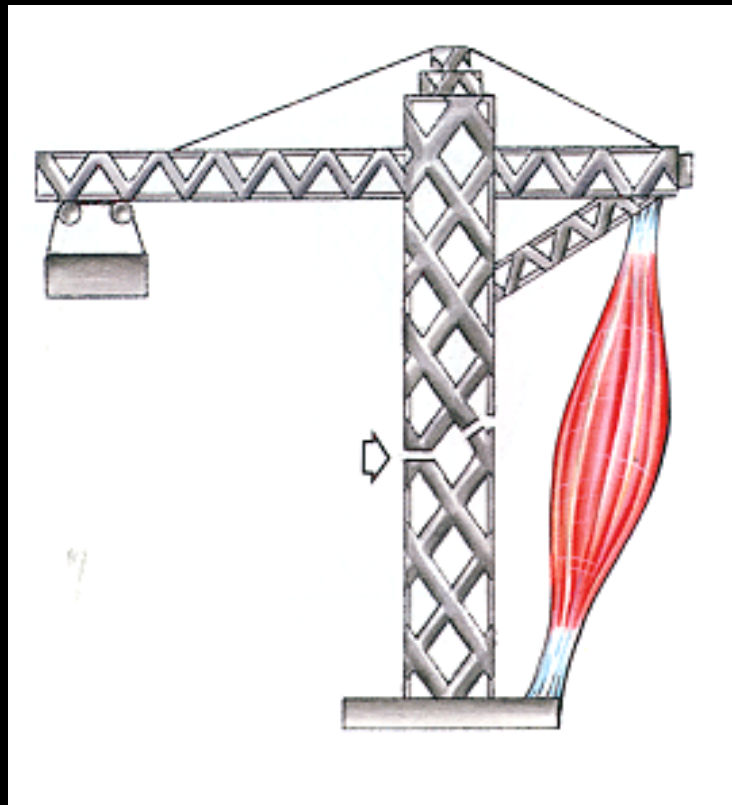




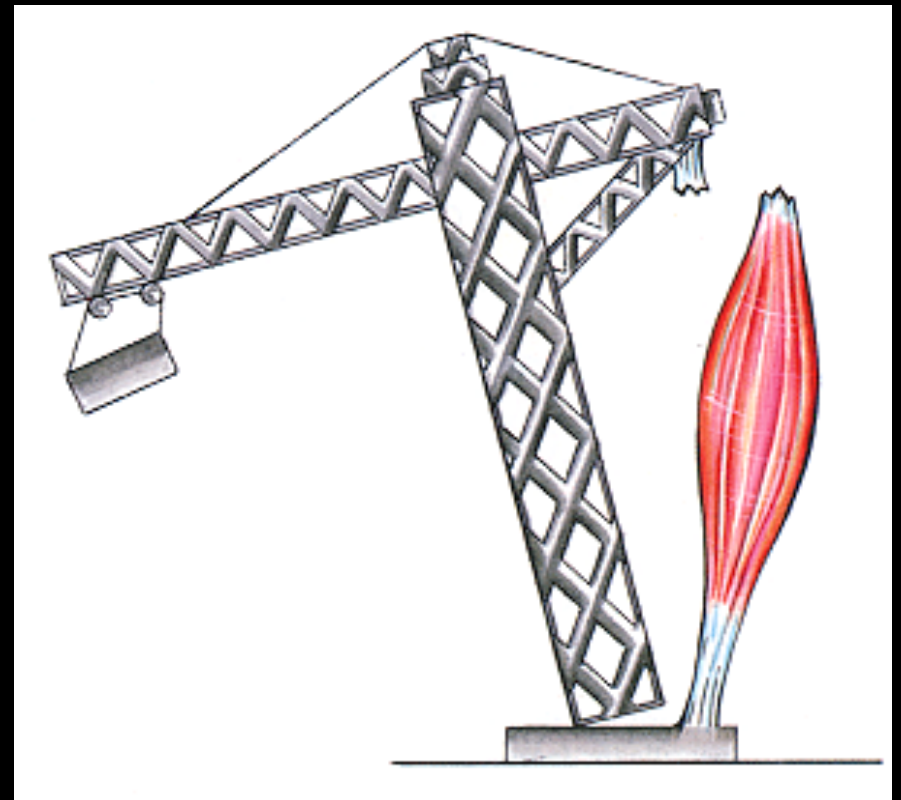
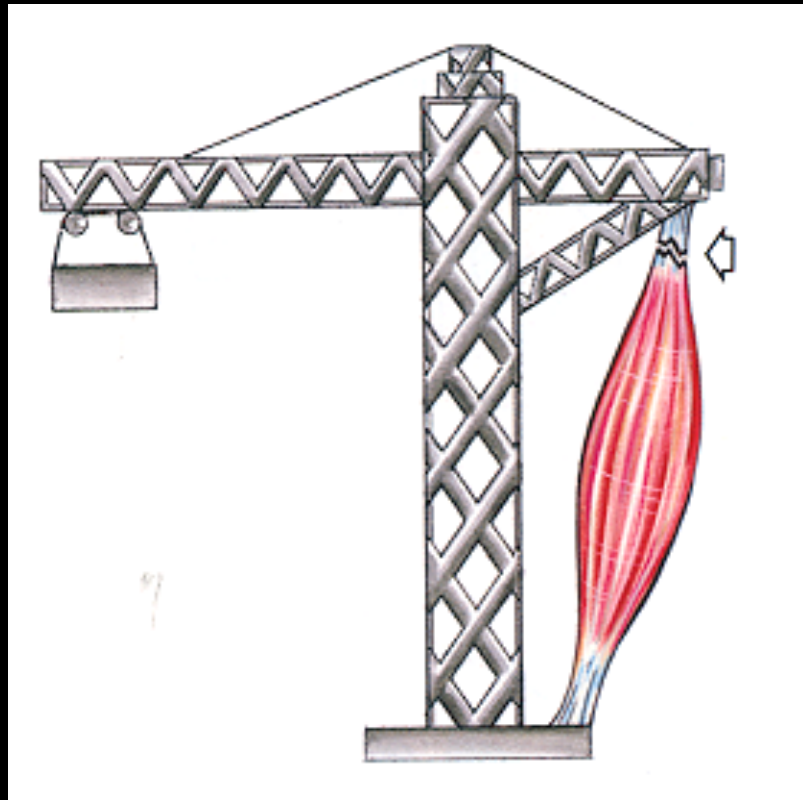


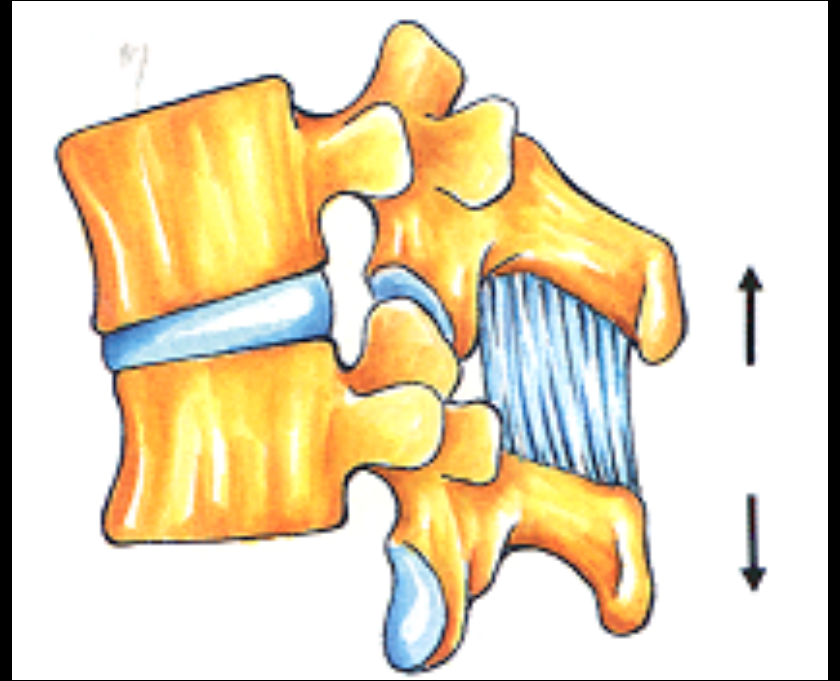
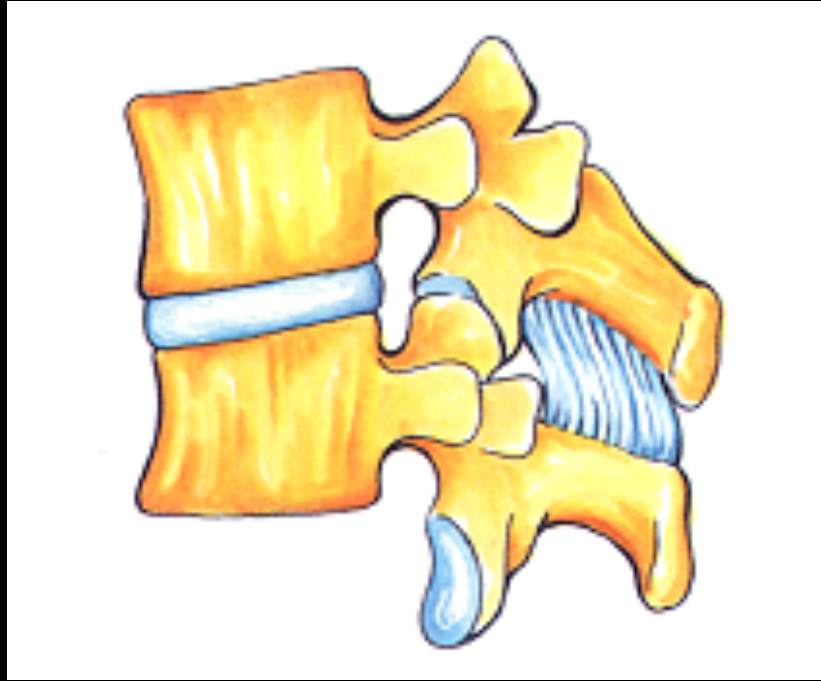


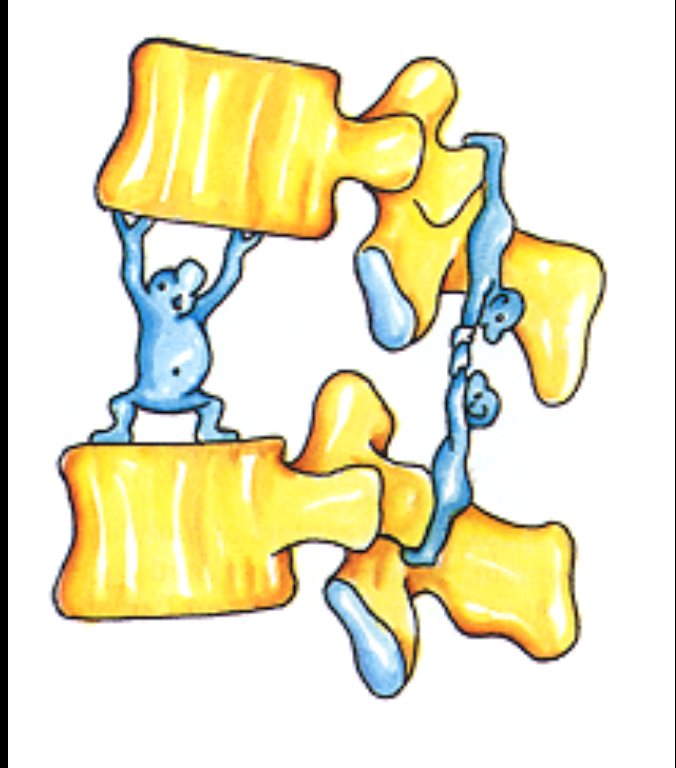
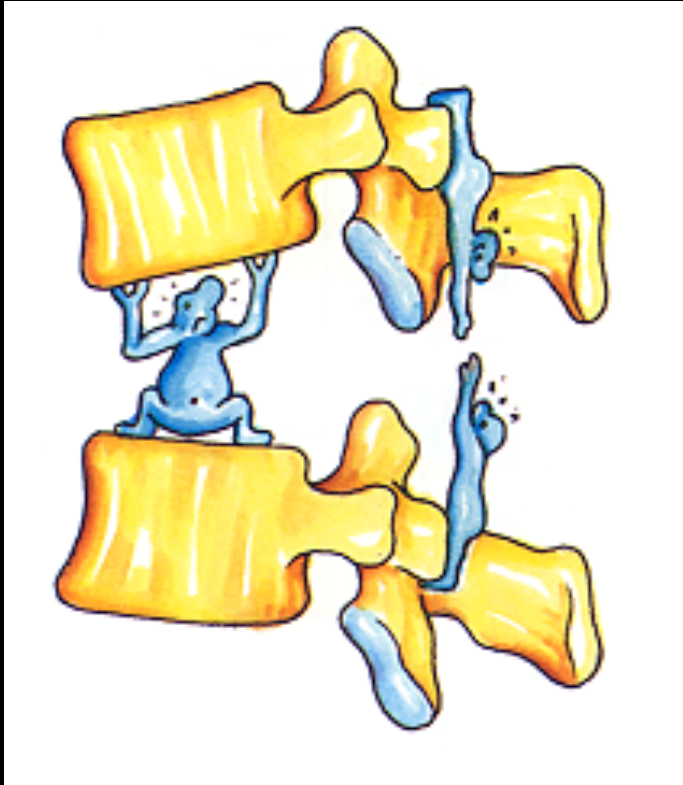


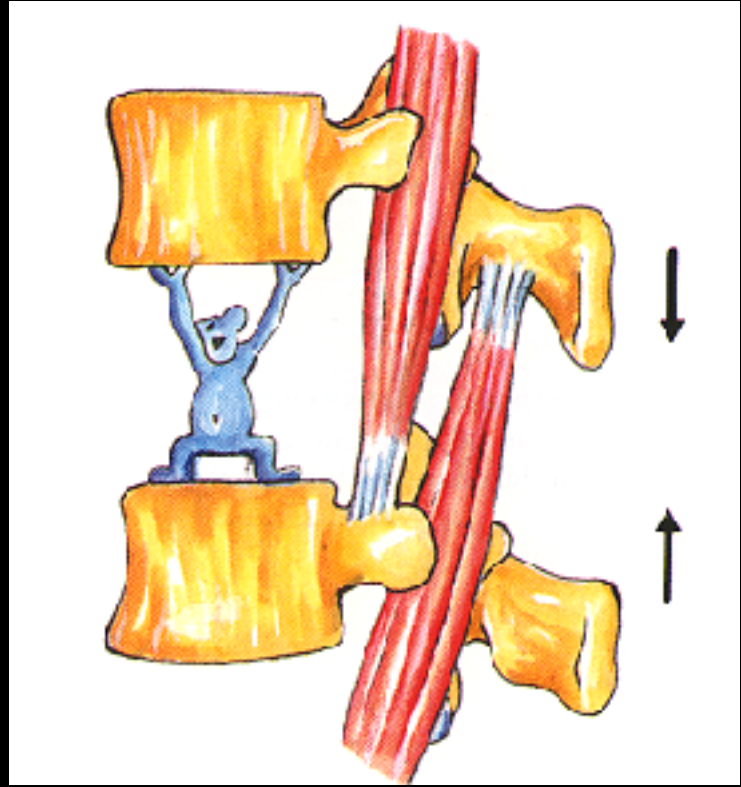
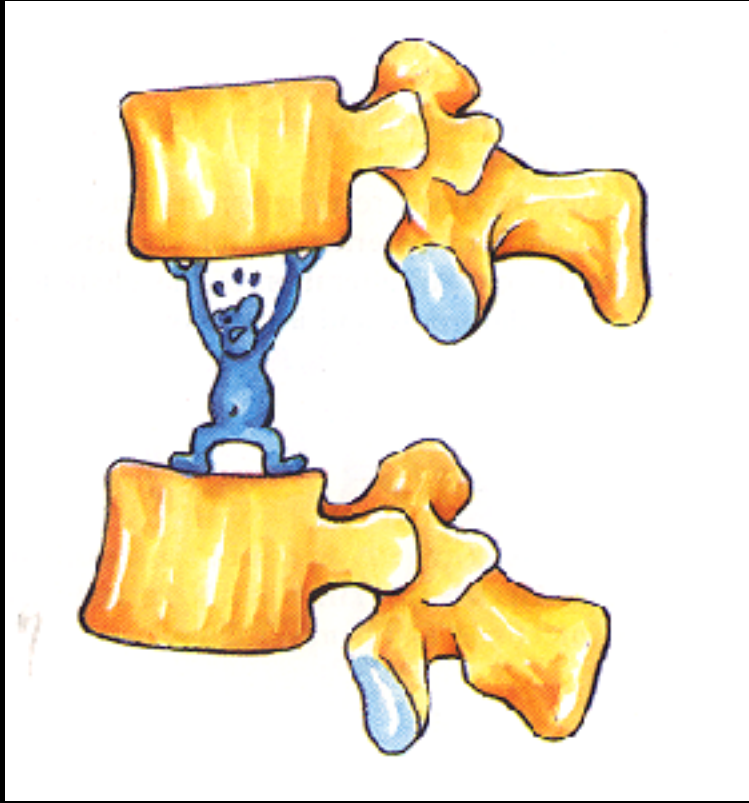





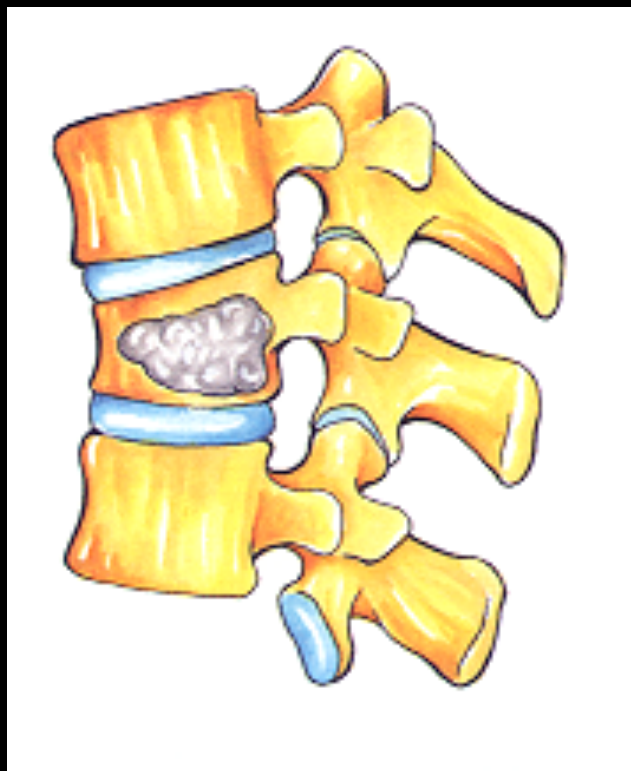


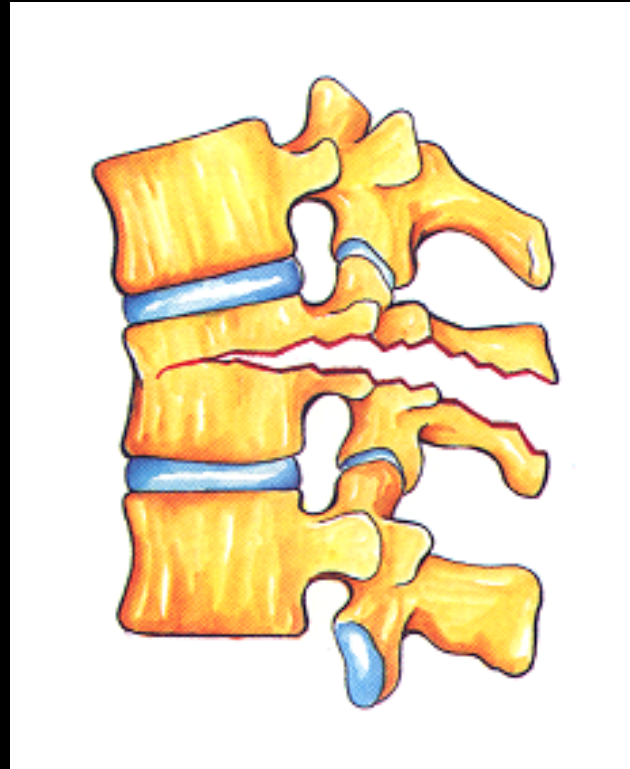
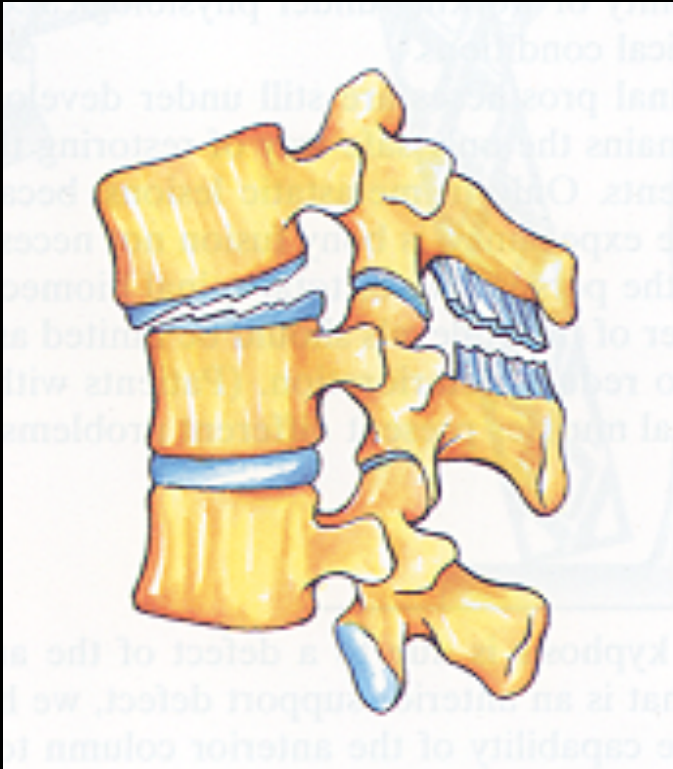




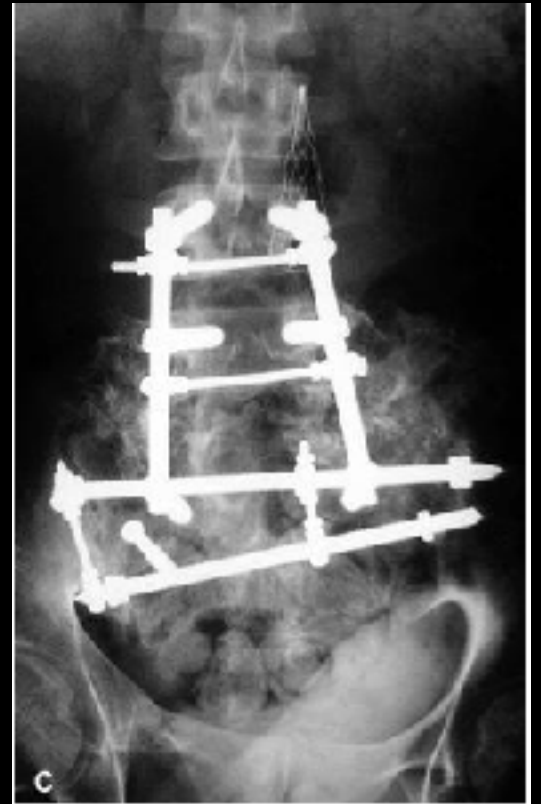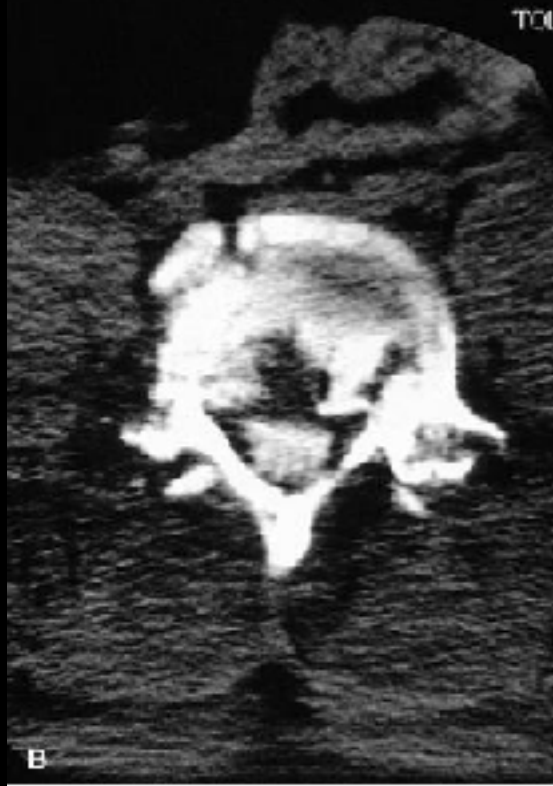
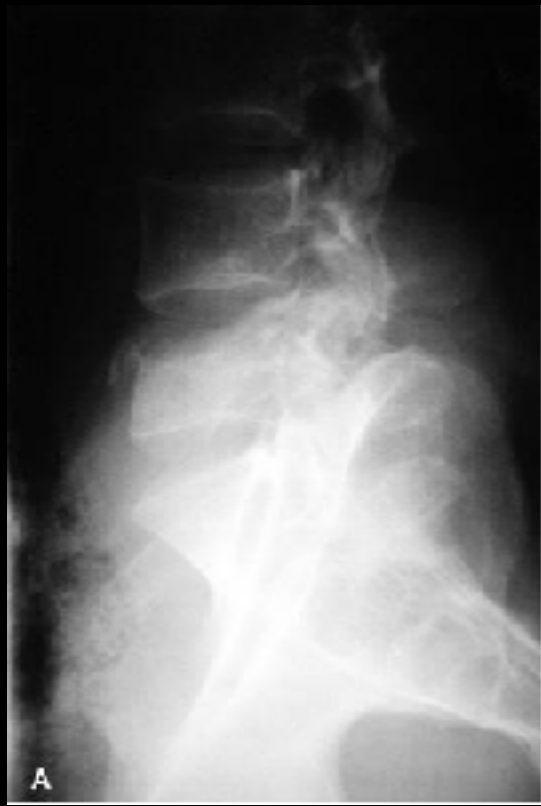

# Παθολογία - Διαταραχή της Μηχανικής Ακεραιότητας



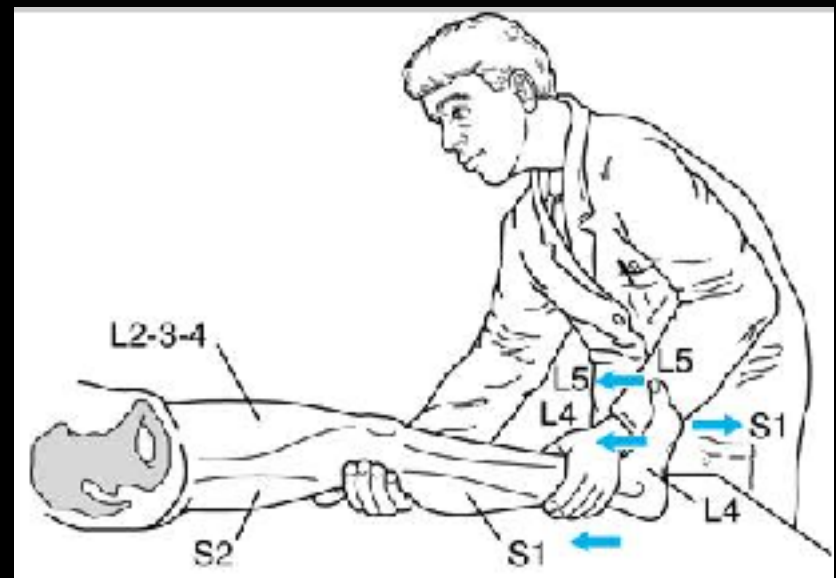
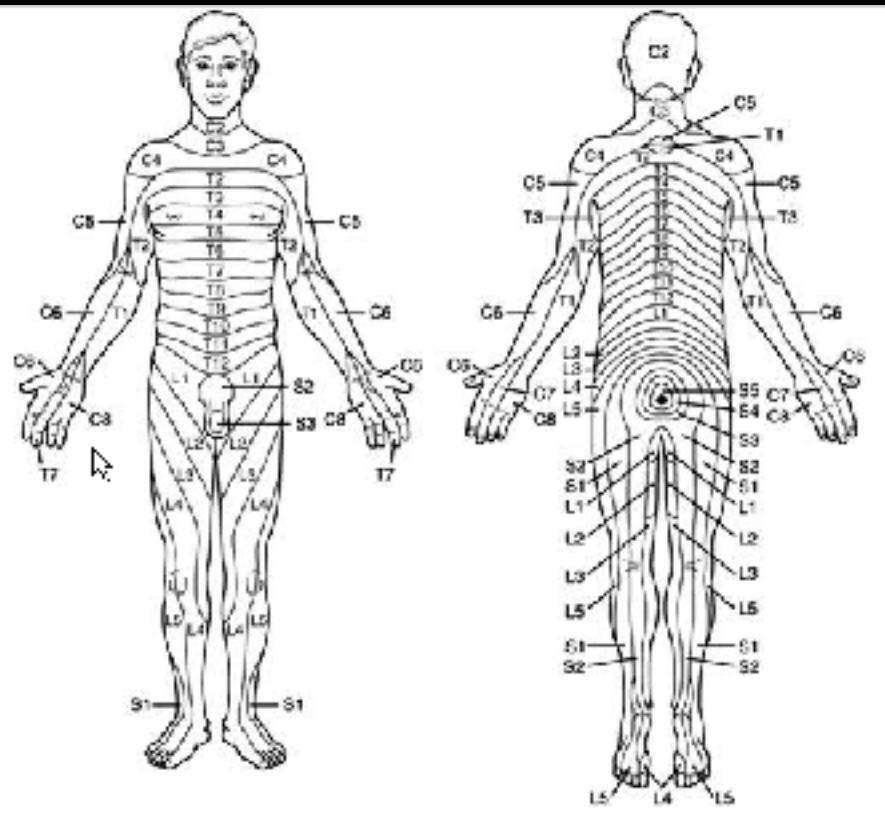


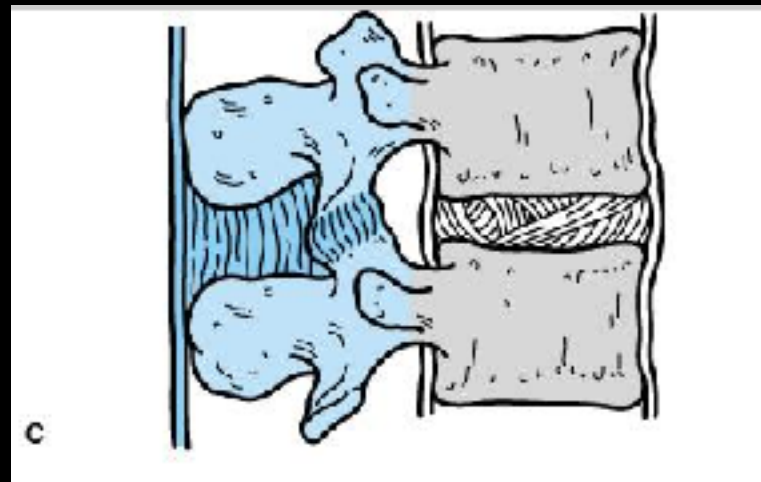
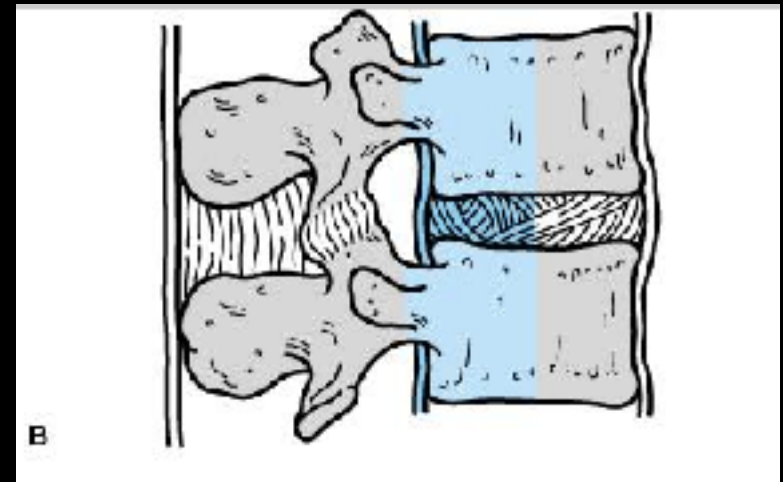
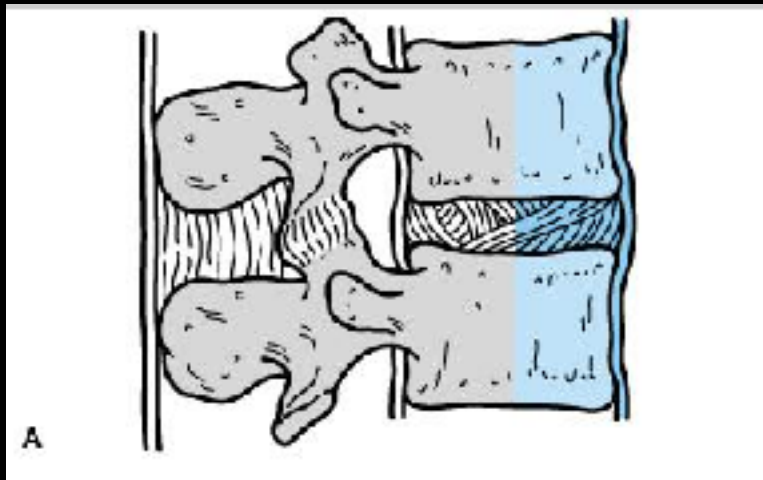
- ✓ COMPRESSION FRACTURES
- ✓ BURST FRACTURES
- ✓ FLEXION – DISTRACTION
- ✓ FRACTURE DISLOCATIONS





5	full strength adequate to powerfully resist the examiner
4	power to resist but not overcome the examiner
3	power to overcome gravity
2	power to move the joint but not to overcome gravity
1	capacity to contract the muscle without functional power
0	no motor function at all





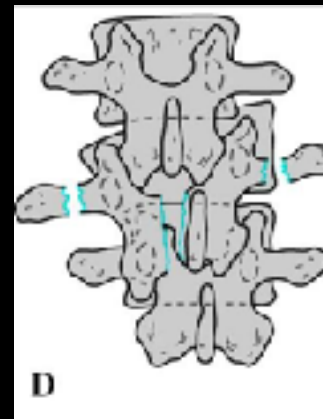
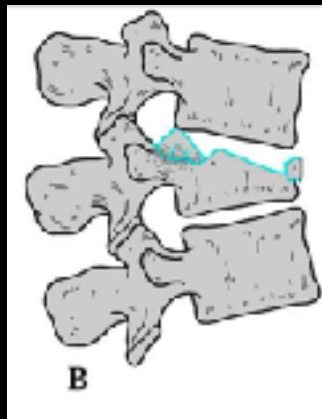
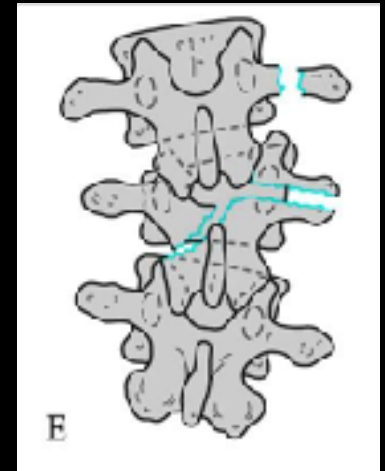
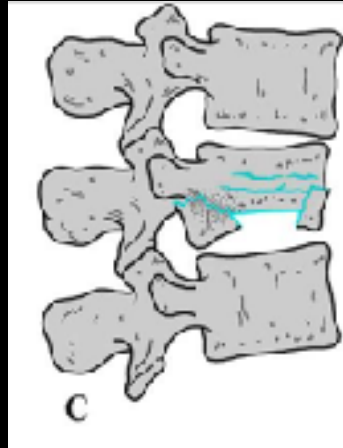
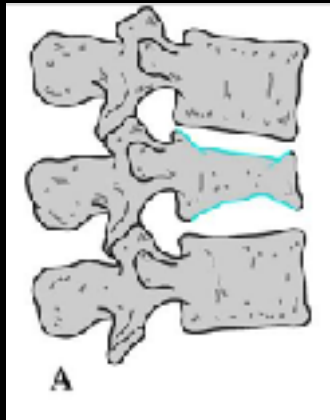
### **Three-column model of Denis.**

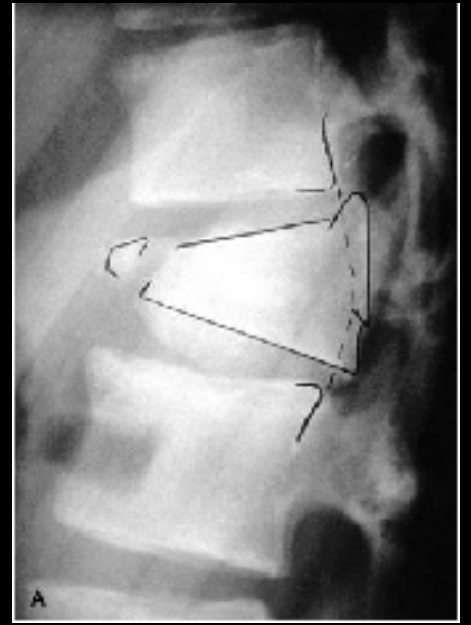
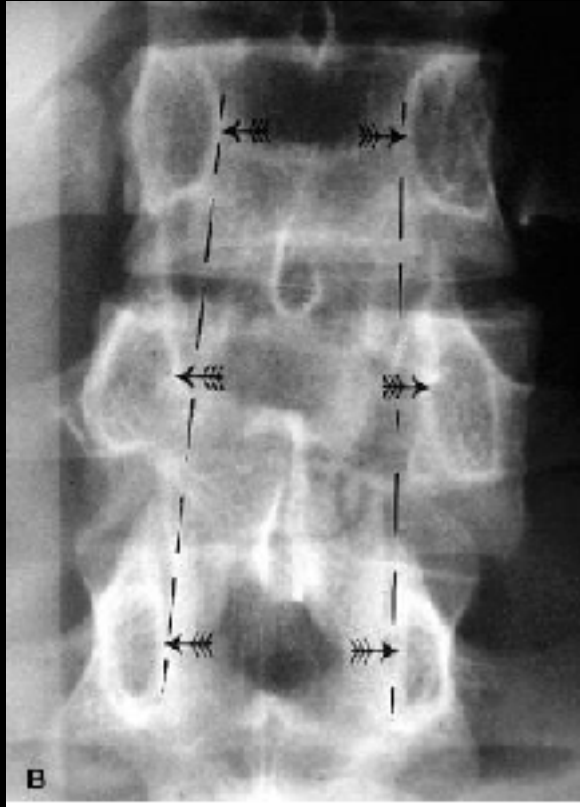
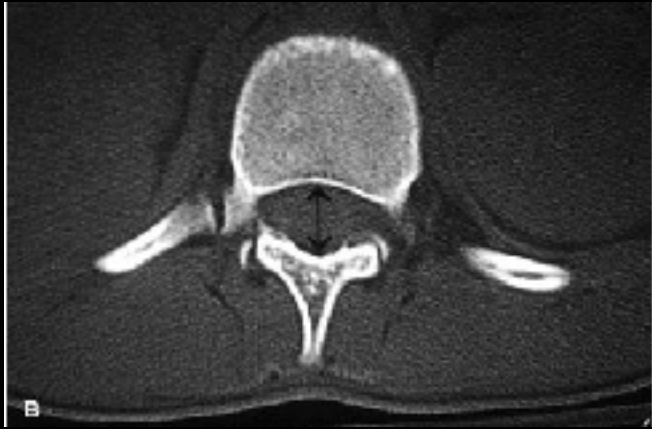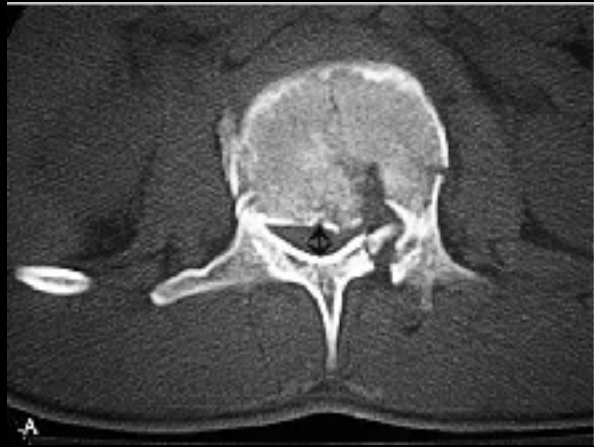A: Anterior column. B: Middle column. C: Posterior column.

# ΑΣΤΑΘΕΙΣ ΚΑΚΩΣΕΙΣ

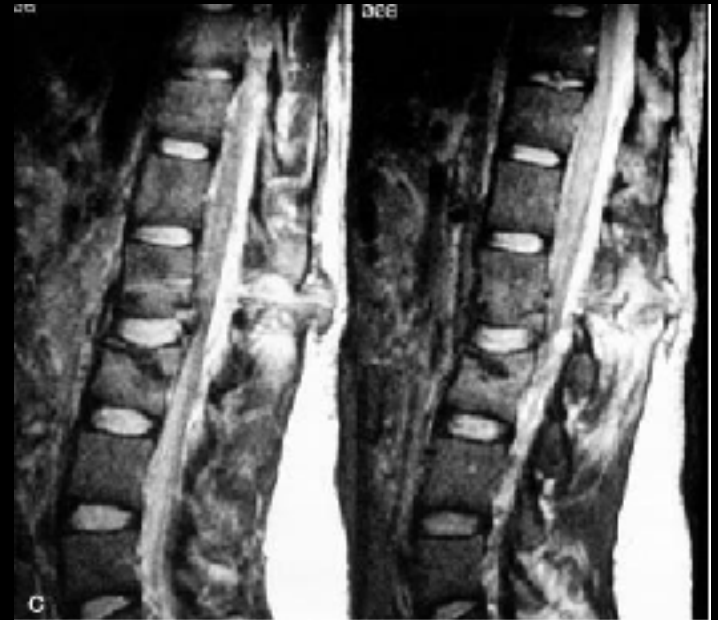
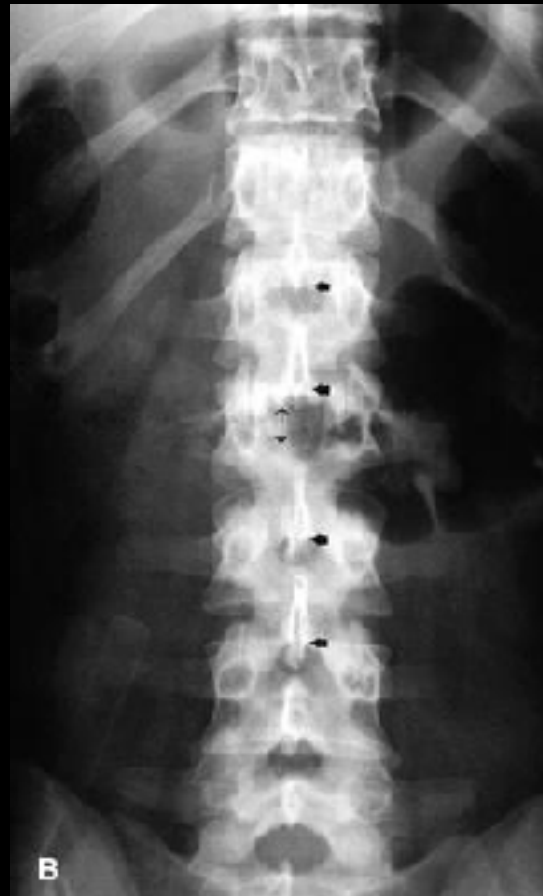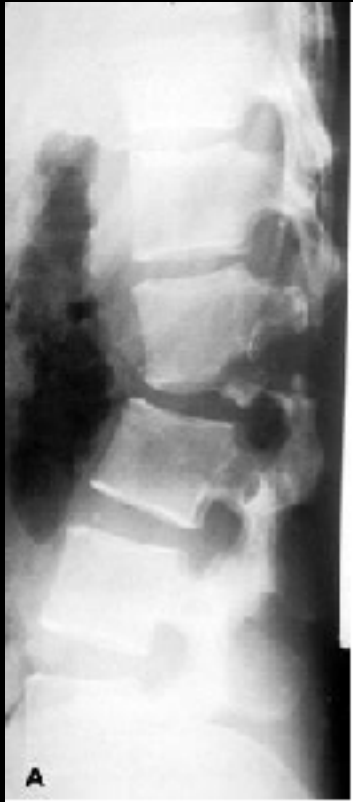- ✓ Διάσπαση τριών κολωνών
- ✓ >50% καθίζηση πρόσθιου φλοιού
- ✓ >25° εστιακή κύφωση
- ✓ Υπαρξη νευρολογικού ελλείμματος

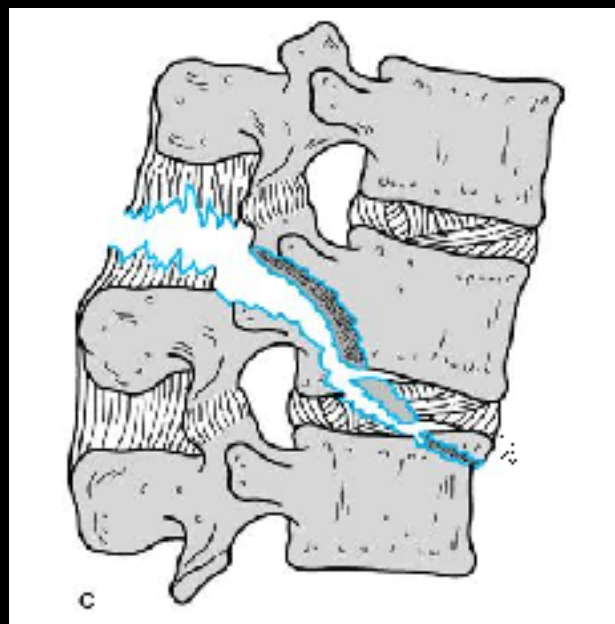
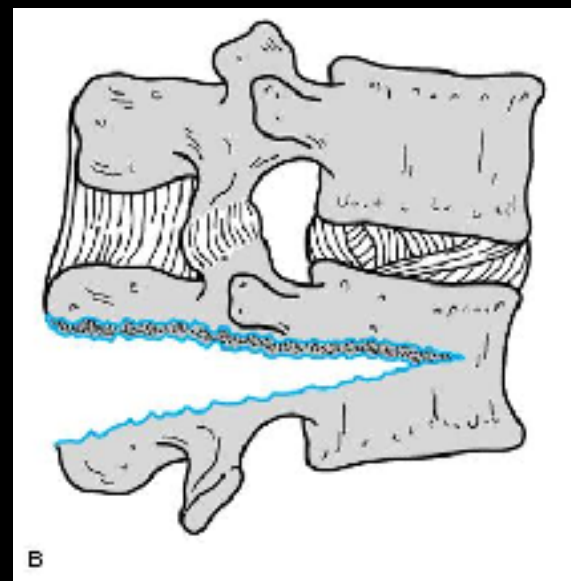
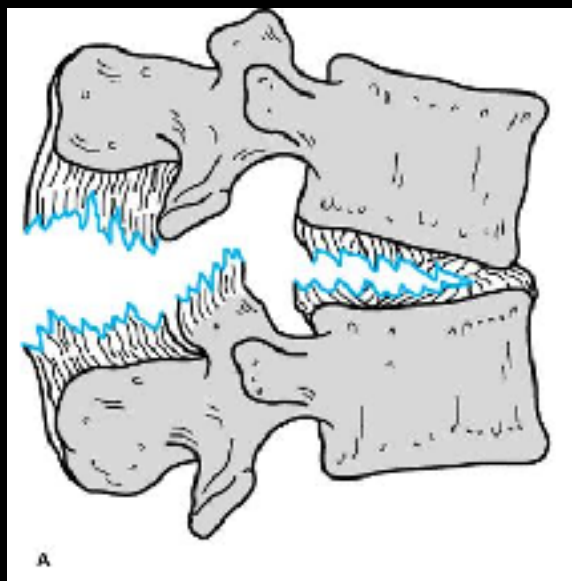
# BURST FRACTURES



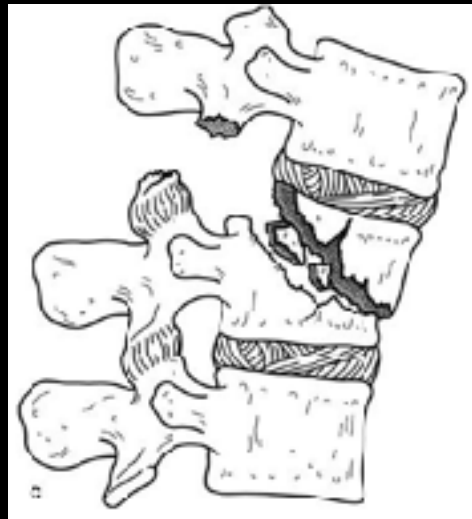
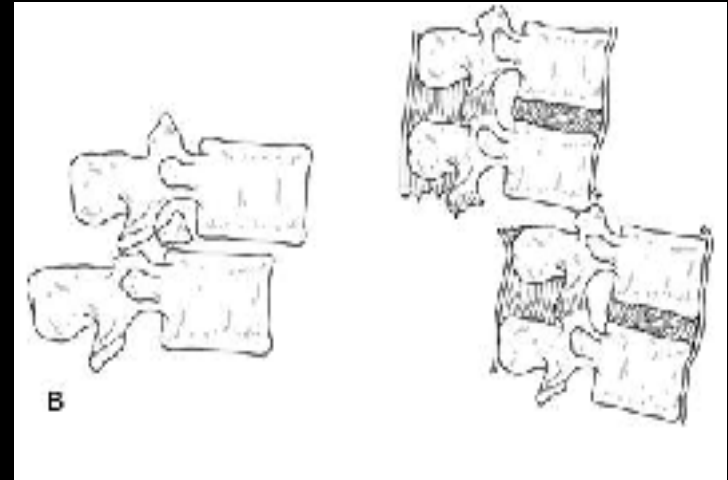
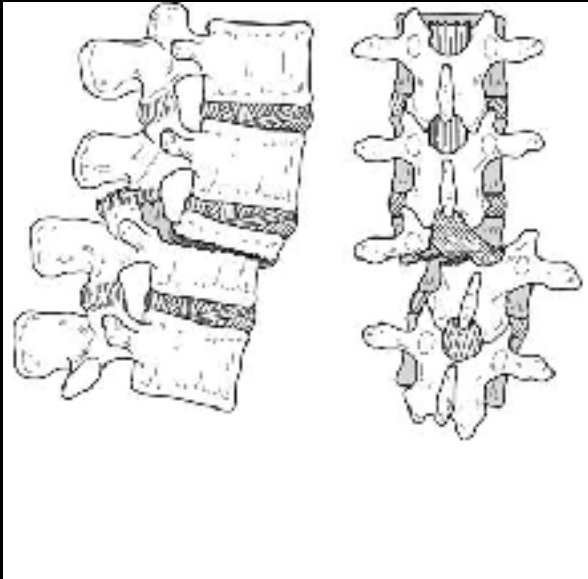


# FLEXION – DISTRACTION





# FRACTURE – DISLOCATIONS



- A: Flexion–rotation
- B: Shear
- C: Flexion–distraction

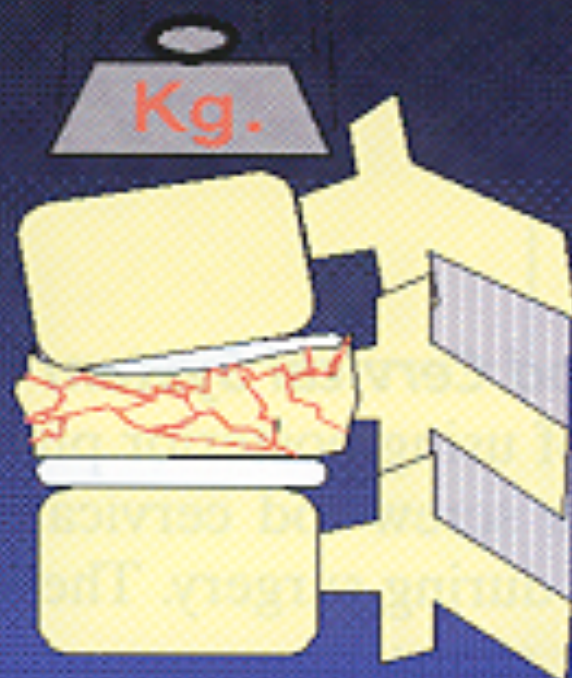


# Ταξινομηση

**Magerl, Aebi, Getzbein, Harms, Nazarian**  
**1994**

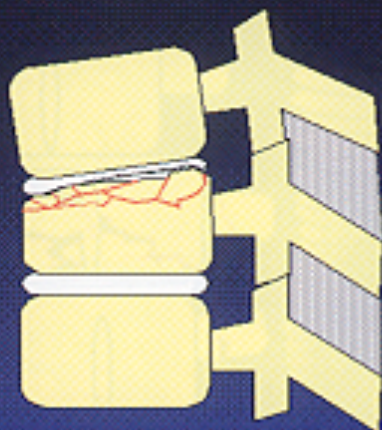
A

VERTEBRAL  
BODY  
COMPRESSION



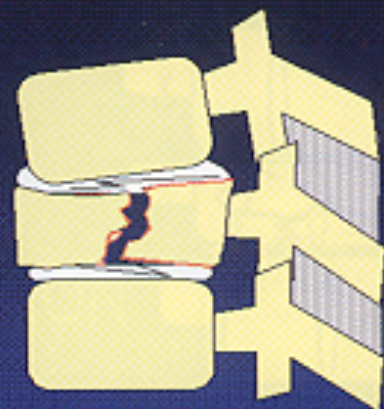
A1

IMPACTION

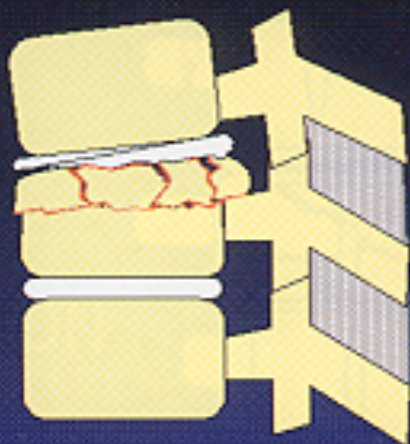


A2

SPLIT

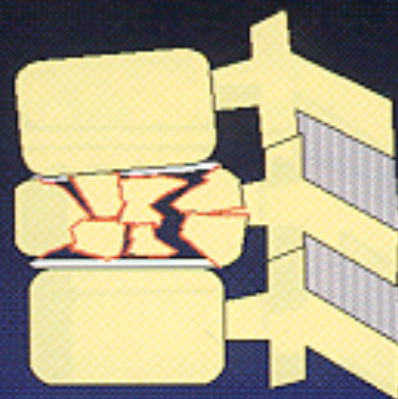


A 3



INCOMPLETE  
BURST

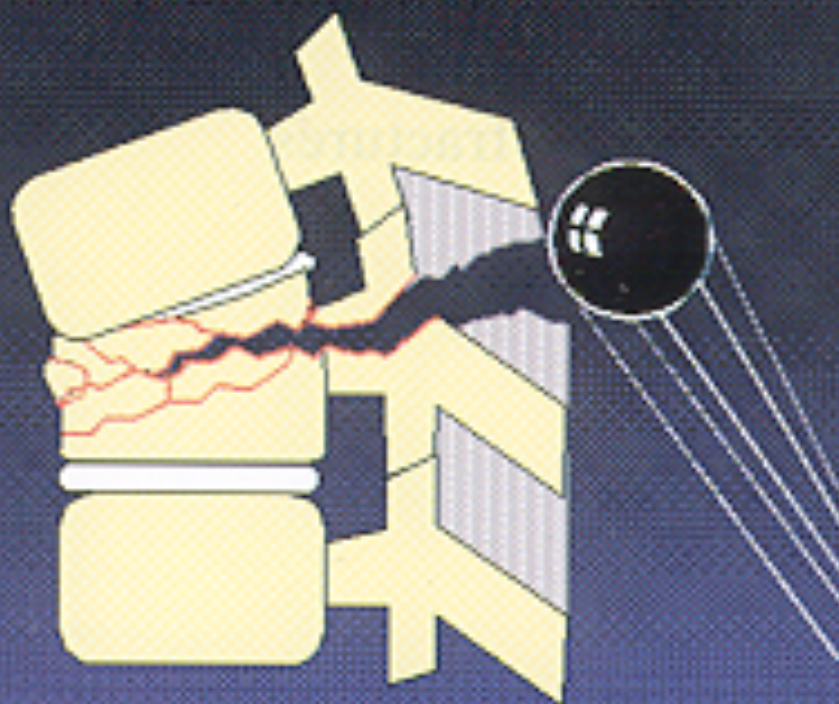
A 3



COMPLETE  
BURST


B

ANTERIOR AND  
POSTERIOR  
ELEMENT  
INJURY WITH  
DISTRACTION



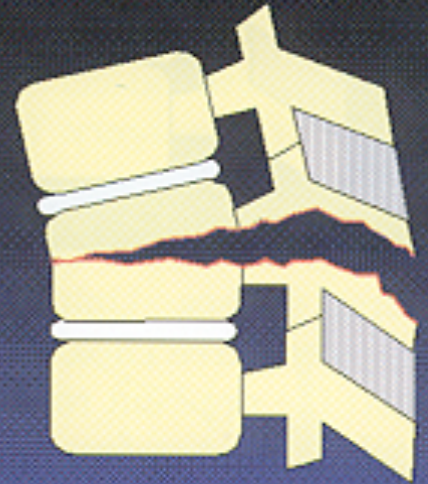B 1

DISTRACTION  
FLEXION  
INTRA-ARTICULAR



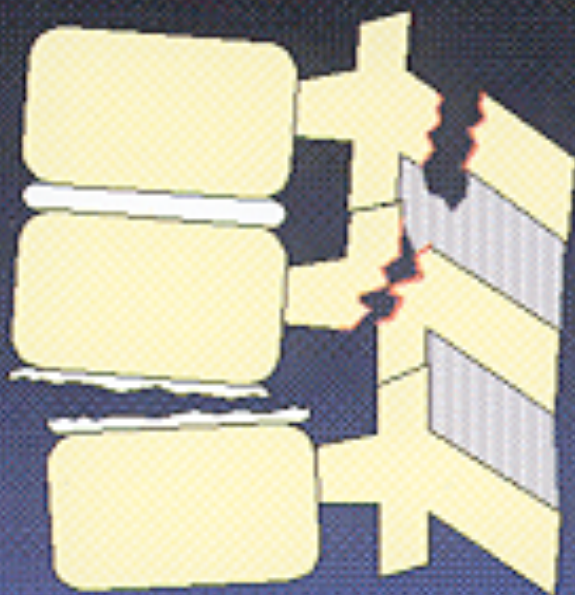
B 2

DISTRACTION  
FLEXION  
TRANSOSSEOUS



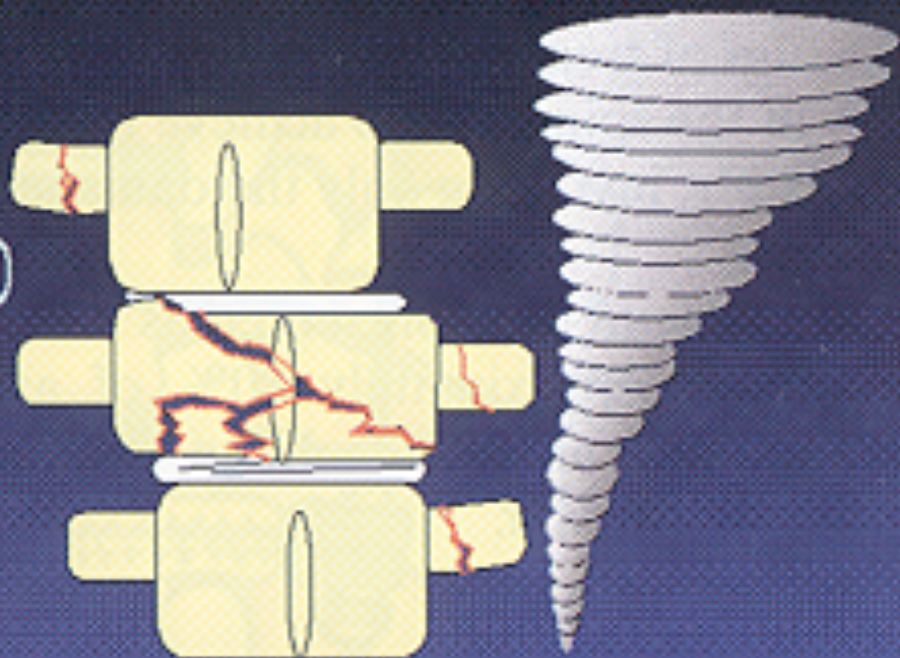
B 3

DISTRACTION  
EXTENSION



C

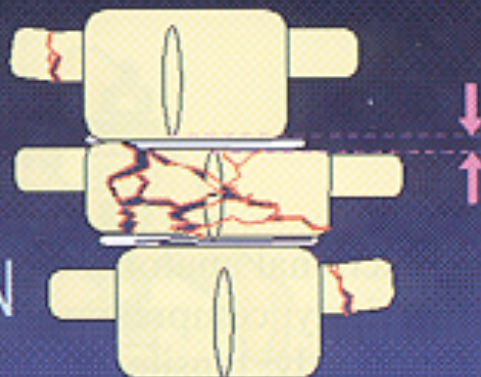
ANTERIOR AND  
POSTERIOR  
ELEMENT  
INJURY WITH  
TORSION





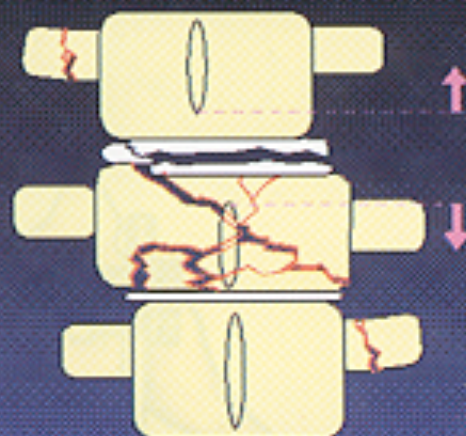
C1

TORSION  
COMPRESSION



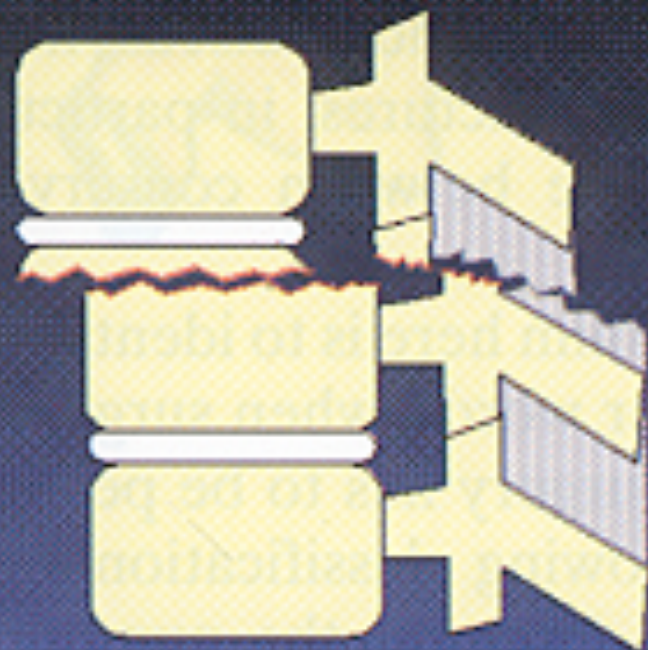
C2

TORSION  
DISTRACTION

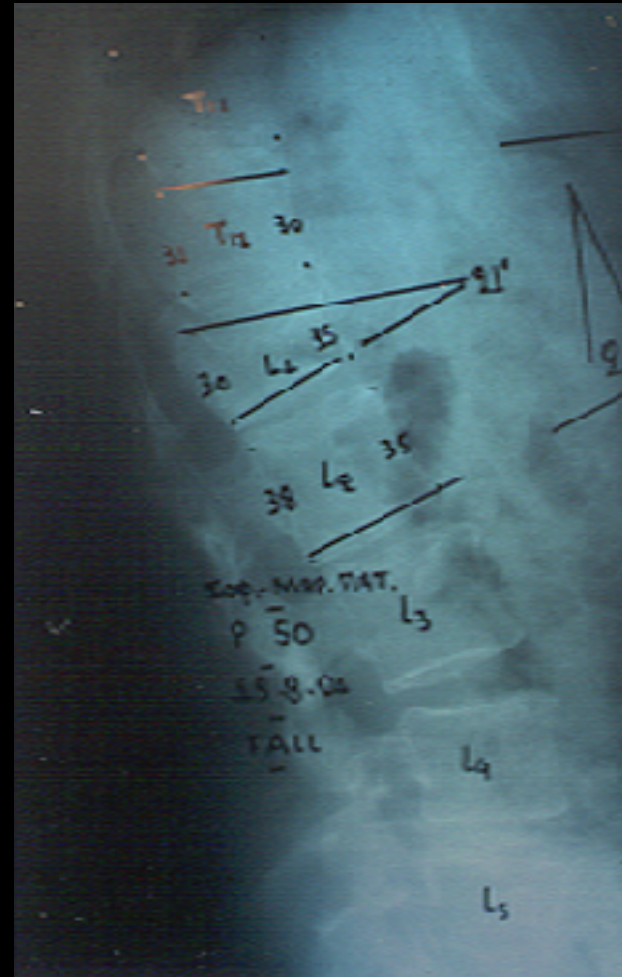
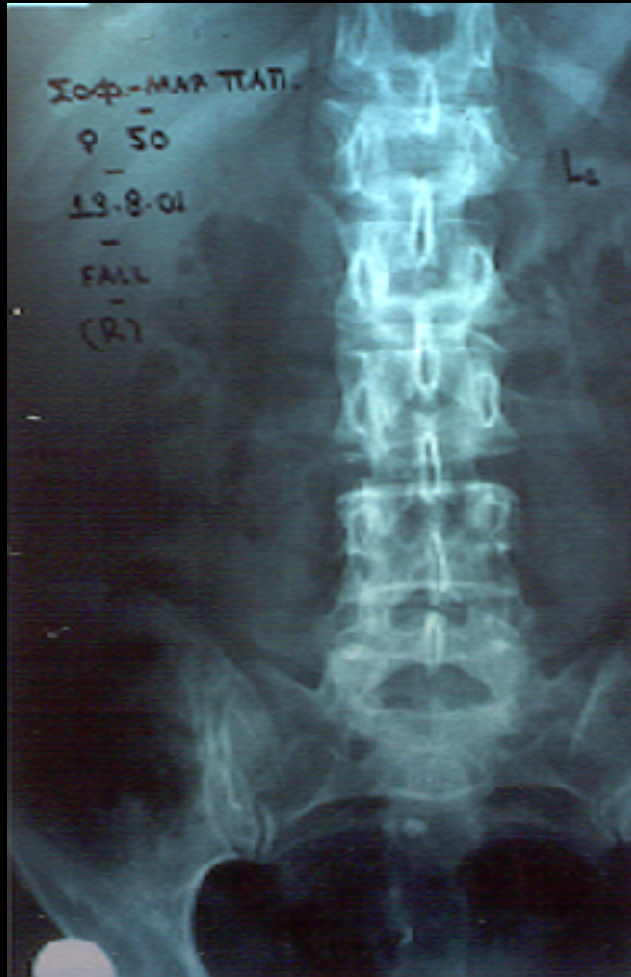

C 3

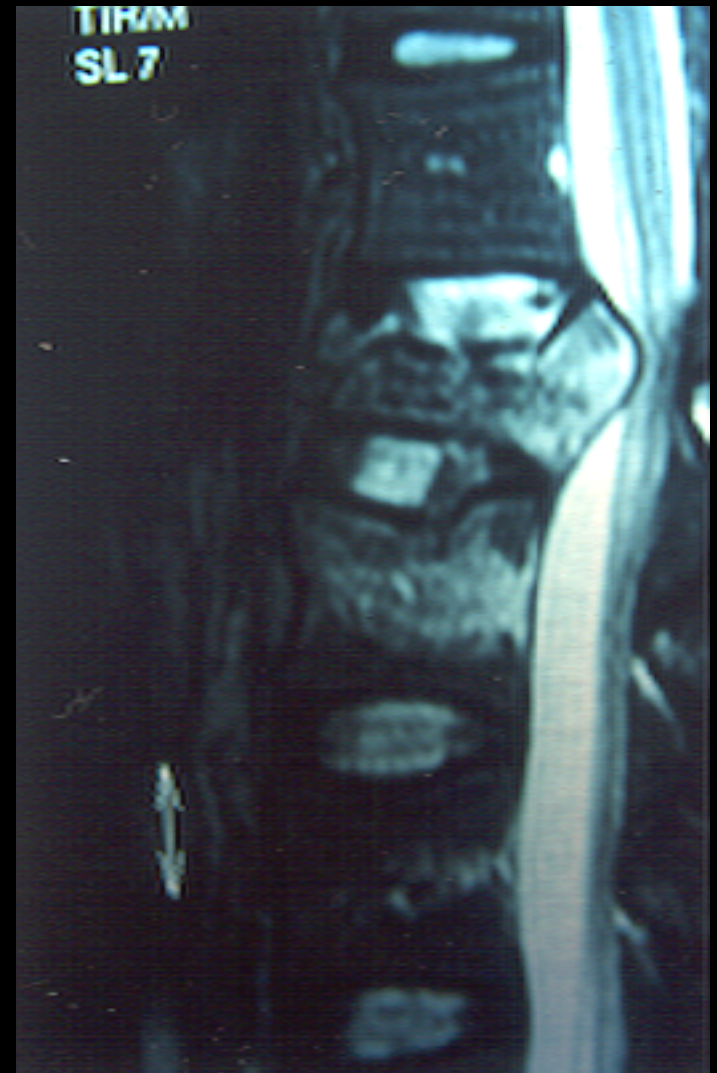
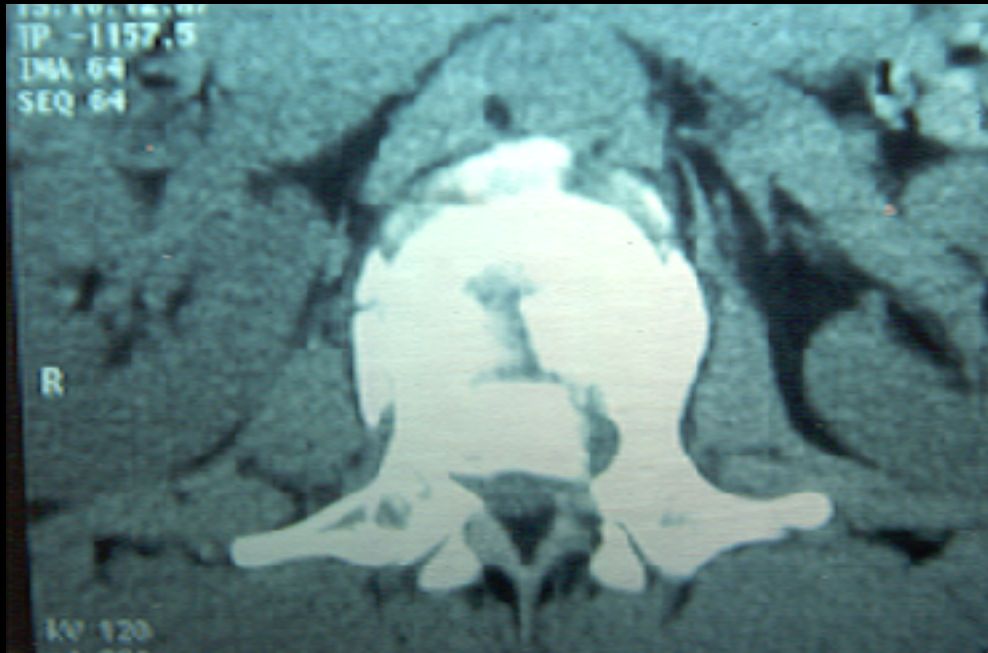
TORSION  
SHEAR



# Διάγνωση



# Διάγνωση



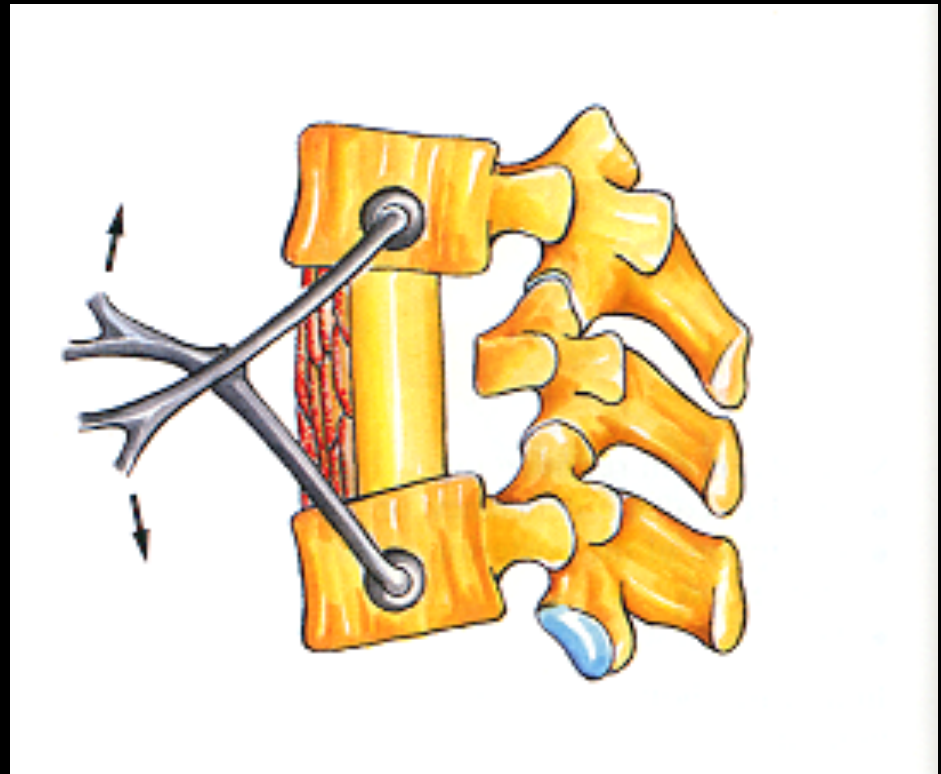
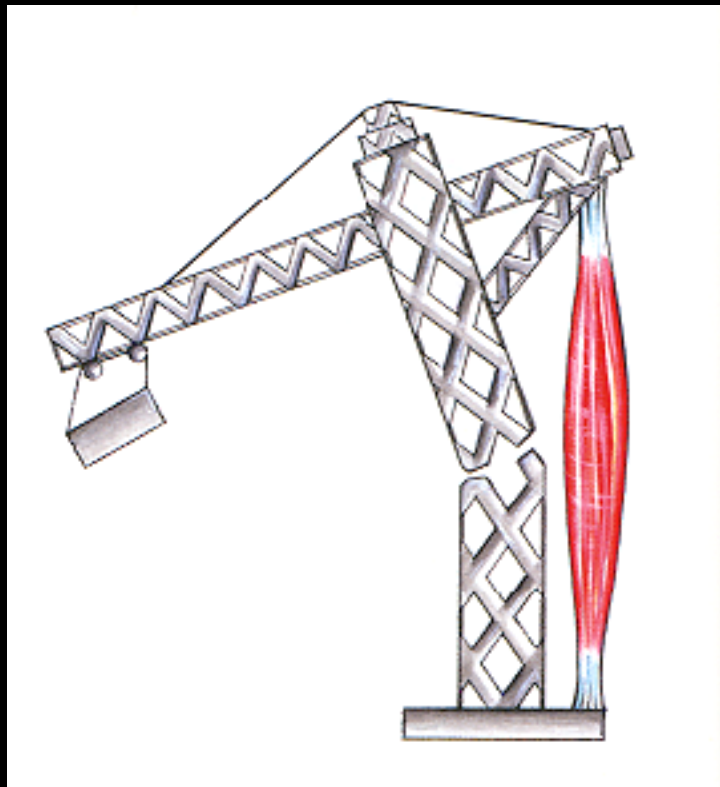
# ΓΗΡΙΑΤΡΙΚΟ ΤΡΑΥΜΑ

- ΡΑΓΔΑΙΩΣ ΑΥΞΑΝΟΜΕΝΟ ΠΡΟΒΛΗΜΑ
- ΜΕΓΑΛΗ ΘΝΗΣΙΜΟΤΗΤΑ ΚΑΙ ΝΟΣΗΡΟΤΗΤΑ
- ΚΑΚΗ ΙΣΟΡΡΟΠΙΑ ΑΥΞΑΝΕΙ ΤΟΝ ΚΙΝΔΥΝΟ ΠΤΩΣΗΣ
- ΟΣΤΕΟΠΩΡΩΣΗ ΚΑΘΙΣΤΑ ΠΙΟ ΕΥΑΛΩΤΑ ΤΑ ΟΣΤΑ
- ΣΥΝΥΠΑΡΧΟΥΣΕΣ ΠΑΘΗΣΕΙΣ ΑΥΞΑΝΟΥΝ ΤΟΝ ΔΙΕΓΧΕΙΡΗΤΙΚΟ ΚΙΝΔΥΝΟ
- ΑΠΑΙΤΕΙΤΑΙ ΕΞΟΝΥΧΙΣΤΙΚΟΣ ΠΛΗΝ ΟΜΩΣ ΓΡΗΓΟΡΟΣ ΠΡΟΕΓΧΕΙΡΗΤΙΚΟΣ ΕΛΕΓΧΟΣ

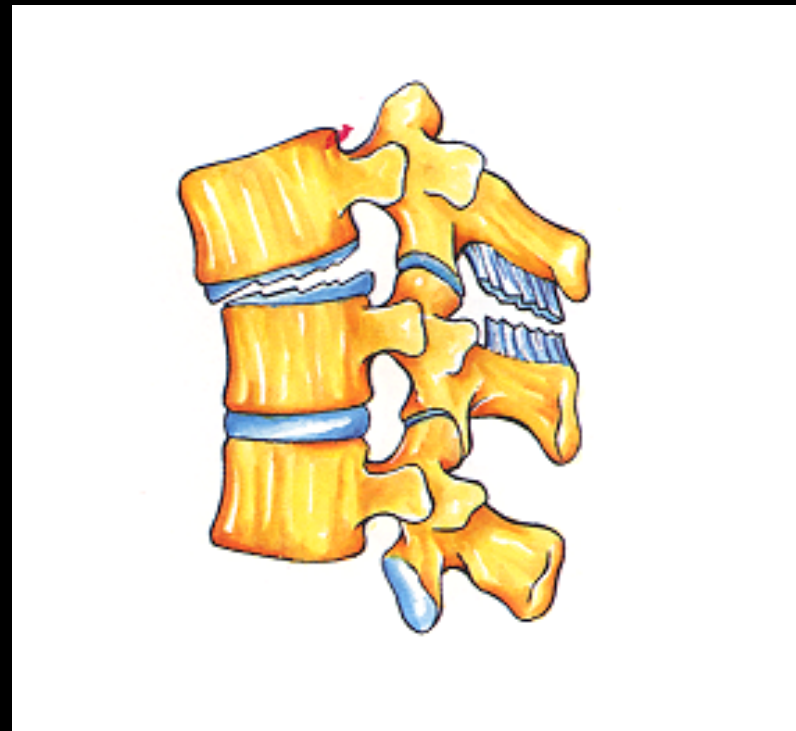
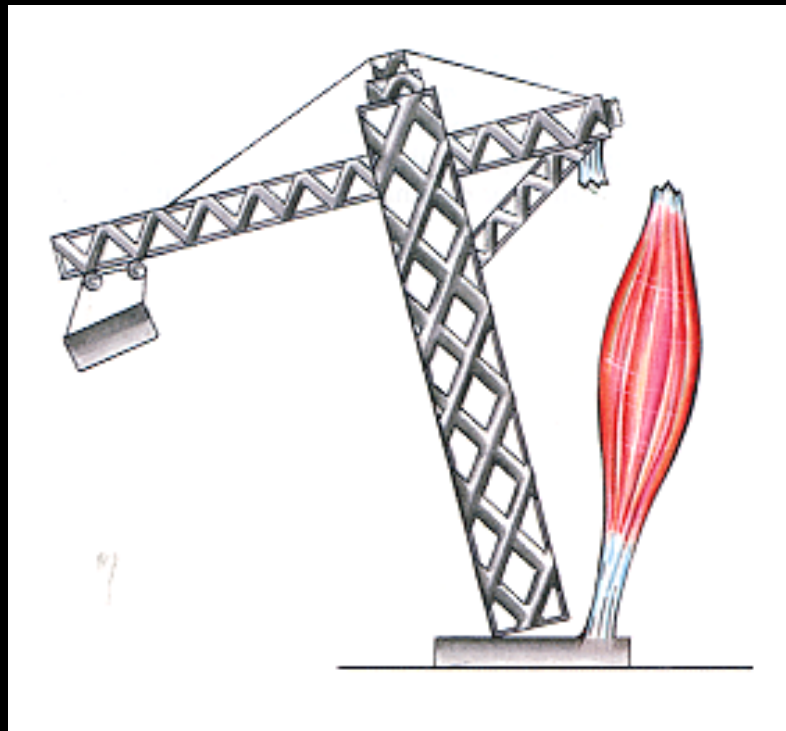
# ΑΠΟΚΑΤΑΣΤΑΣΗ

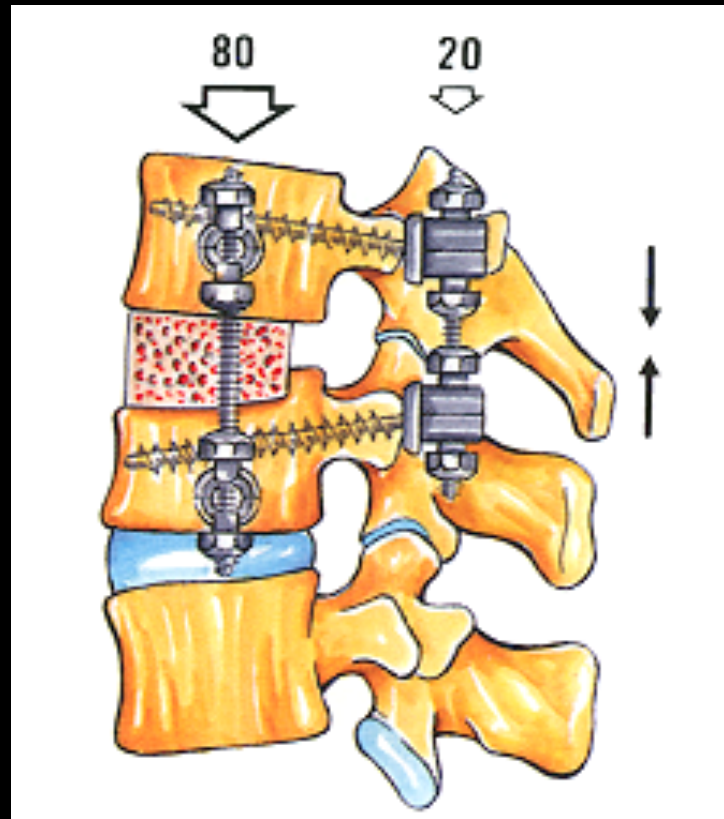
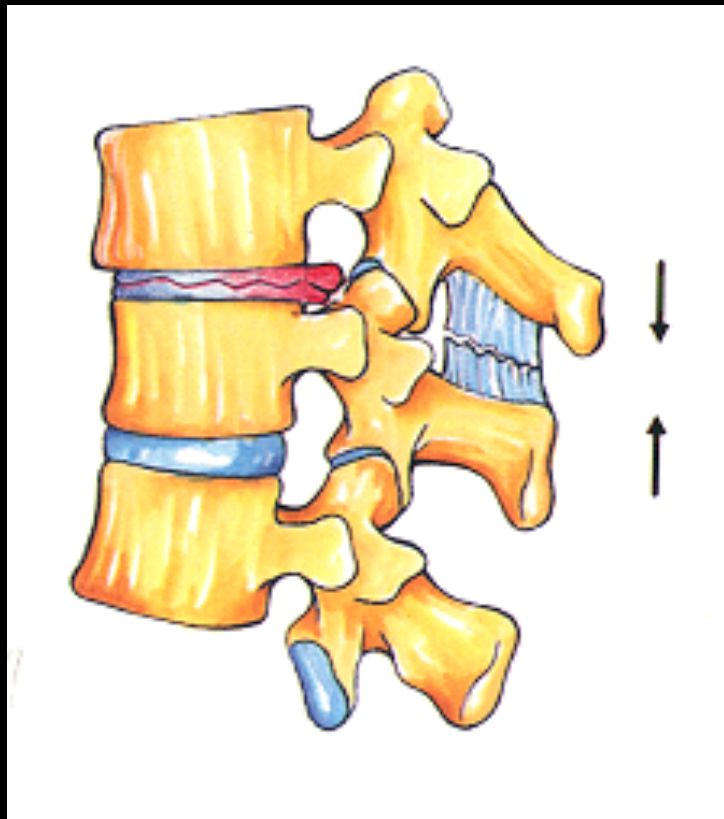
- ΕΠΑΡΚΗΣ ΑΠΟΚΑΤΑΣΤΑΣΗ ΔΙΑΣΦΑΛΙΖΕΙ ΤΟ ΚΑΛΥΤΕΡΟ ΔΥΝΑΤΟ ΧΕΙΡΟΥΡΓΙΚΟ ΑΠΟΤΕΛΕΣΜΑ
- ΕΙΔΙΚΟΙ ΤΗΣ ΑΠΟΚΑΤΑΣΤΑΣΗΣ, ΦΥΣΙΟΘΕΡΑΠΕΥΤΕΣ, ΔΙΑΙΤΟΛΟΓΟΙ, ΚΟΙΝΩΝΙΚΟΙ ΛΕΙΤΟΥΡΓΟΙ ΠΡΕΠΕΙ ΝΑ ΕΠΙΣΤΡΑΤΕΥΘΟΥΝ.

# Αρχές Θεραπείας



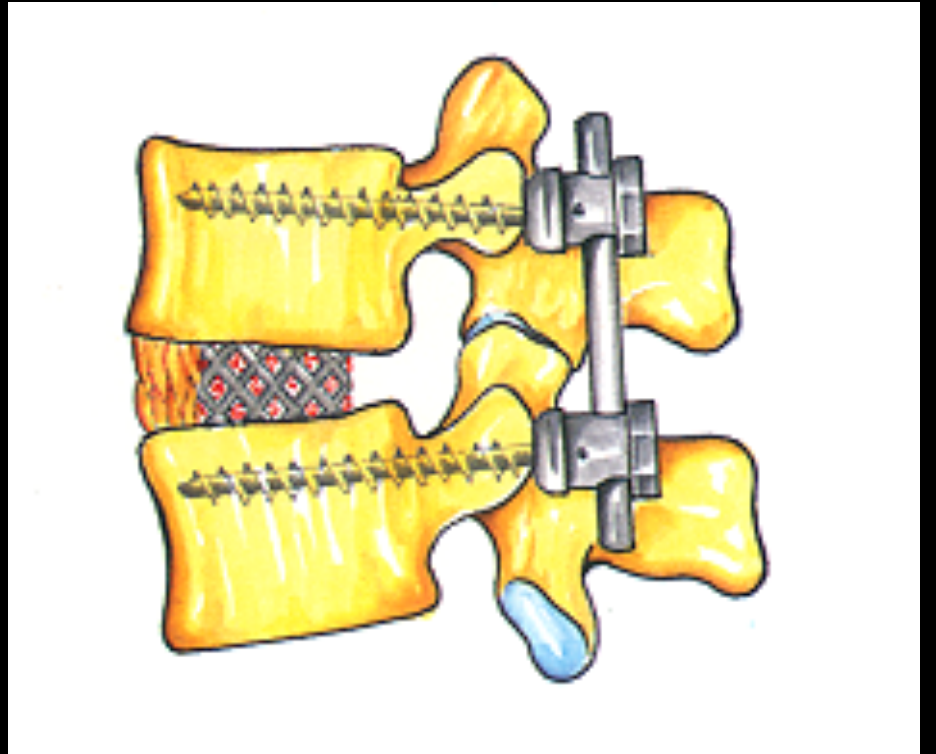
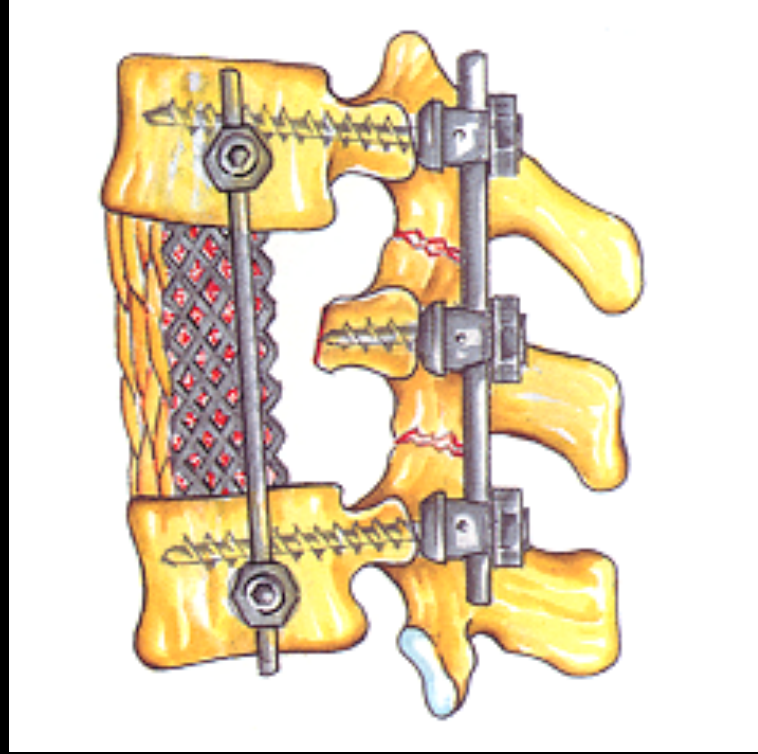


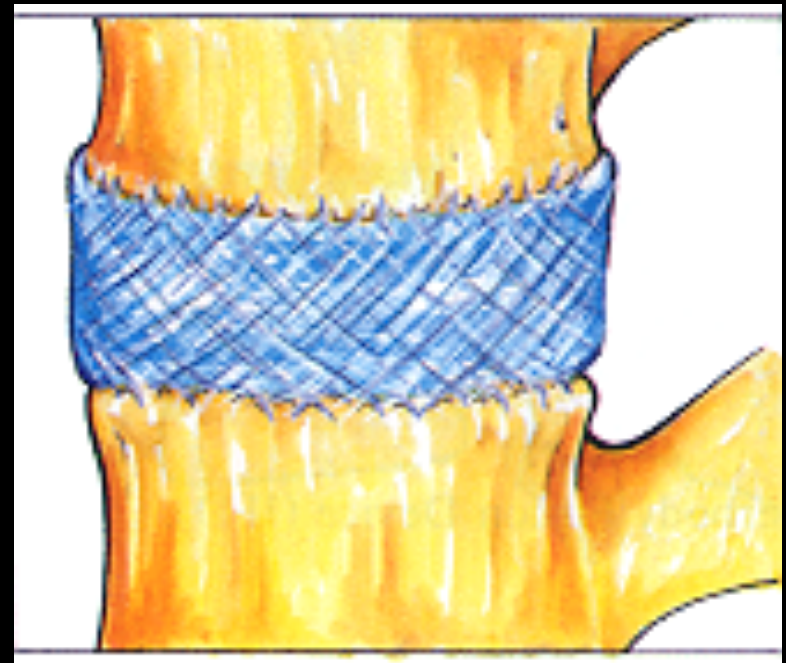
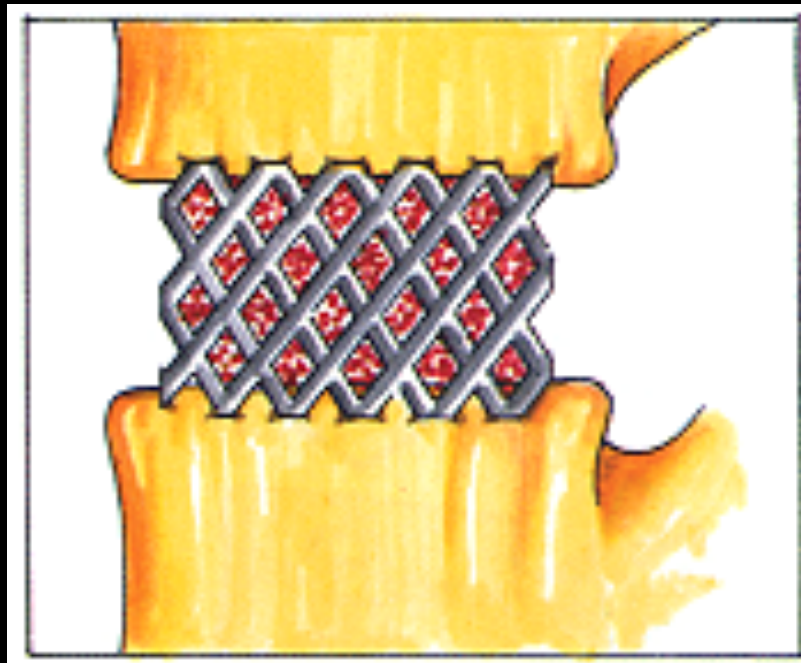


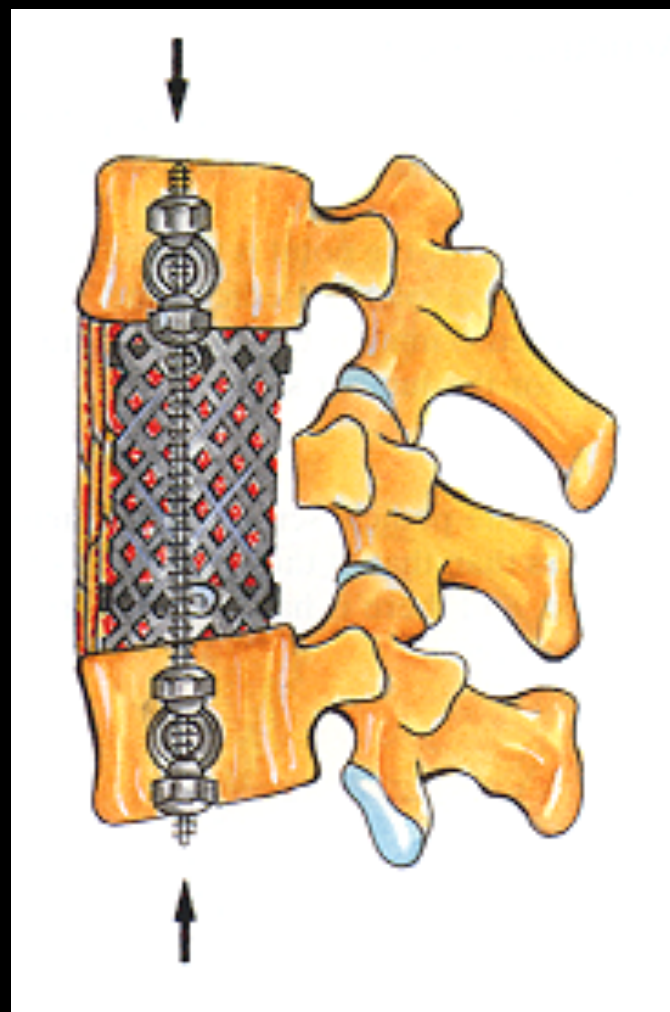

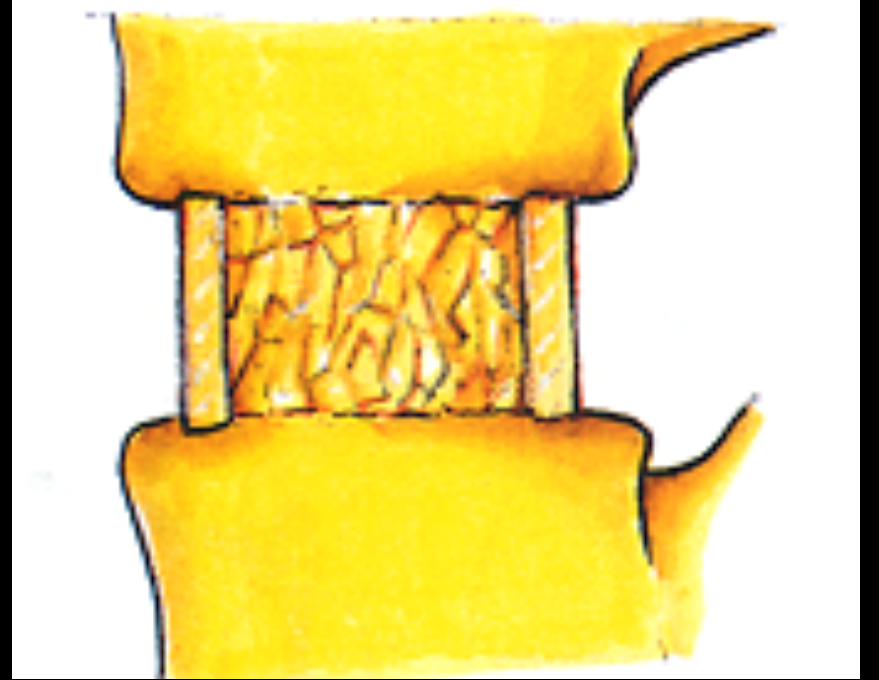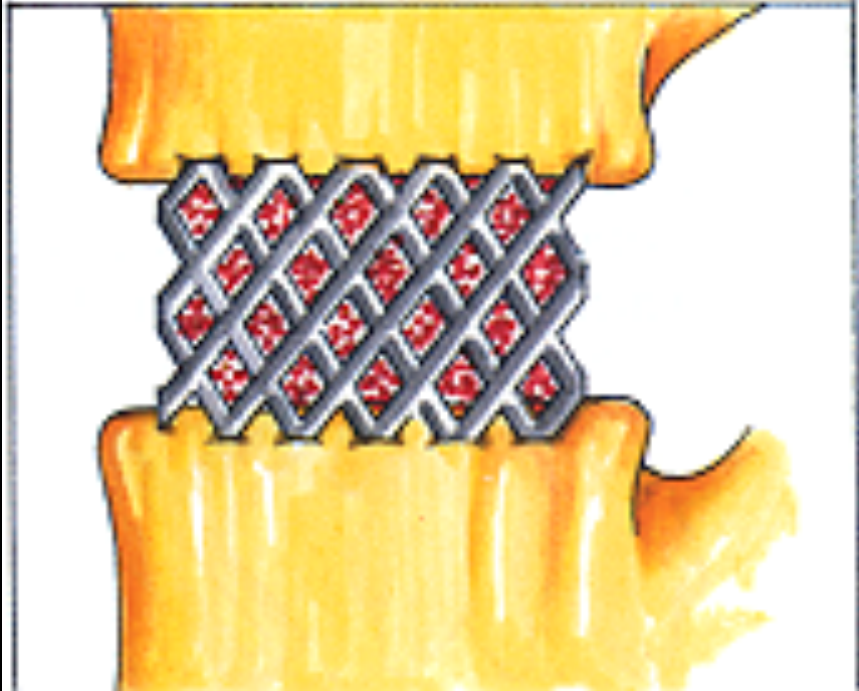
Μεταλλικά εμφυτεύματα

Πρόσθια κολώνα



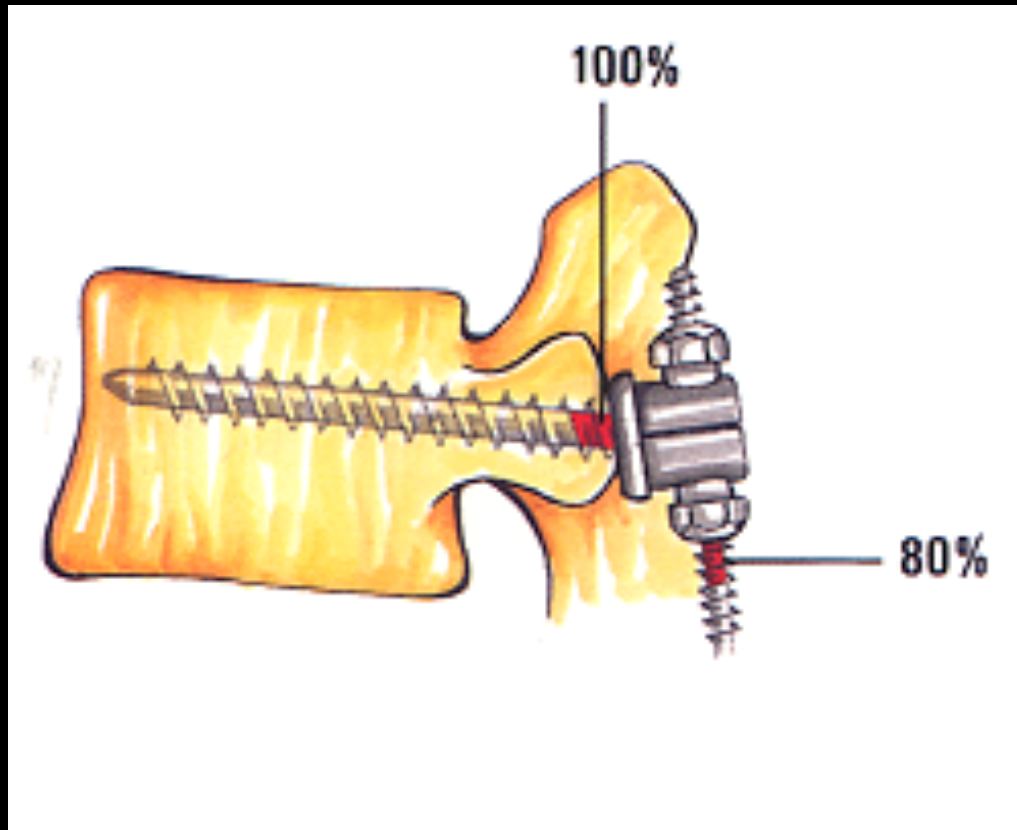


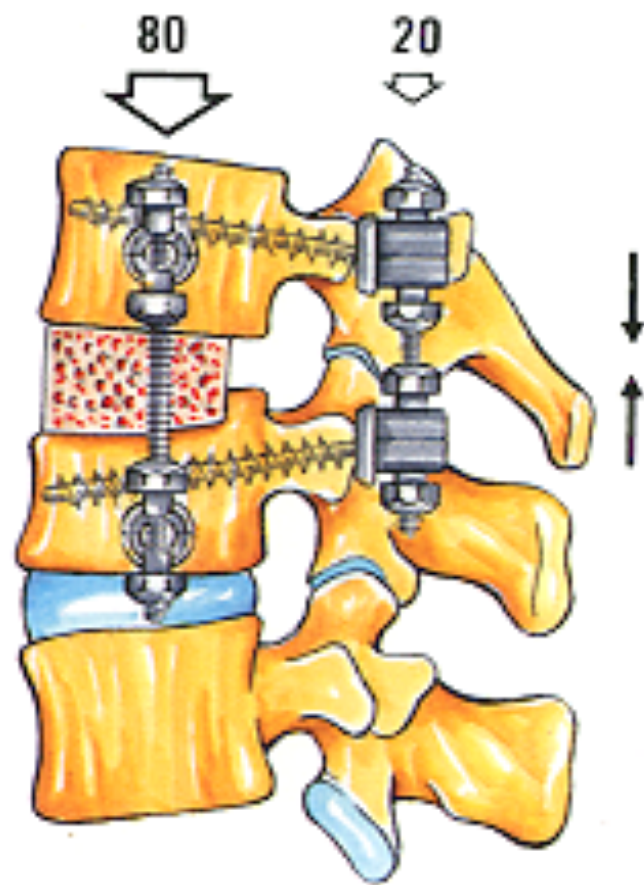
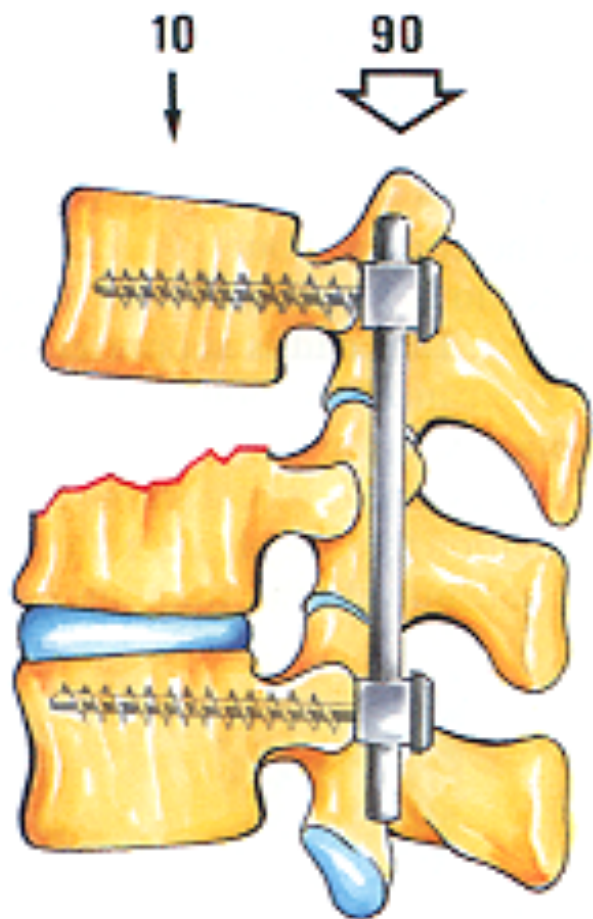


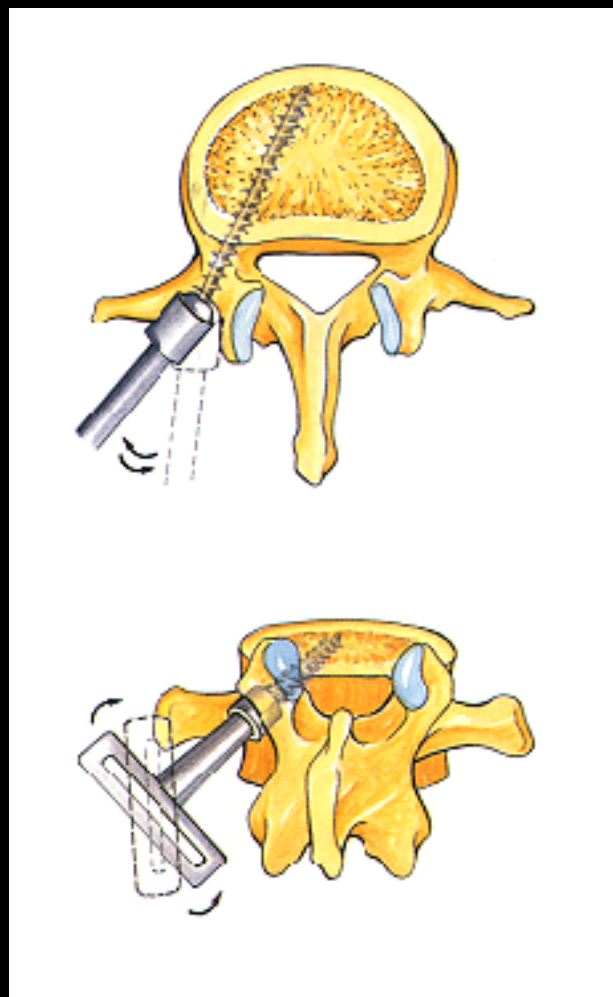
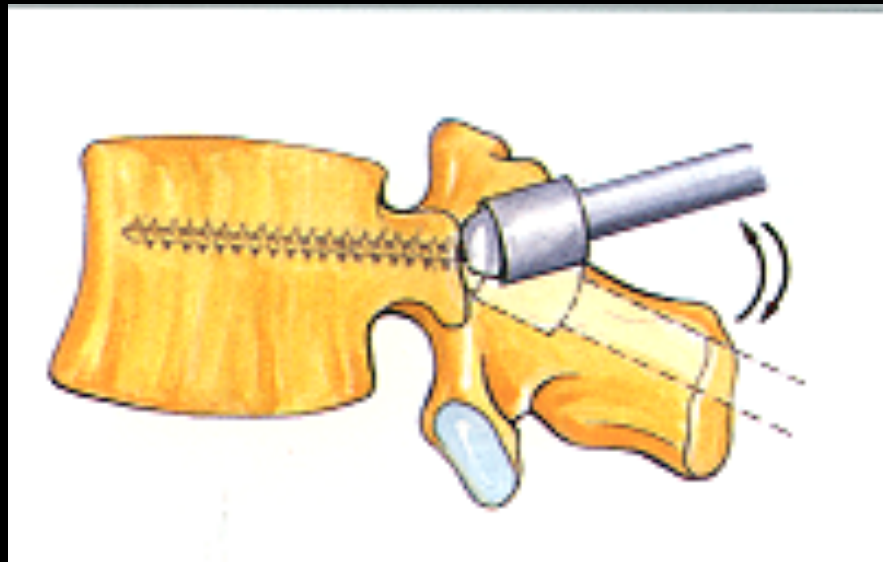


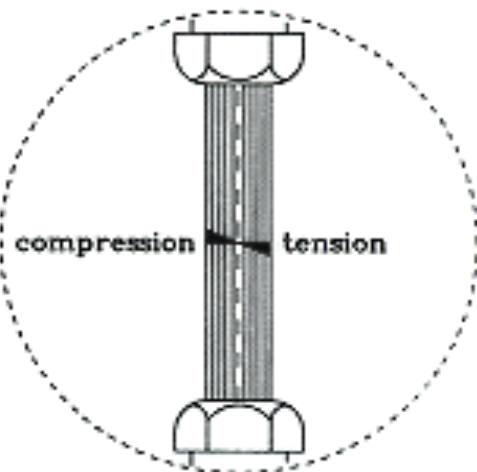
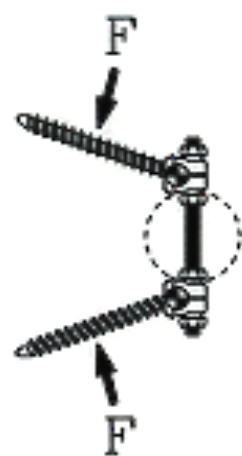

# Οπίσθια κολώνα

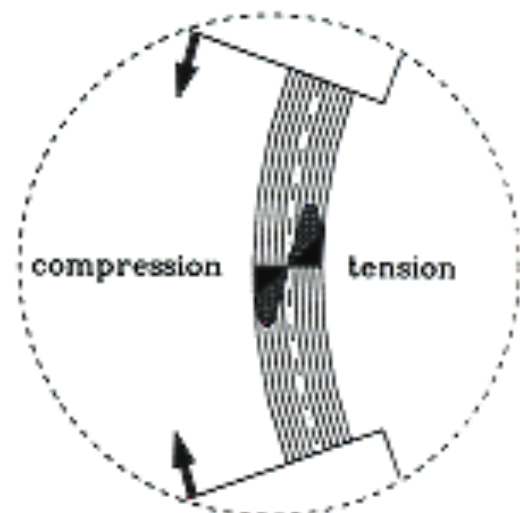
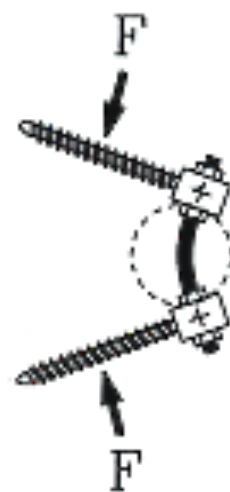



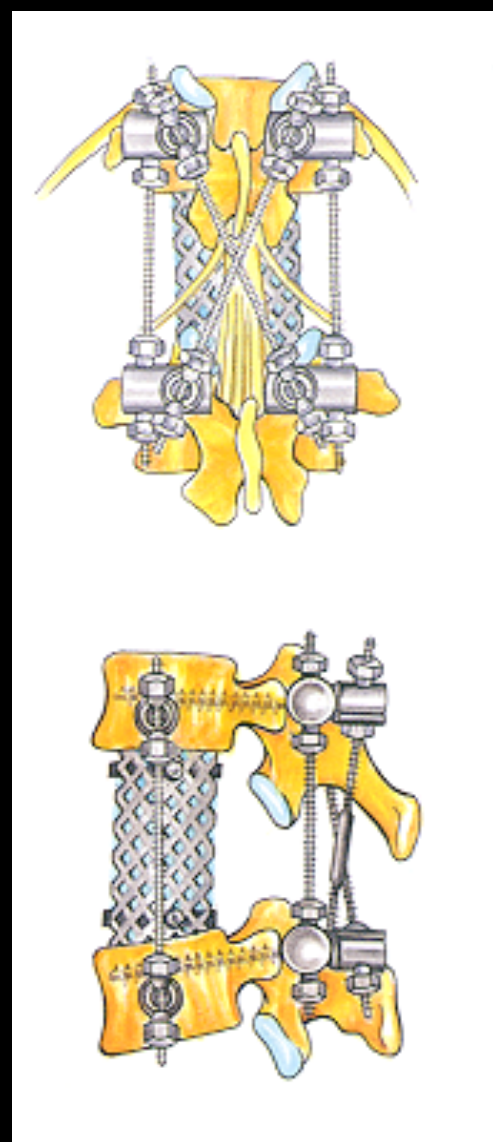
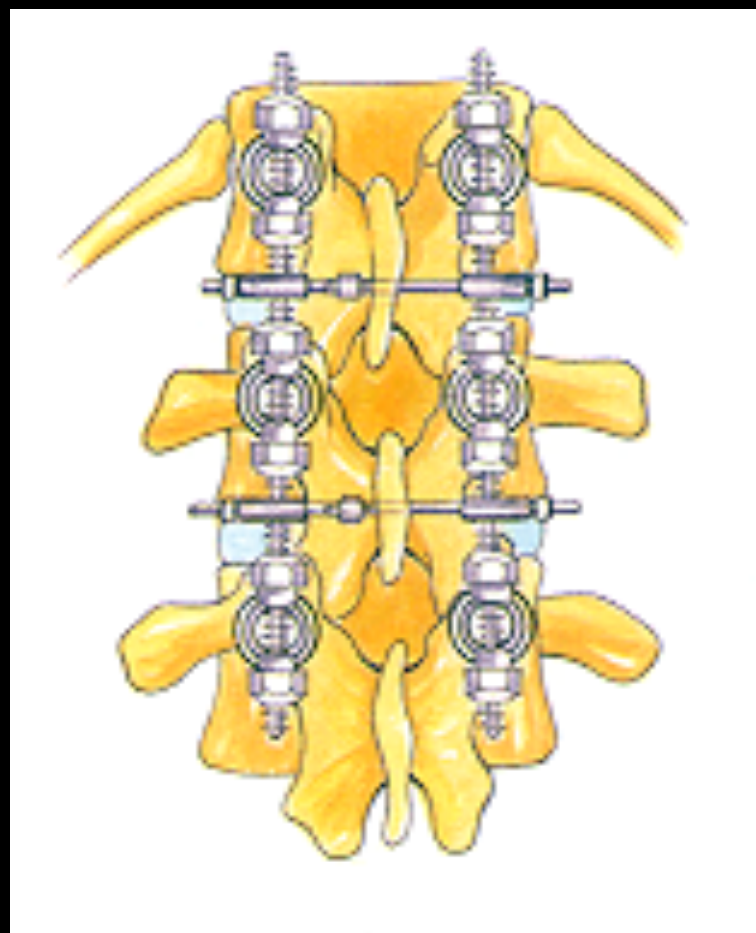




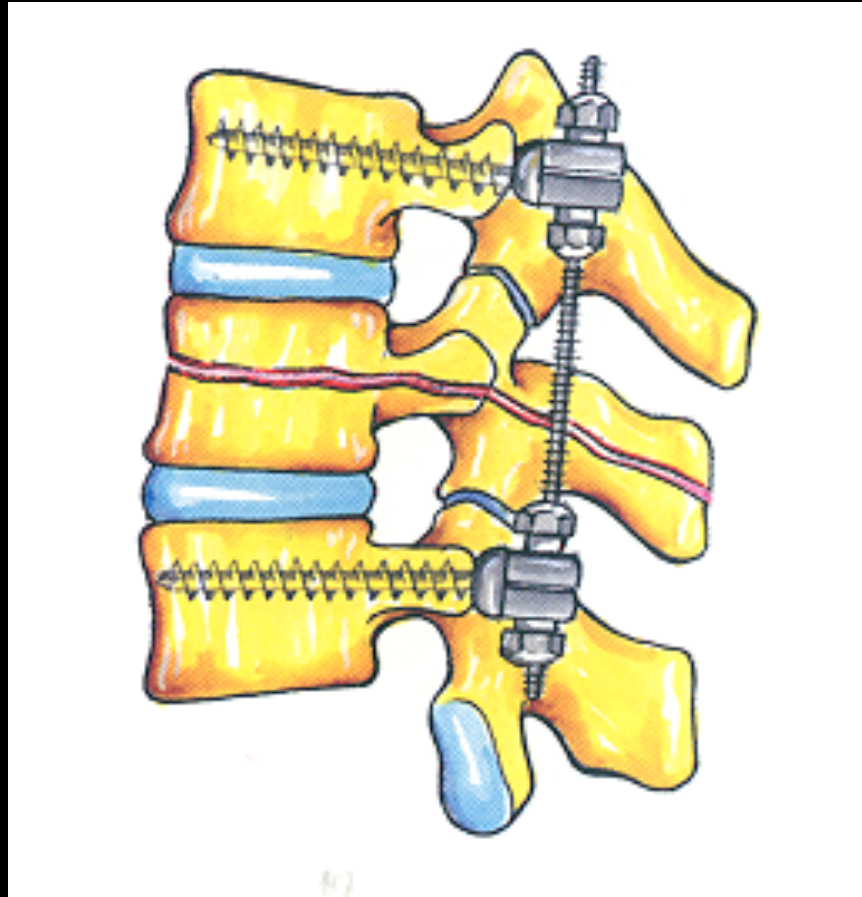
Bending moment  $N = X$



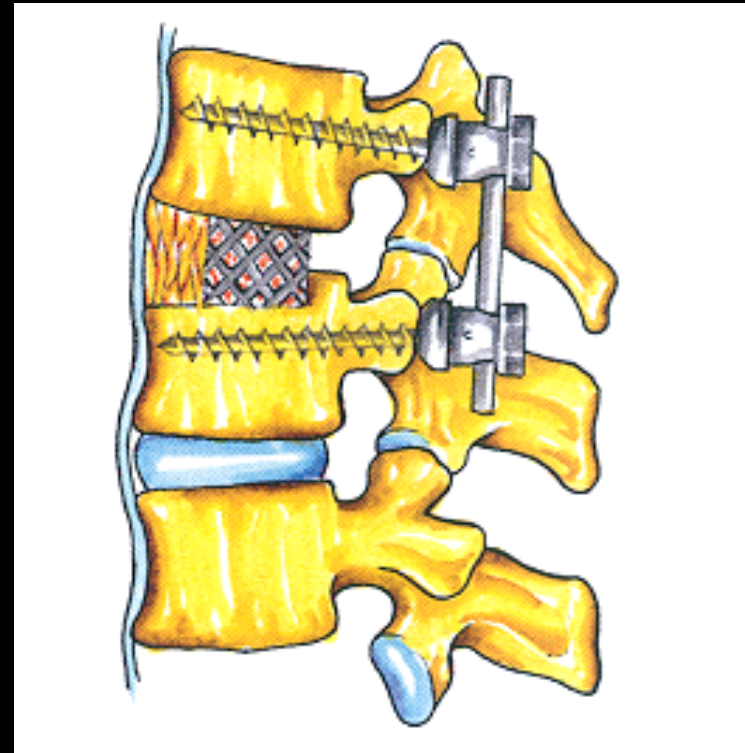
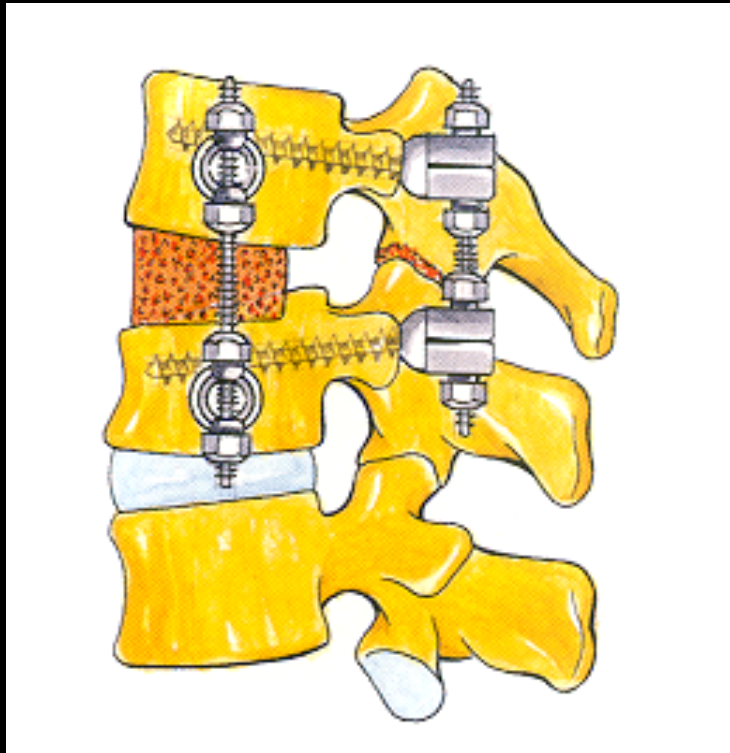
Bending moment  $N = X \times 8$



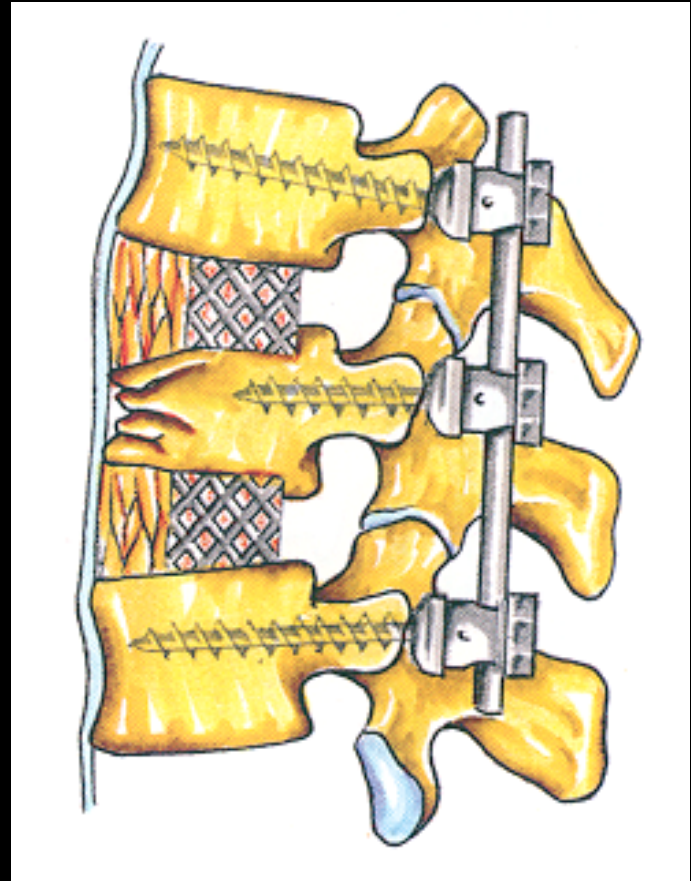
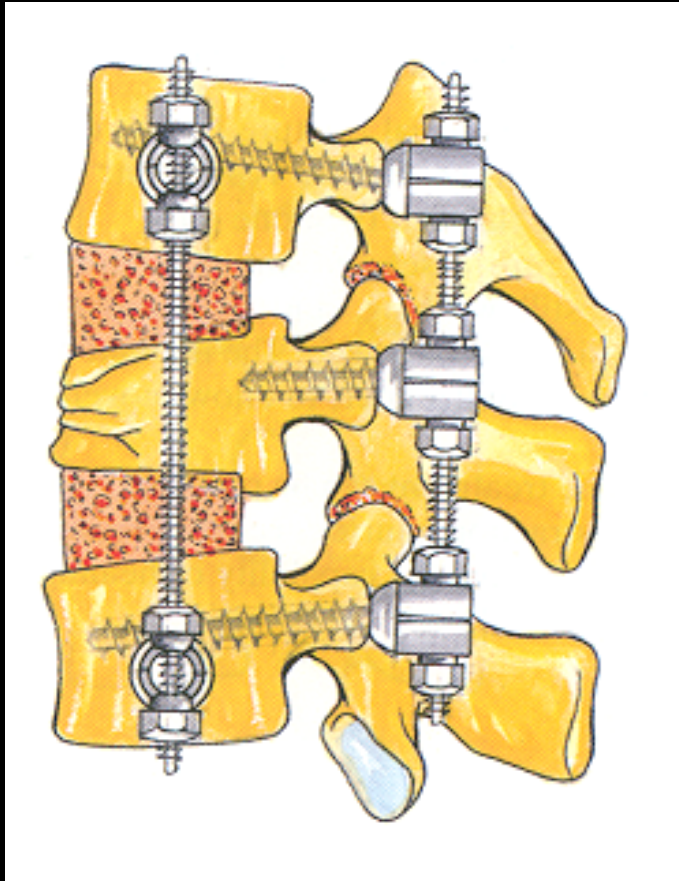
# Αριθμός σπονδυλοδεμένων επιπέδων : 0



# Αριθμός σπονδυλοδεμένων επιπέδων : 1

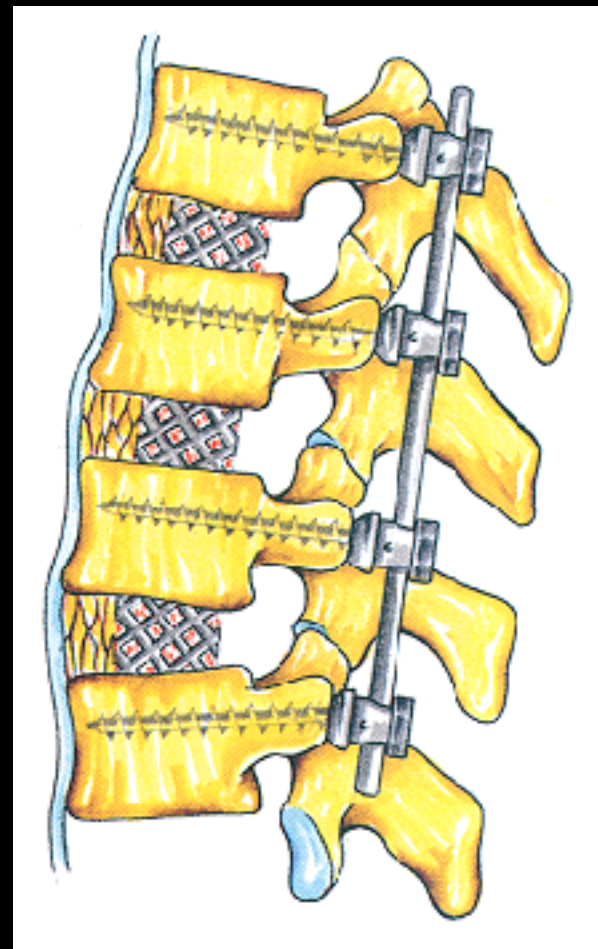
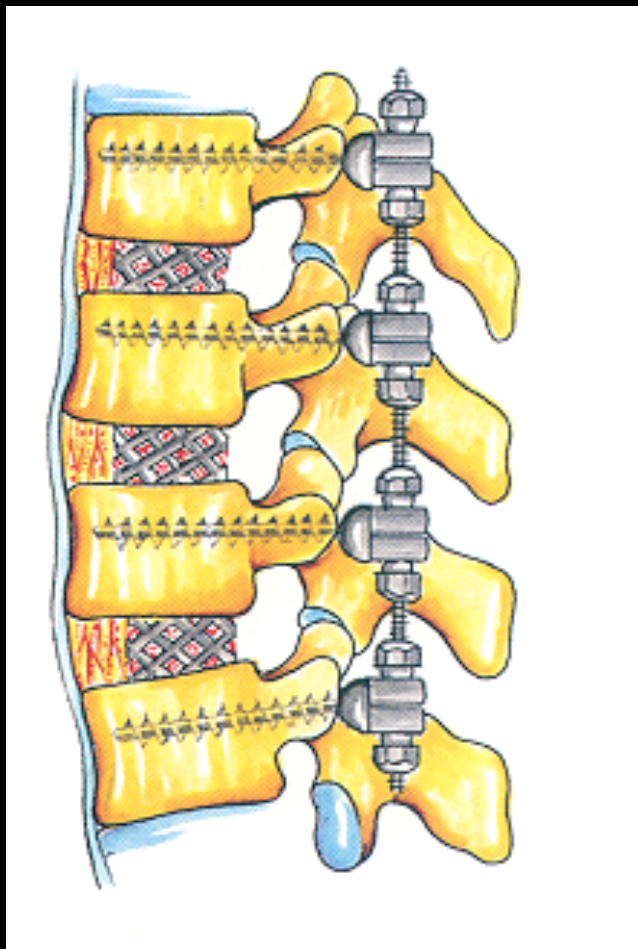


# Αριθμός σπονδυλοδεμένων επιπέδων : 2




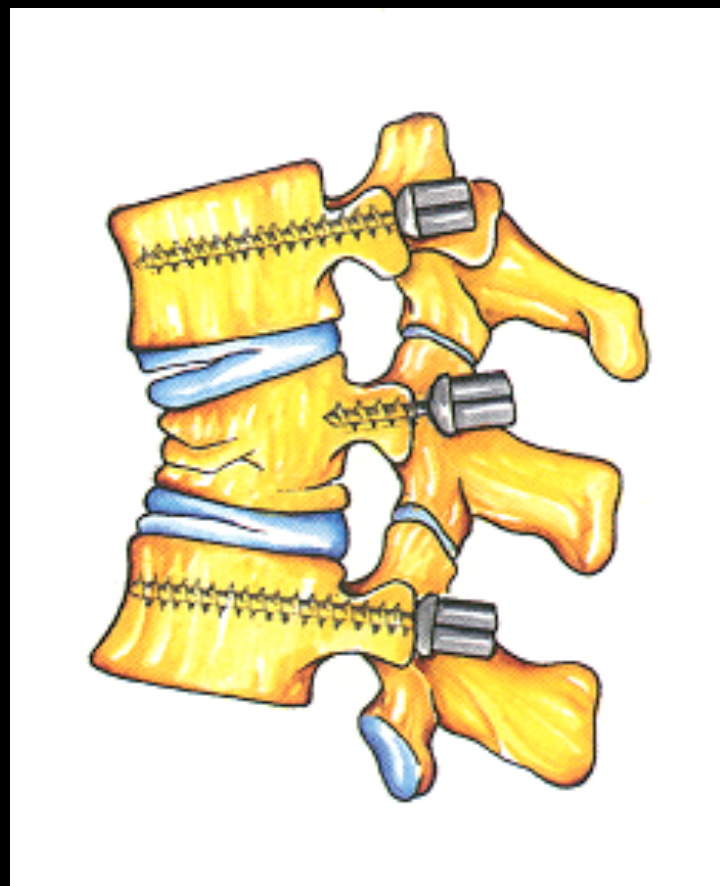
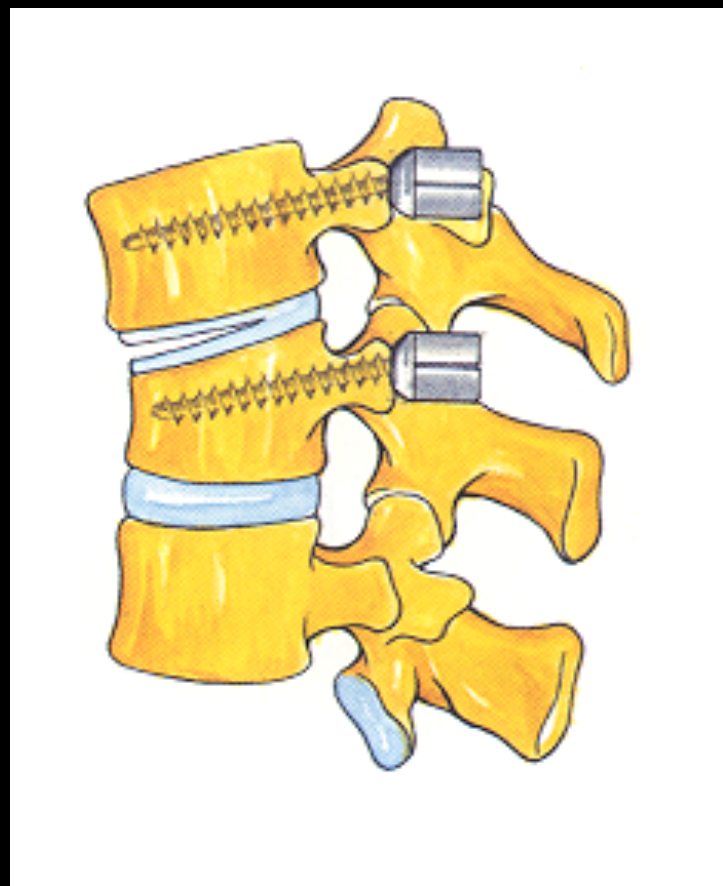


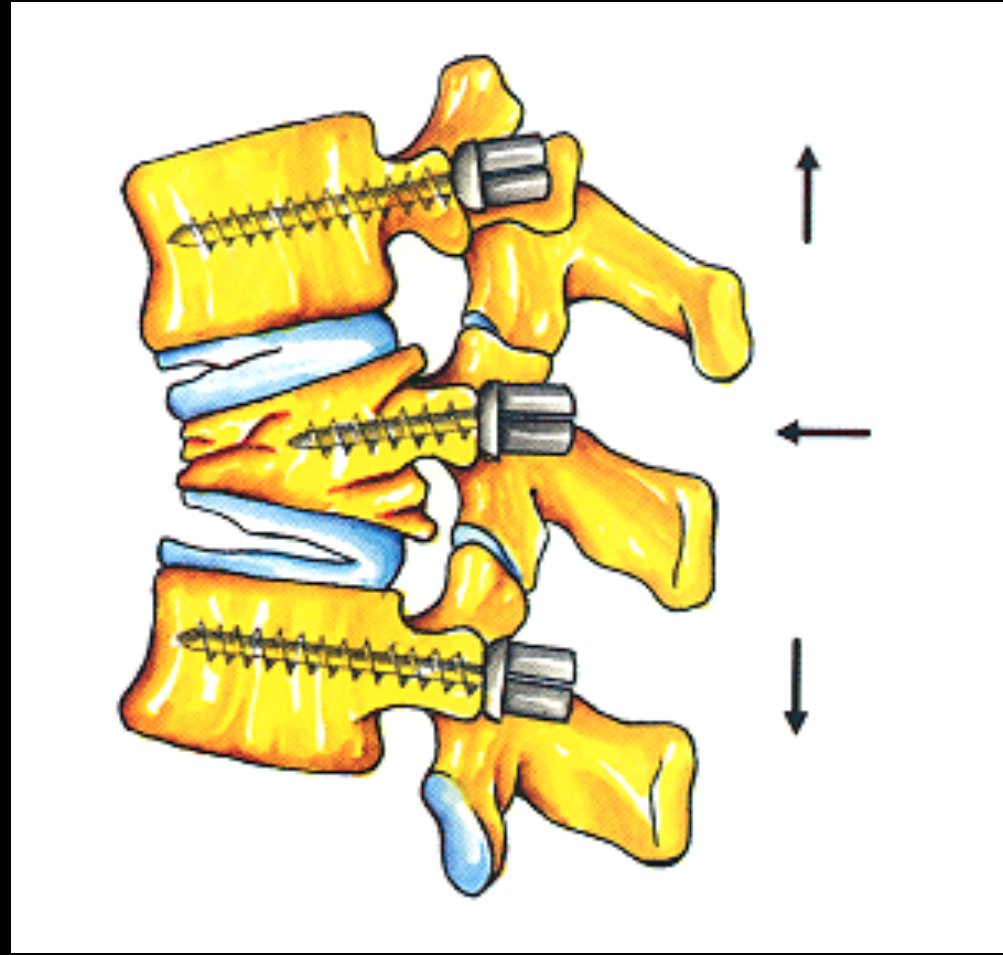
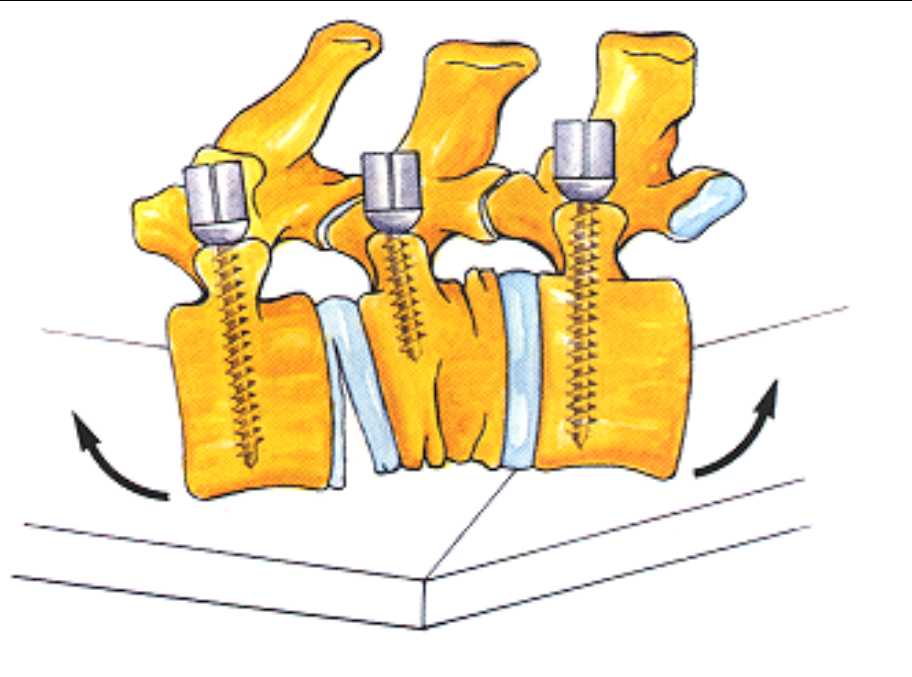
Αριθμός σπονδυλοδεμένων  
επιπέδων : 3 ή περισσότερα

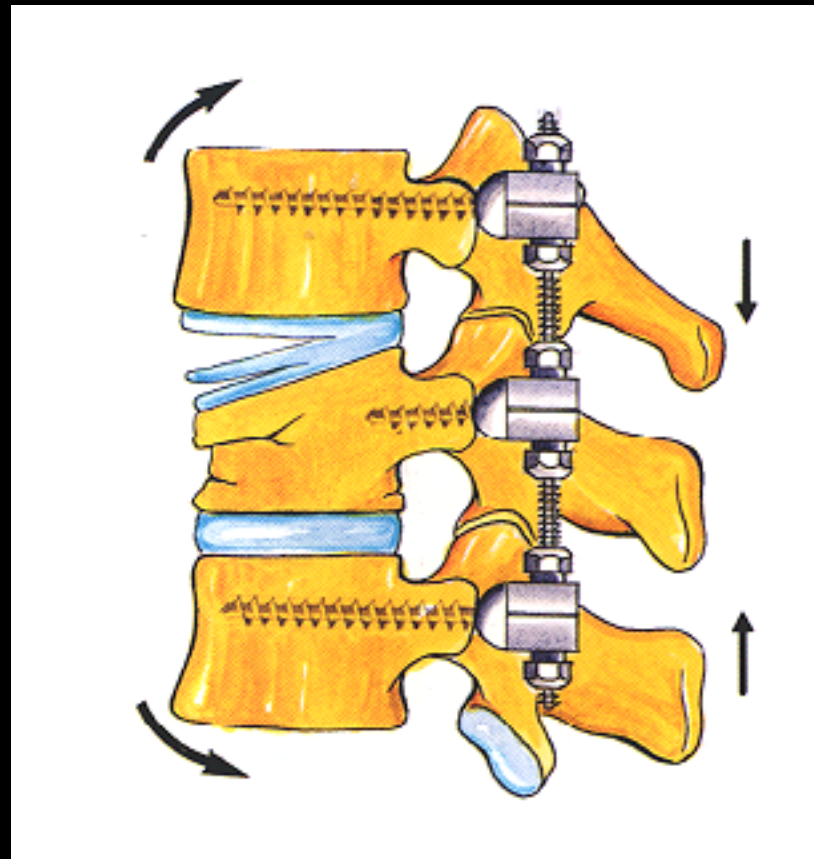
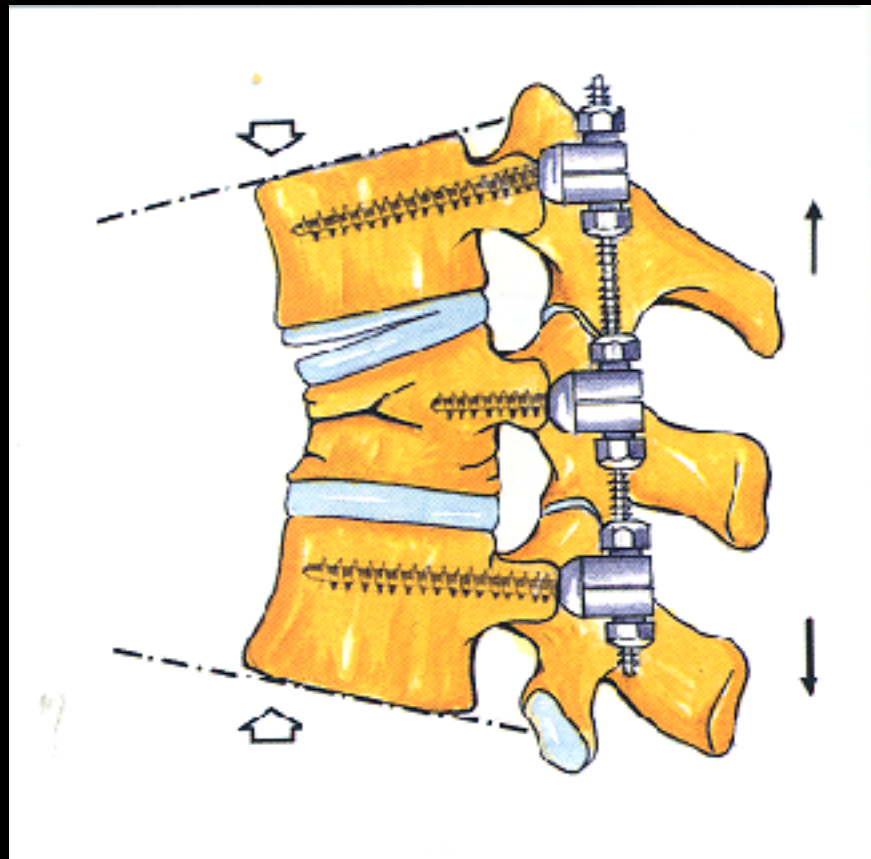


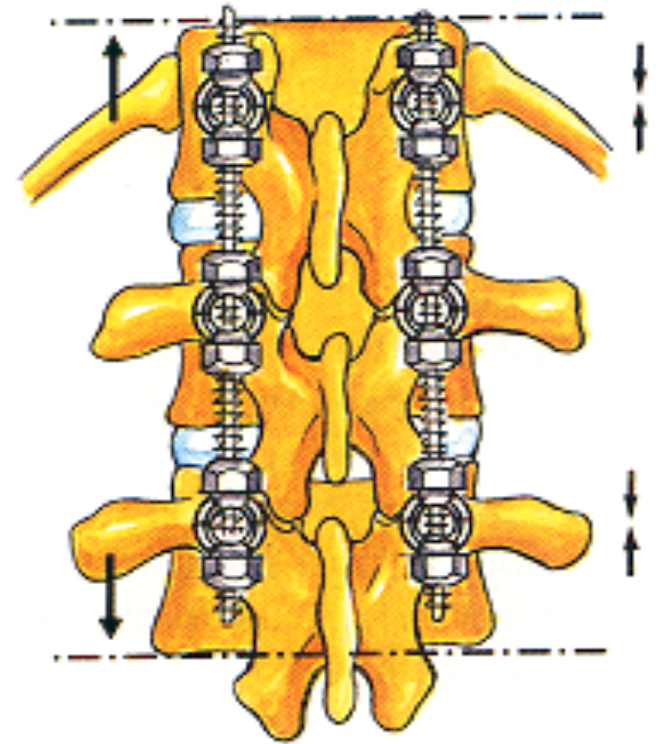
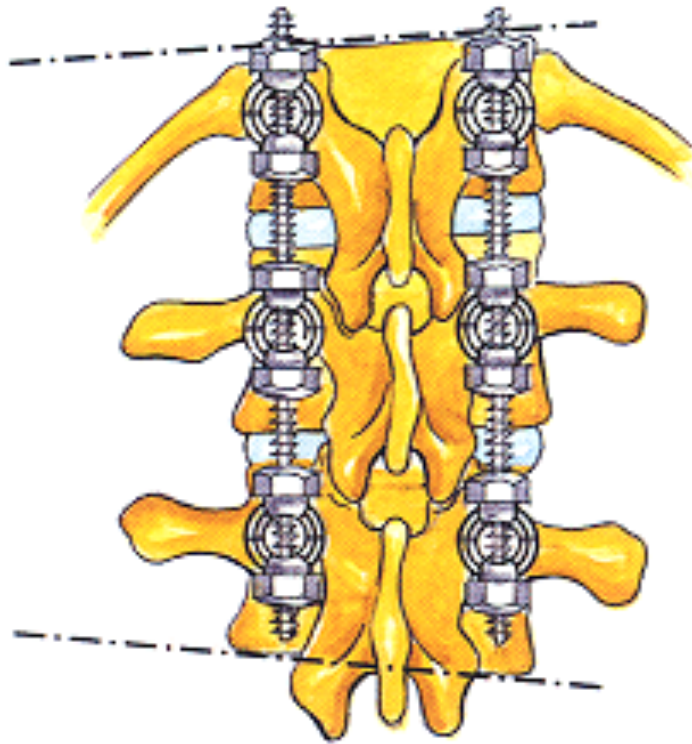
# Παραδείγματα



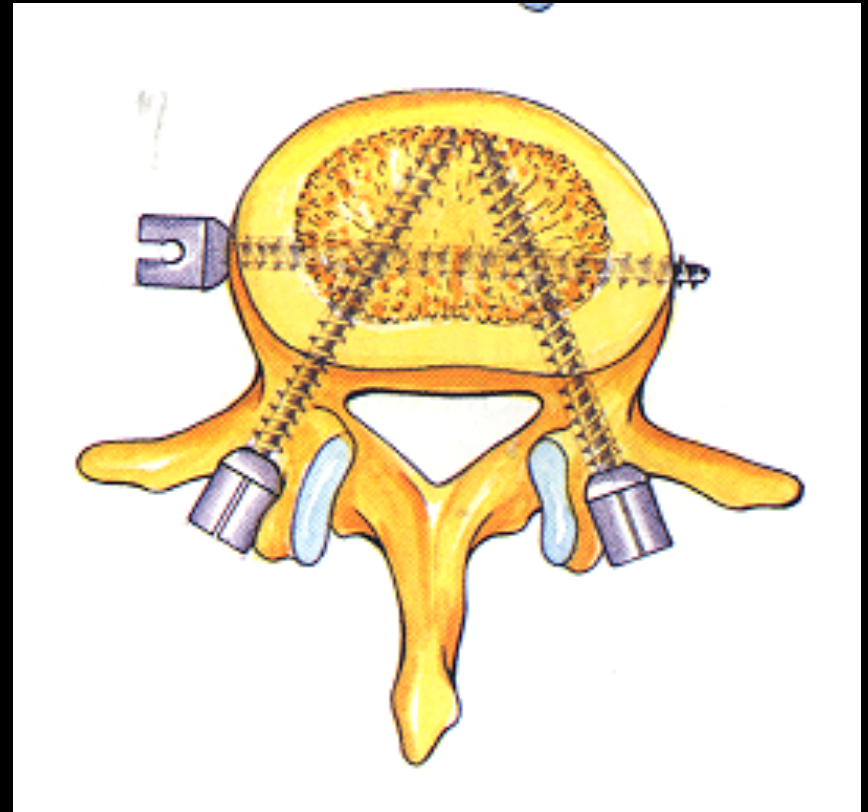
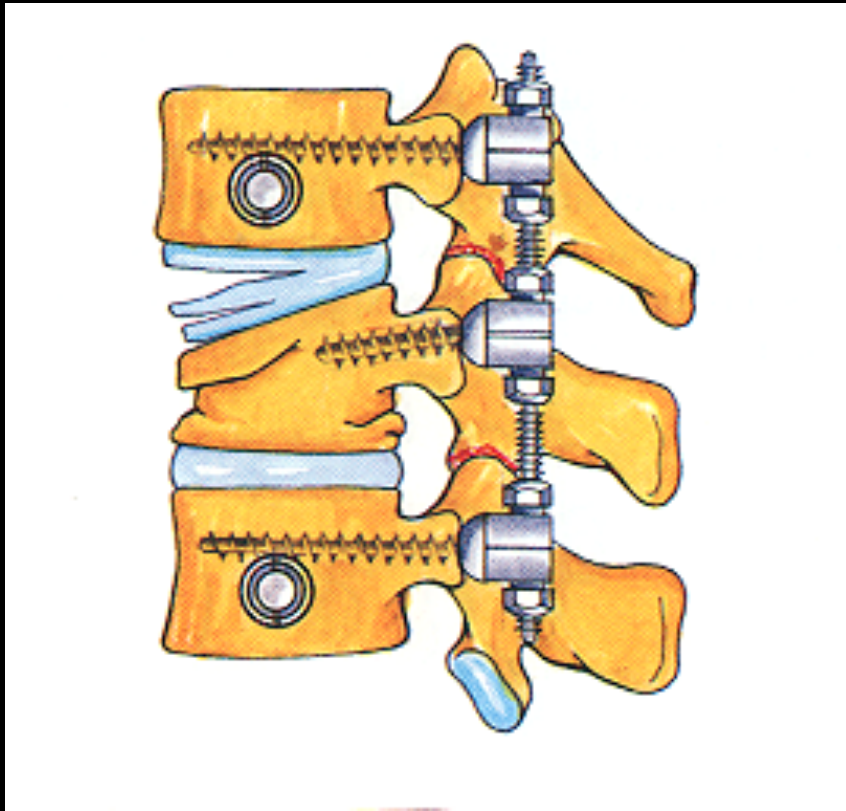


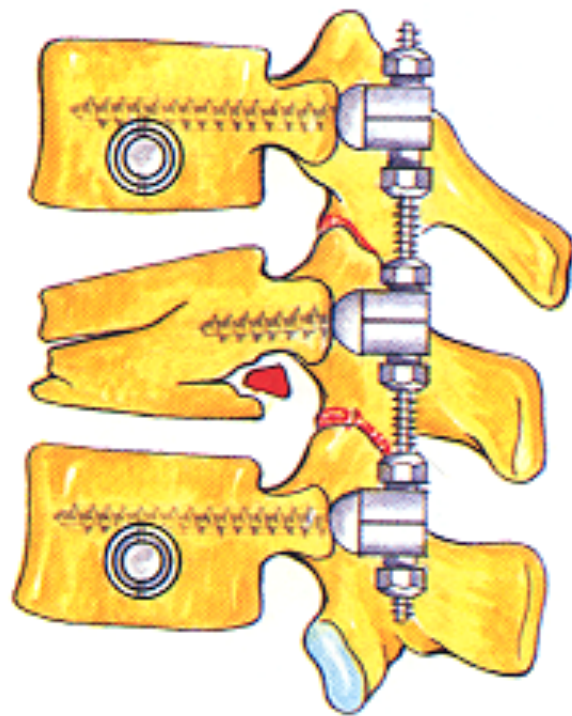
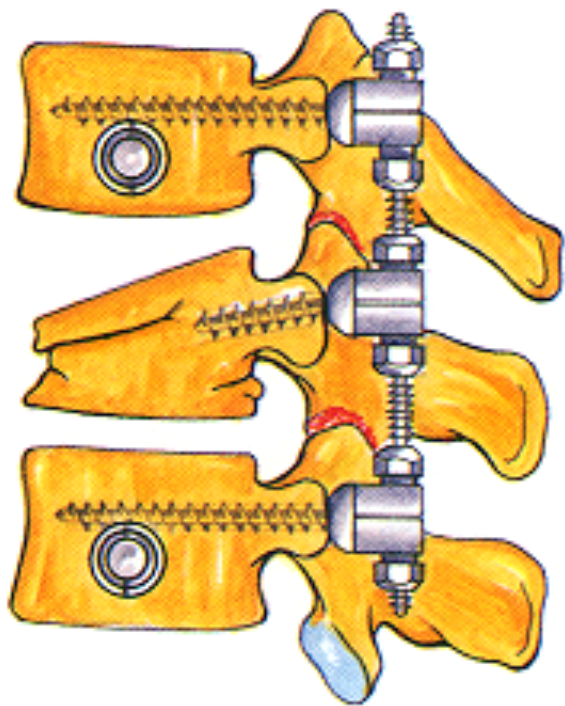




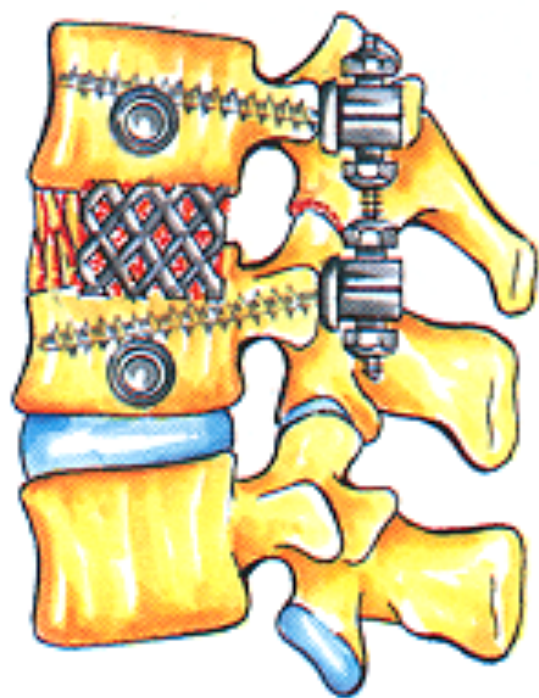
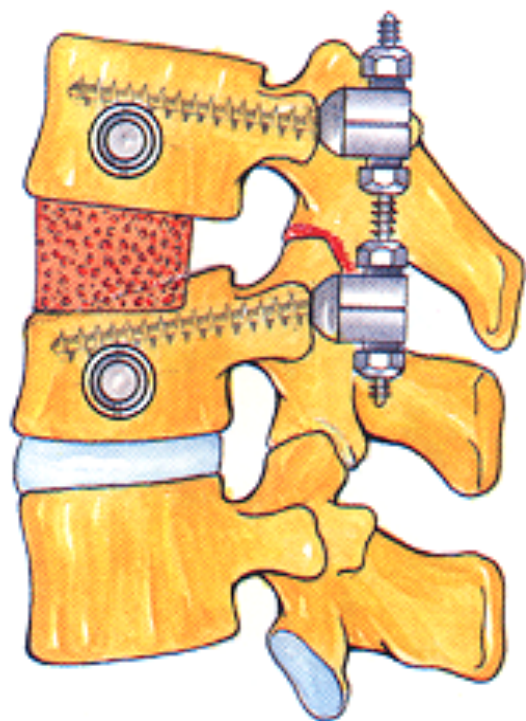


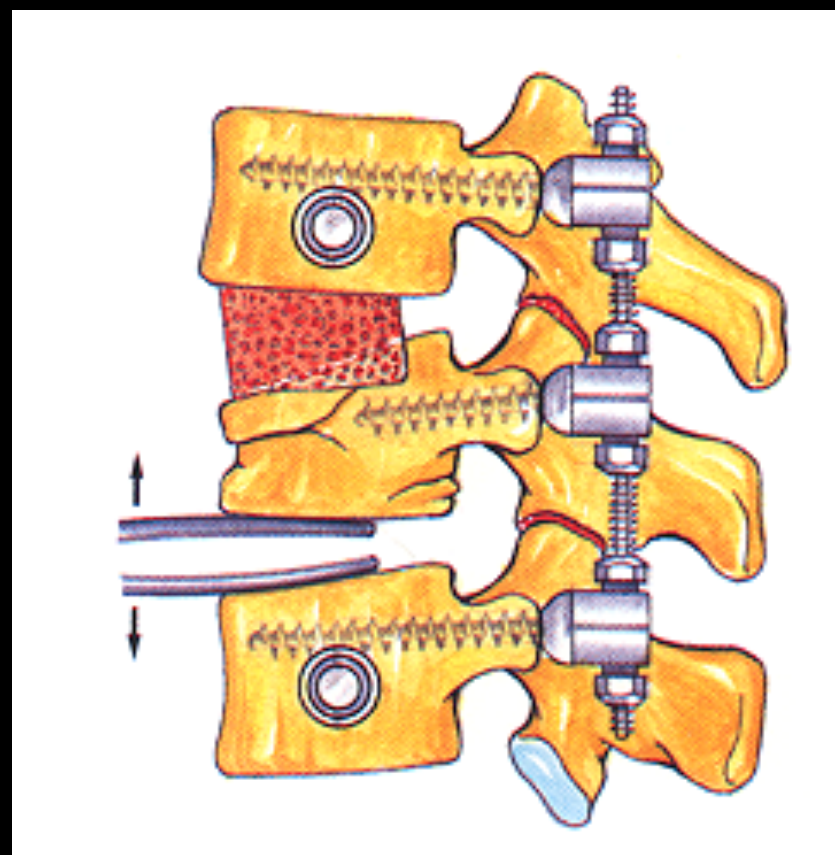
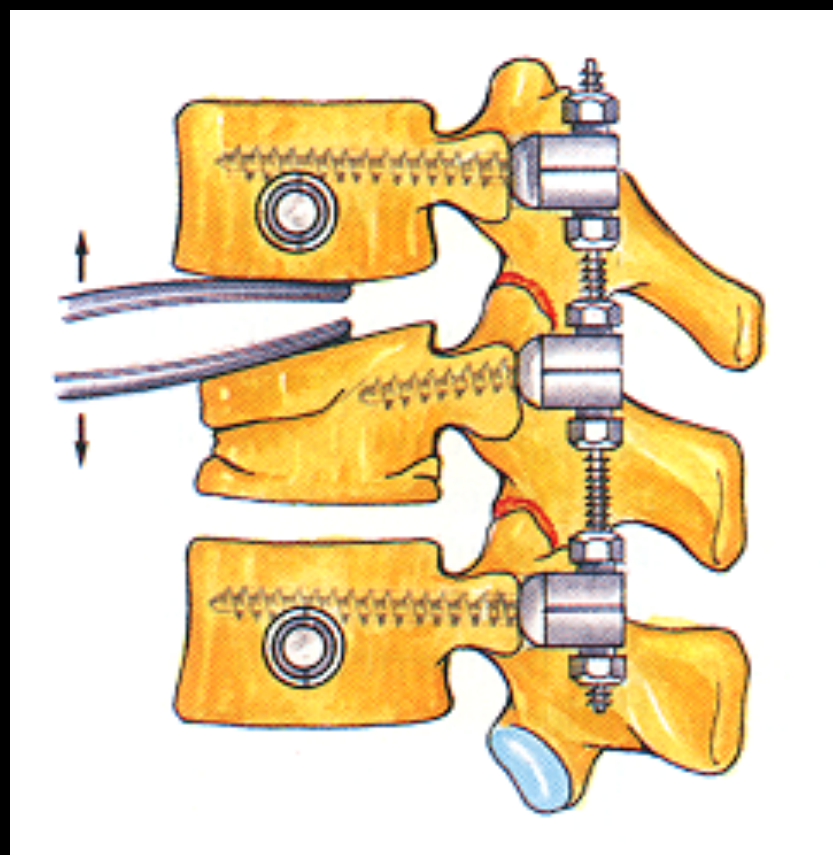
# Πρόσθια προσπέλαση

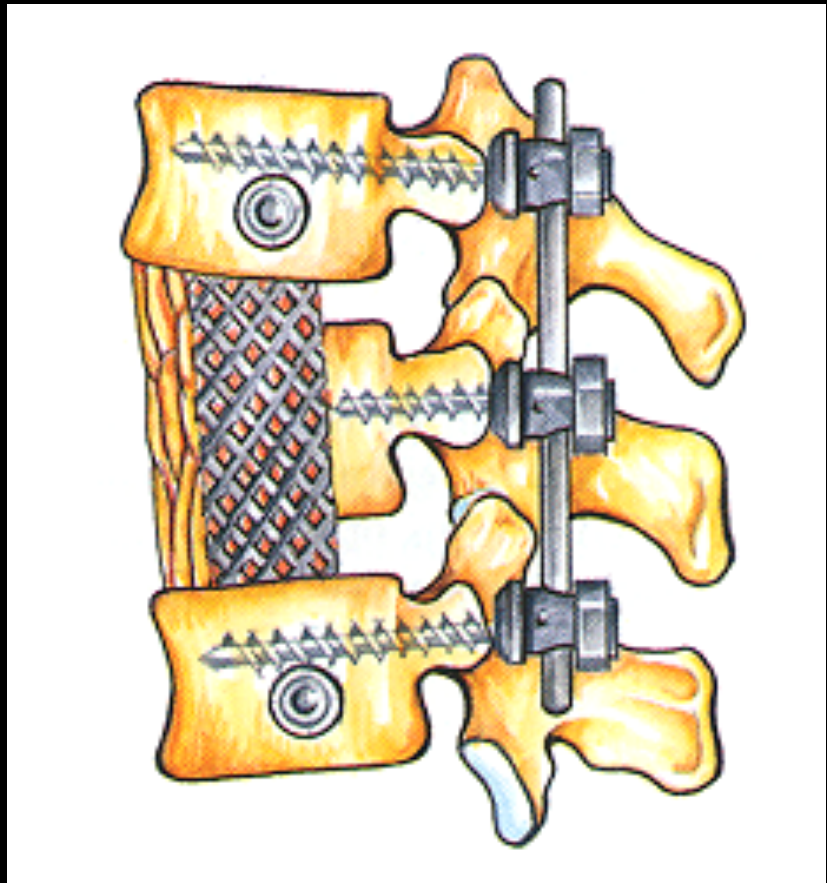
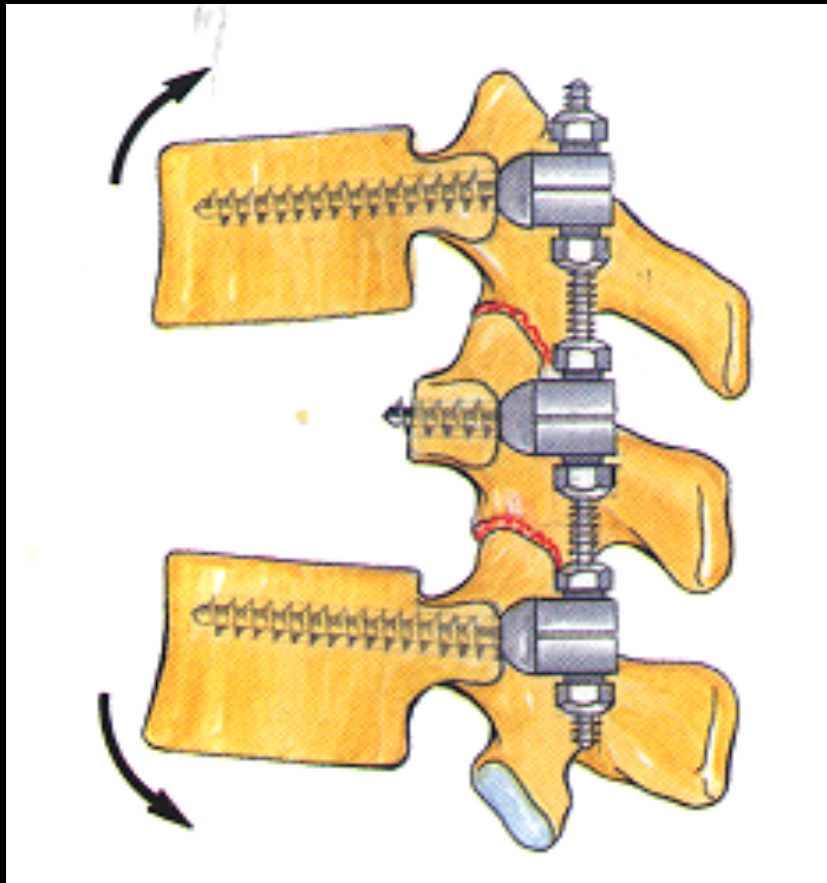


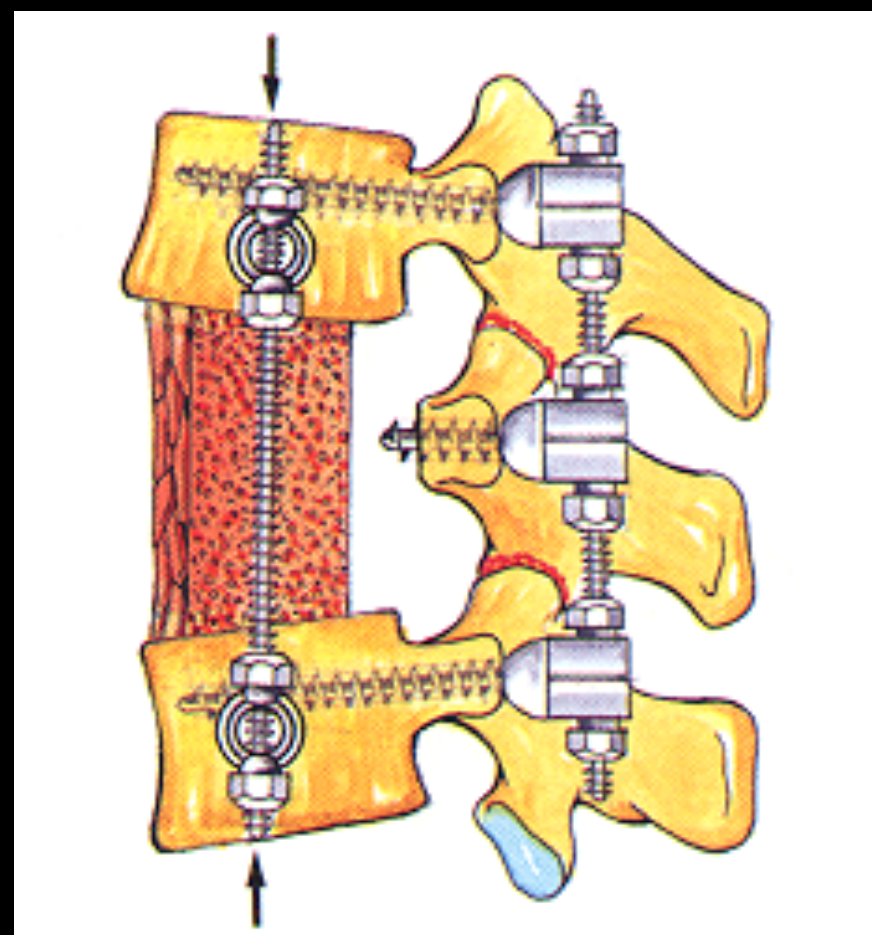
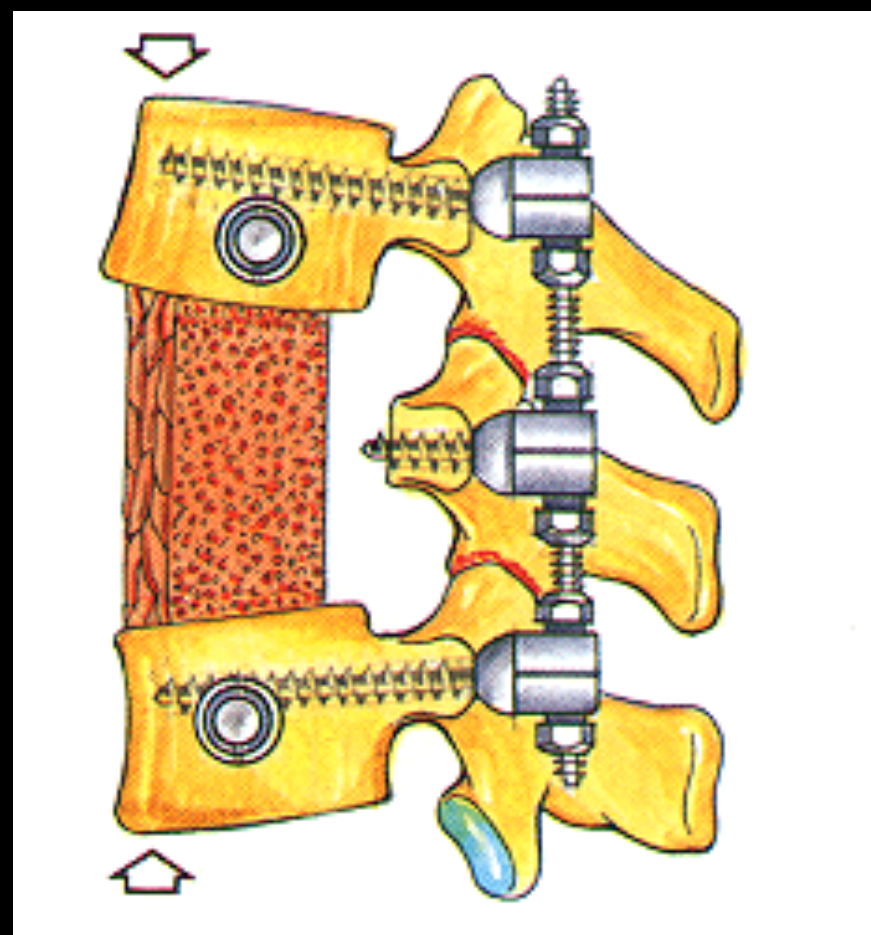




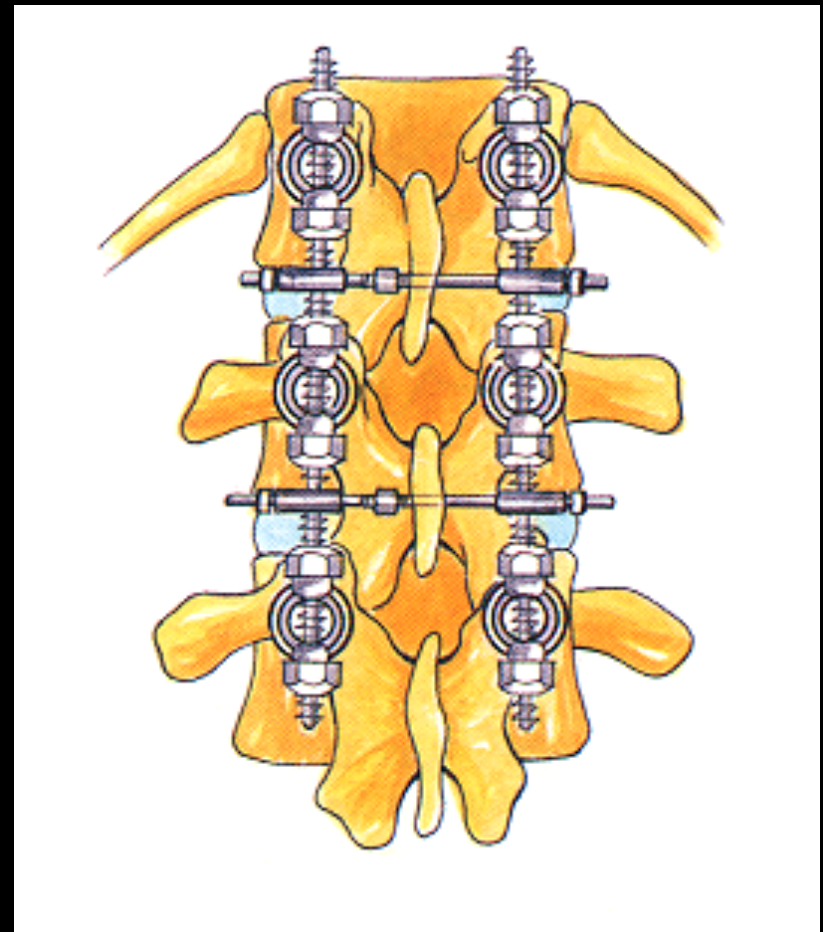
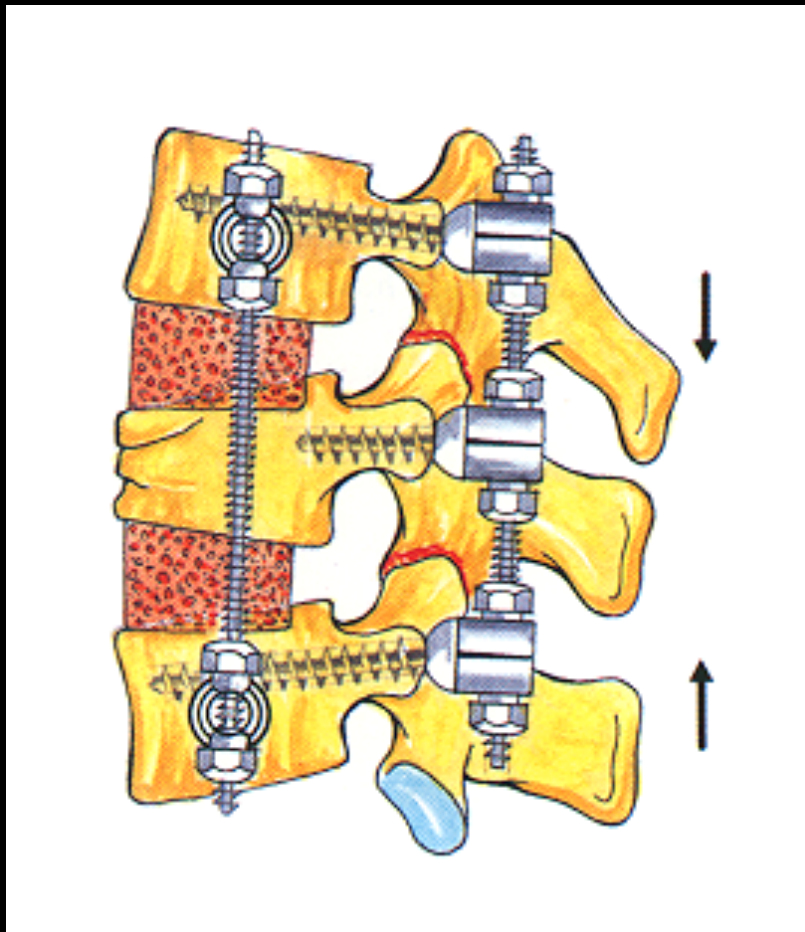


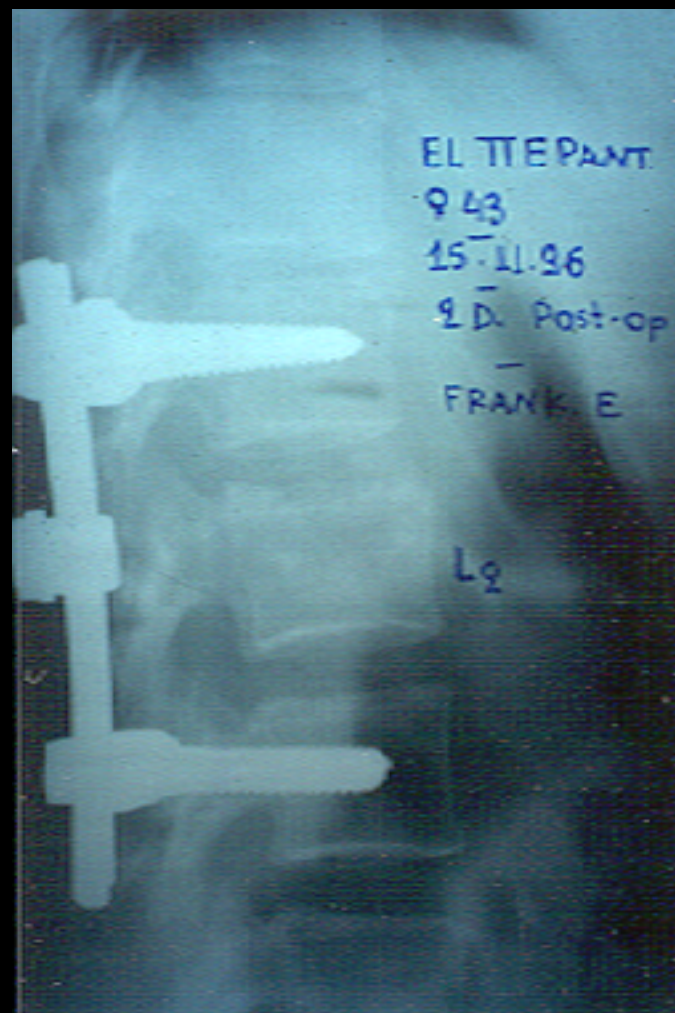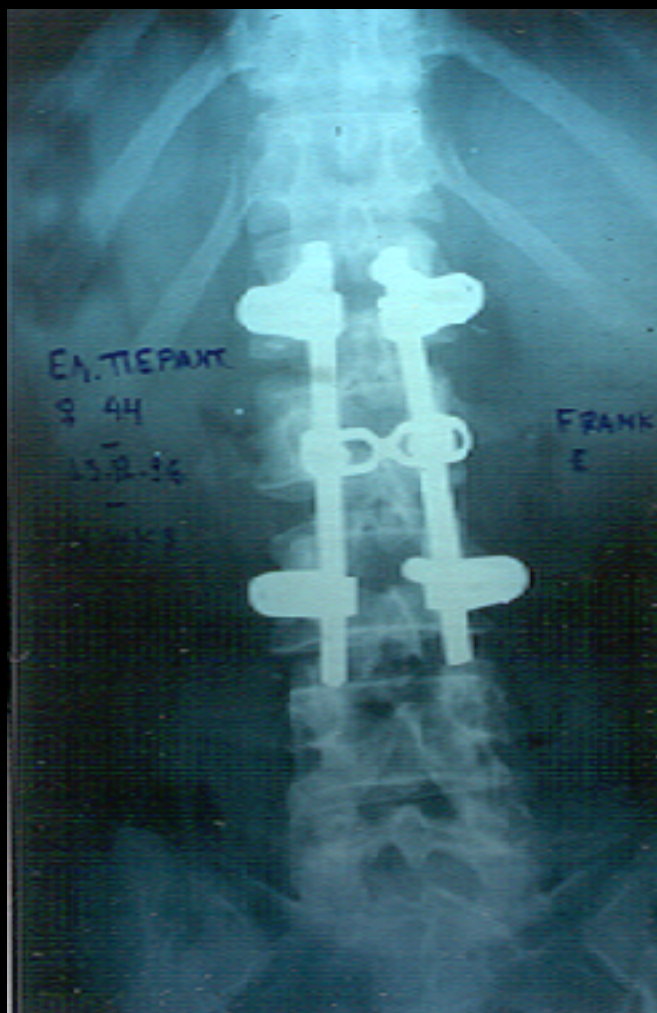


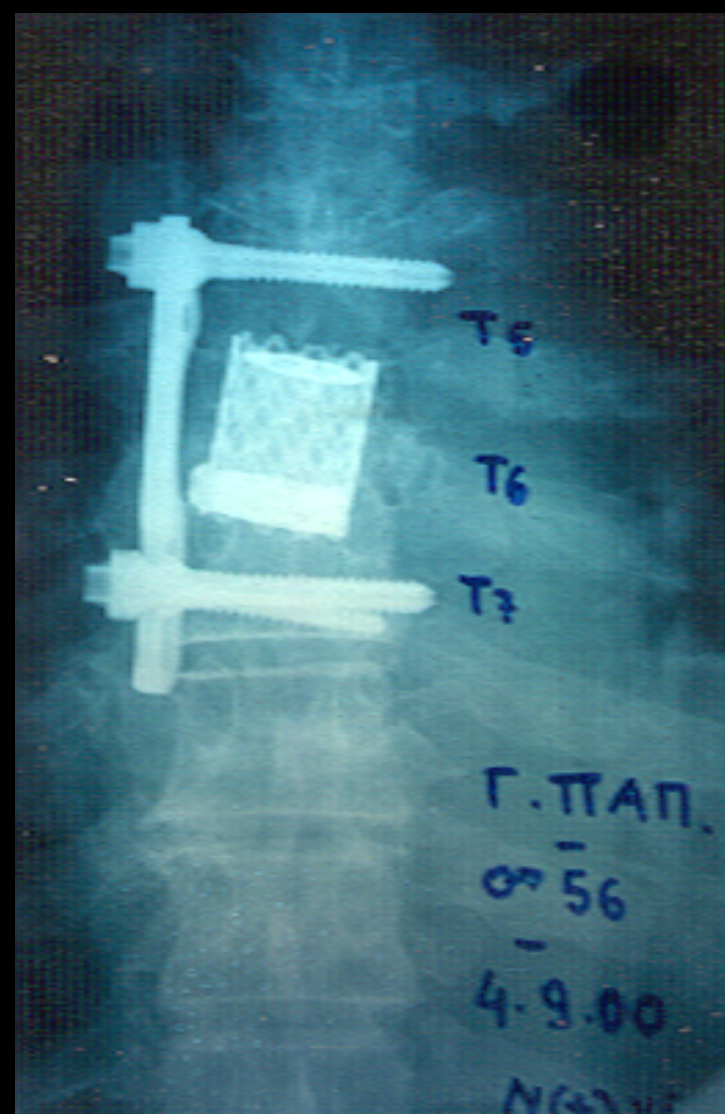
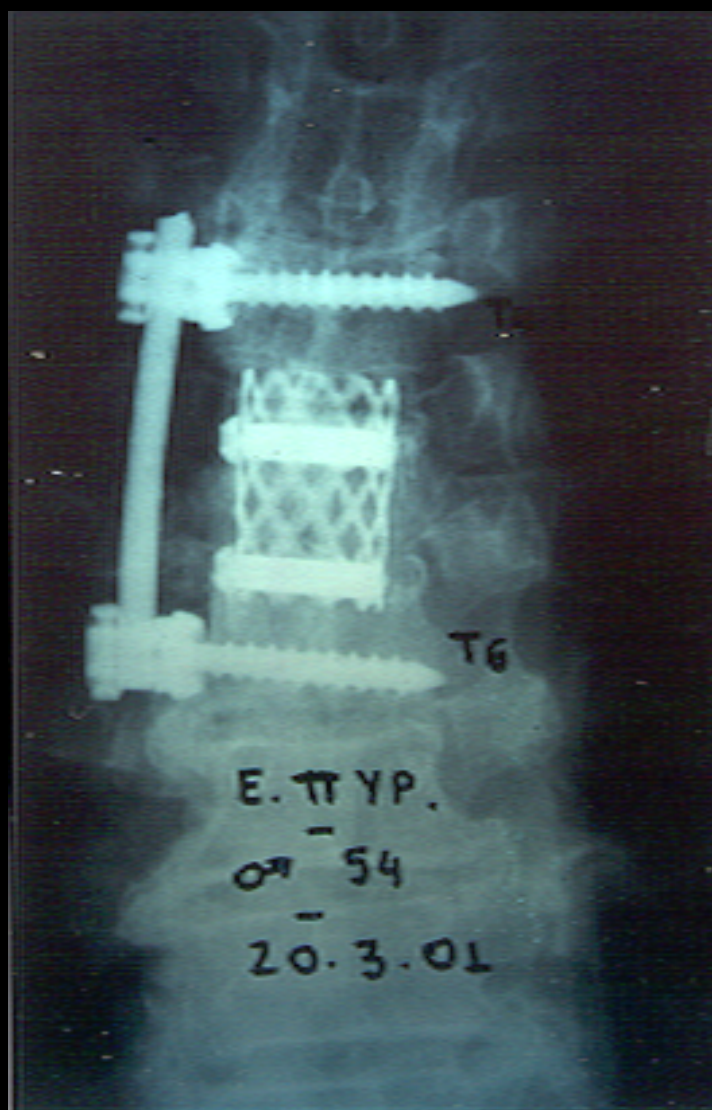




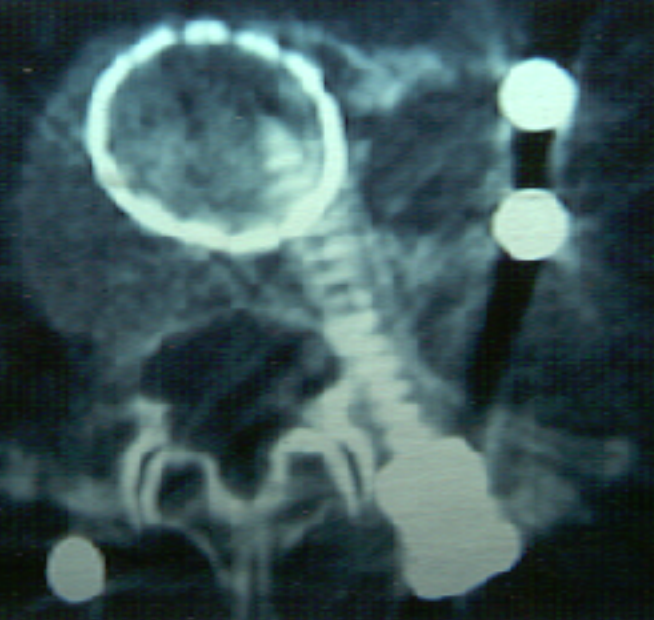
# Οπίσθια προσπέλαση



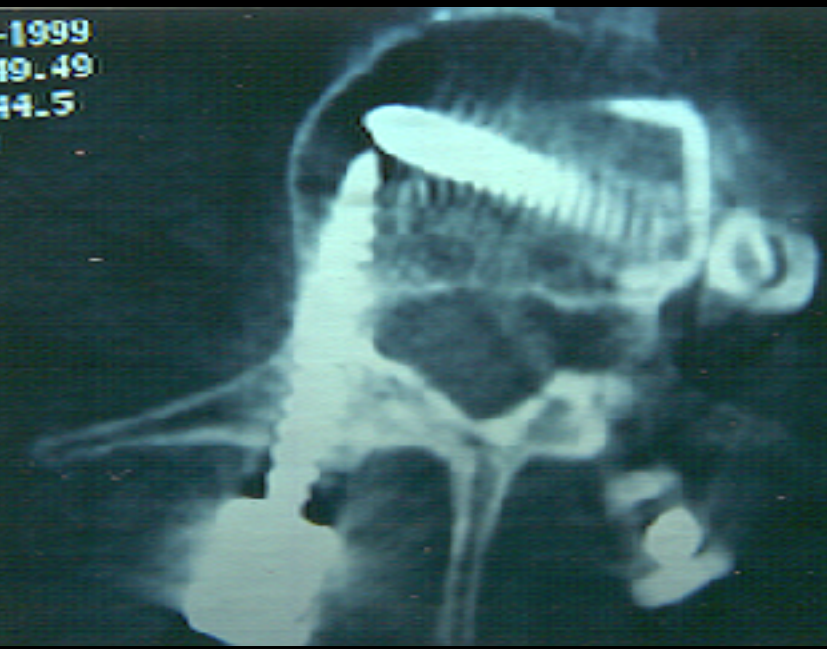




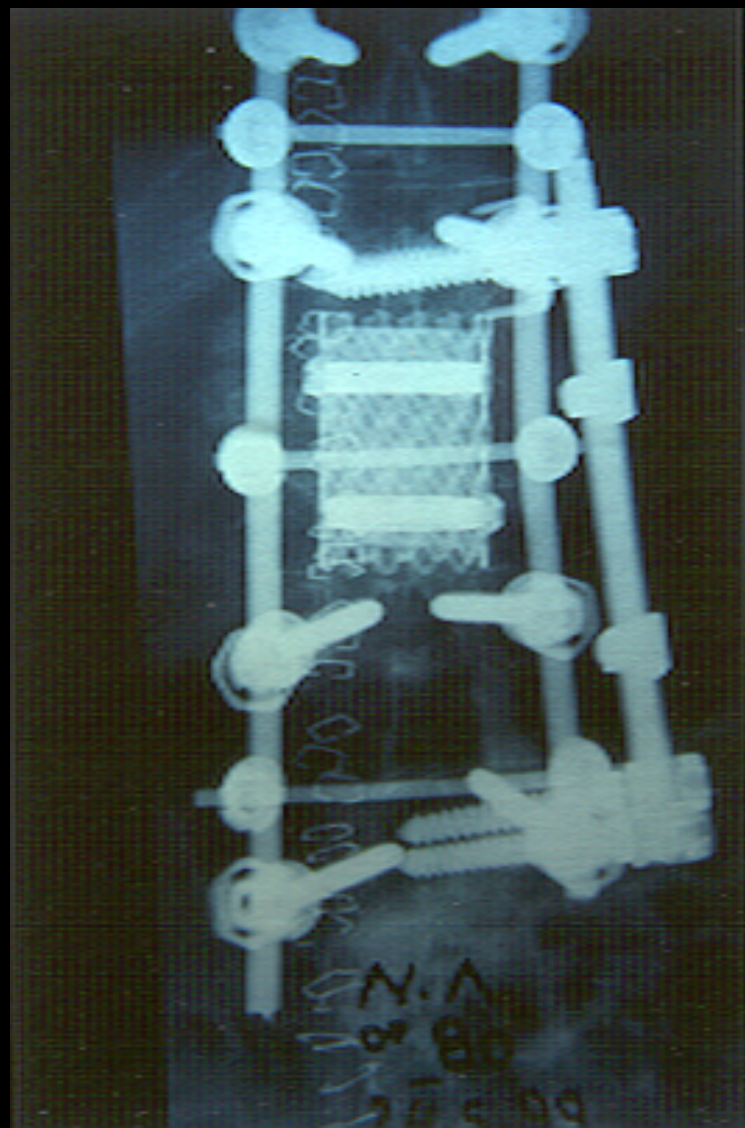
7-00-40-04  
P -1294.5  
MA 79  
PI 5



AY-1999  
0:49.49  
1344.5  
89  
5







# ΚΑΤΑΓΜΑΤΑ ΙΕΡΟΥ ΟΣΤΟΥ

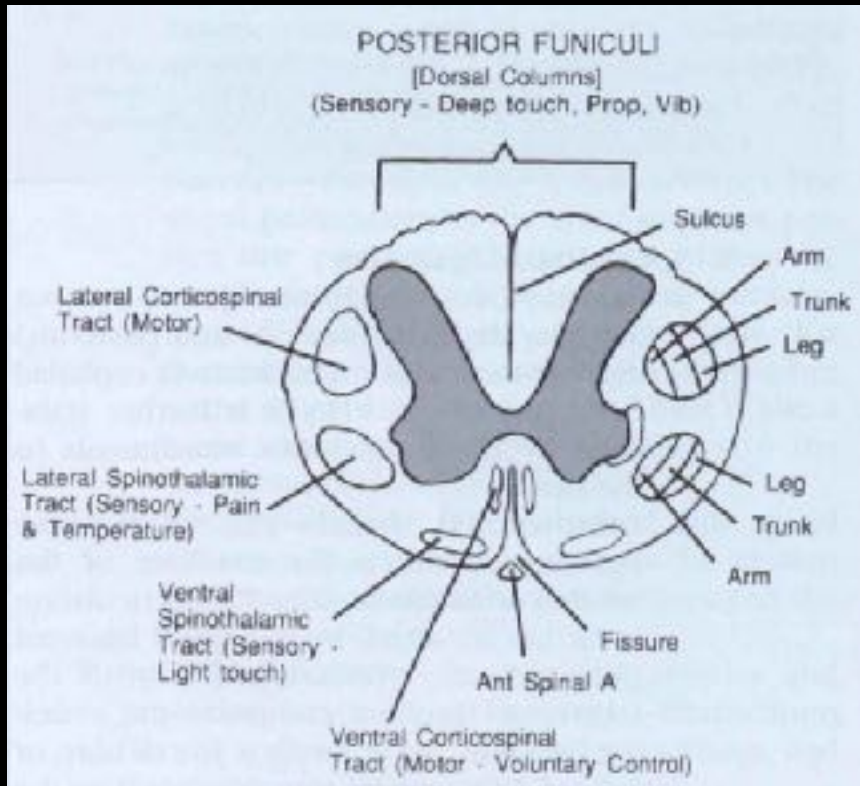
Table 142.2. Sacral Fracture Patterns

Fracture type	Description	Stability	Nerve injury (%)	Treatment
1	SI joint avulsion	Often highly unstable	21	Unstable—ORIF SI joint
2	Alar fracture	Stable if impacted	10	Protected weight bearing
3	Transforaminal	Unstable if displaced	17	Closed reduction, percutaneous SI screws
4	Transforaminal, extending into canal	Unstable if displaced	60	Closed reduction, percutaneous SI screws
5	Transverse	Highly unstable	50	Bed rest; decompression for neurologic deficit
6	Bilateral transforaminal	Highly unstable	60	Bed rest; decompression for neurologic deficit

ORIF, open reduction and internal fixation.



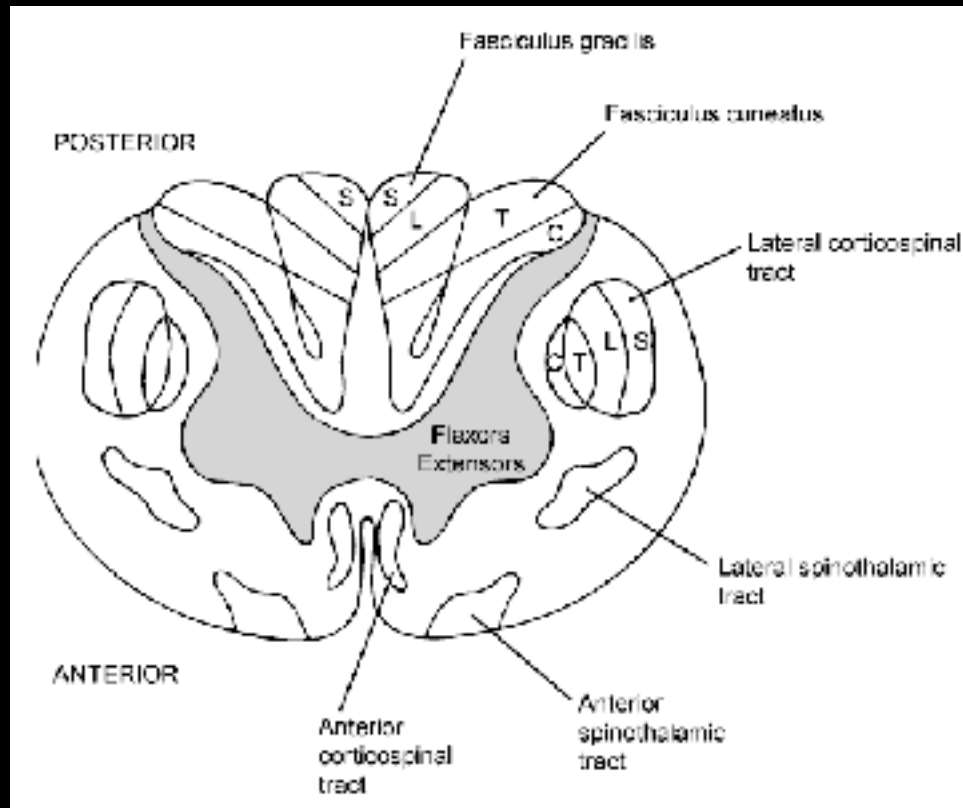
# ANATOMIA ΝΩΤΙΑΙΟΥ ΜΥΕΛΟΥ

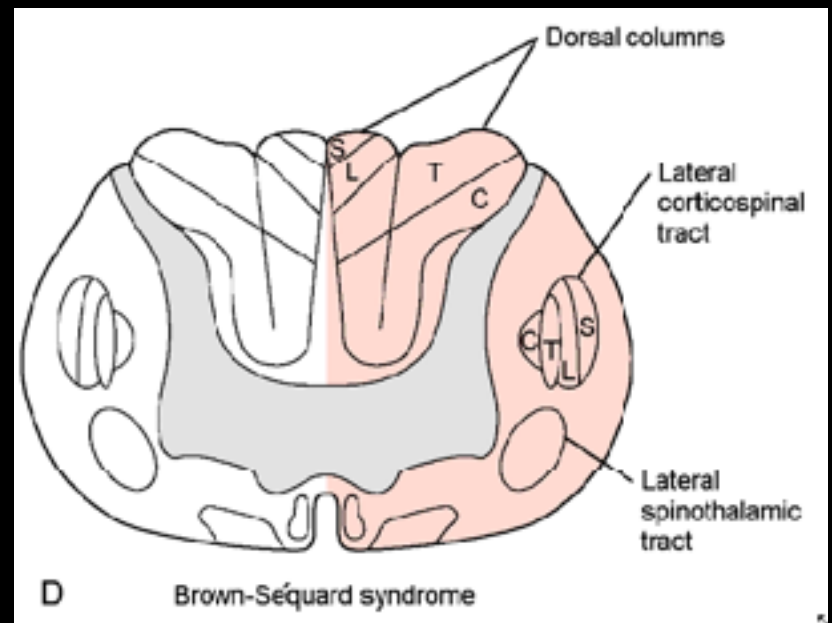
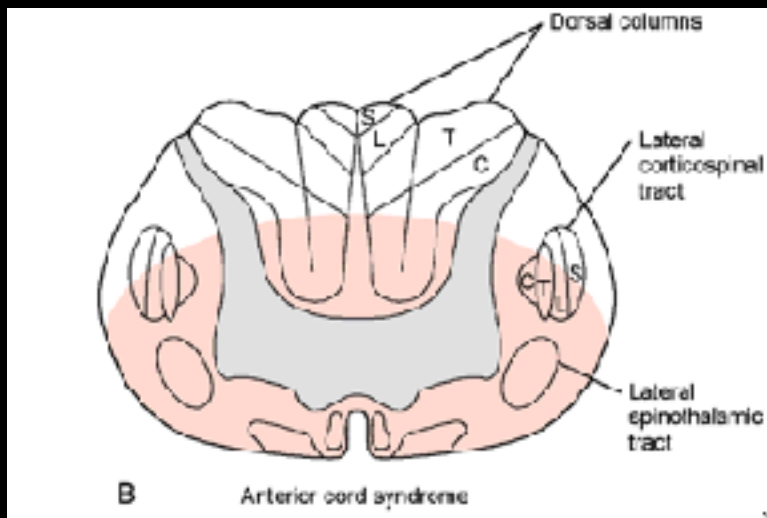
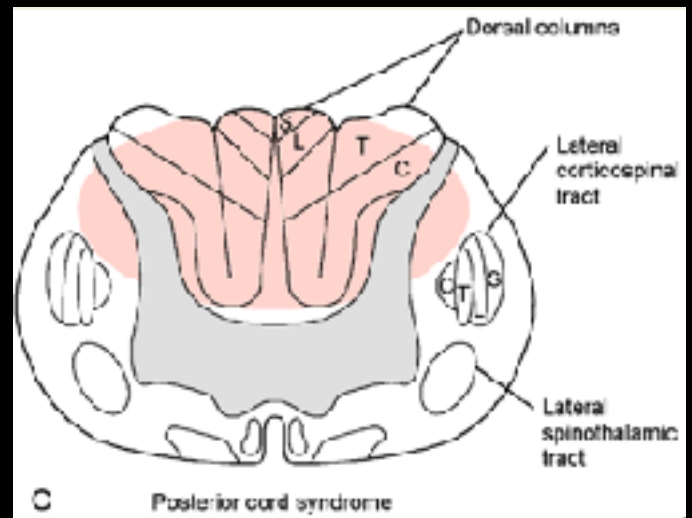
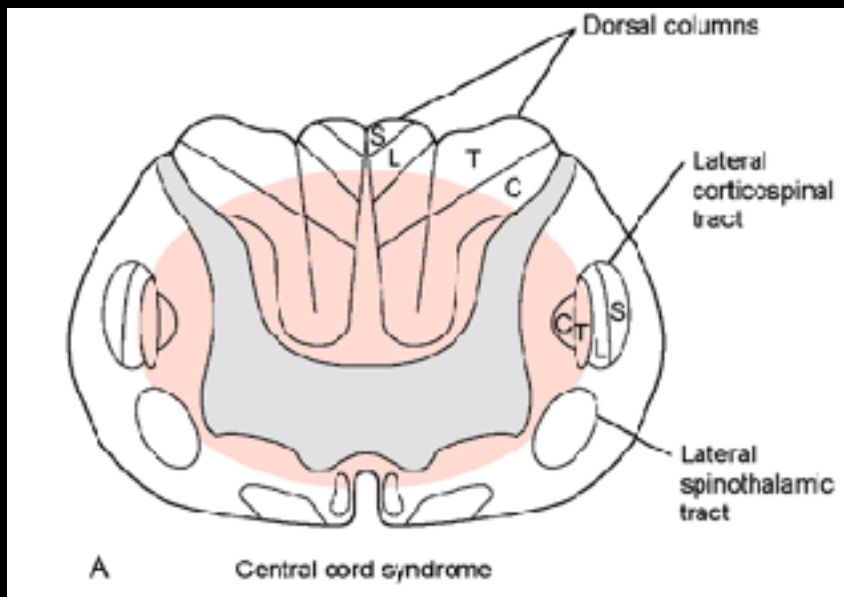


## SPINAL CORD TRACTS

	TRACTS	FUNCTION
<b>Ascending (sensory)</b>	Dorsal columns	Deep touch, proprioception, vibratory
	Lateral spinothalamic	Pain and temperature
	Anterior spinothalamic	Light touch
<b>Descending (motor)</b>	Lateral corticospinal	Voluntary motor
	Anterior corticospinal	Voluntary motor

# ANATOMIA ΝΩΤΙΑΙΟΥ ΜΥΕΛΟΥ





# ΤΡΑΥΜΑΤΙΣΜΟΣ ΝΩΤΙΑΙΟΥ ΜΥΕΛΟΥ

## INCOMPLETE SPINAL CORD INJURY PATTERNS

INJURY PATTERN	FUNCTIONAL DEFICIT	RECOVERY
Central ( <b>most common</b> )	UE>LE, usually quadriplegic with sacral sparing. Flaccid paralysis of UE and spastic paralysis of LE	75%
Anterior	Complete motor deficit	10% ( <b>worst prognosis</b> )
Posterior	Loss of deep pressure, deep pain and proprioception	
Brown-Séquard	Unilateral cord injury with ipsilateral motor deficit and contralateral pain and temperature deficit (two levels below injury)	>90% recovery

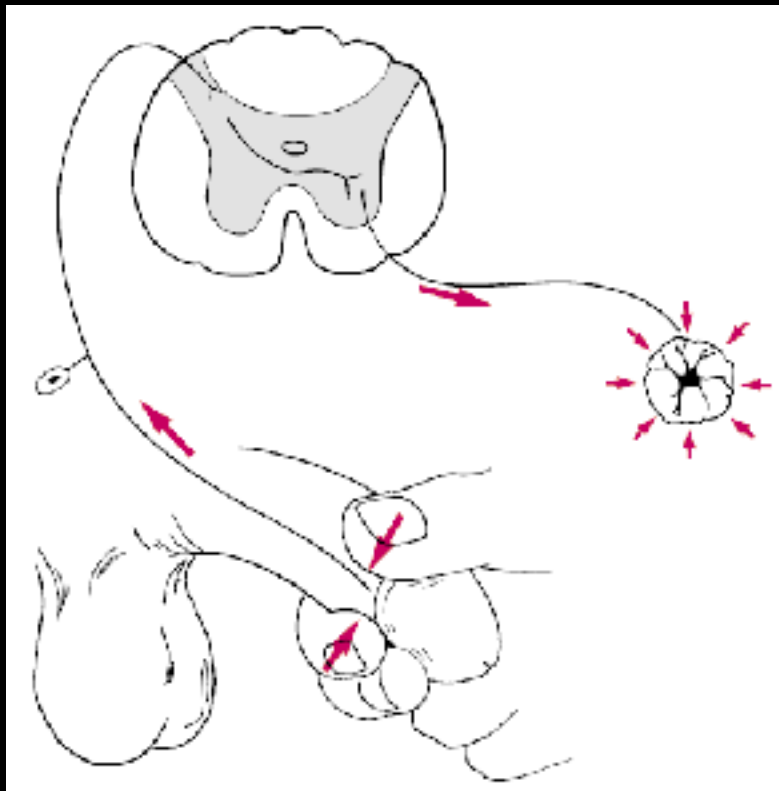
UE, Upper extremity; LE, lower extremity.

# Incomplete Cord Syndromes

Syndrome	Frequency	Functional Description	Recovery (%)
Central	Most common	Usually quadriplegic, with sacral sparing; upper extremities affected more than lower	75
Anterior	Common	Complete motor deficit; trunk and lower extremity deep pressure and proprioception preserved	10
Posterior	Rare	Loss of deep pressure, deep pain, and proprioception	
Brown-Séguard	Uncommon	Ipsilateral motor deficit; contralateral pain and temperature deficit	>90
Root	Common	Motor and sensory deficit in dermatomal distribution	30-100



# ΤΡΑΥΜΑΤΙΣΜΟΣ ΝΩΤΙΑΙΟΥ ΜΥΕΛΟΥ



ΒΟΛΒΟΣΗΡΑΓΓΩΔΕΣ  
ΑΝΤΑΝΑΚΛΑΣΤΙΚΟ

# ΔΙΑΤΗΡΗΣΗ ΡΙΖΩΝ ΙΕΡΟΥ ΠΛΕΓΜΑΤΟΣ

