
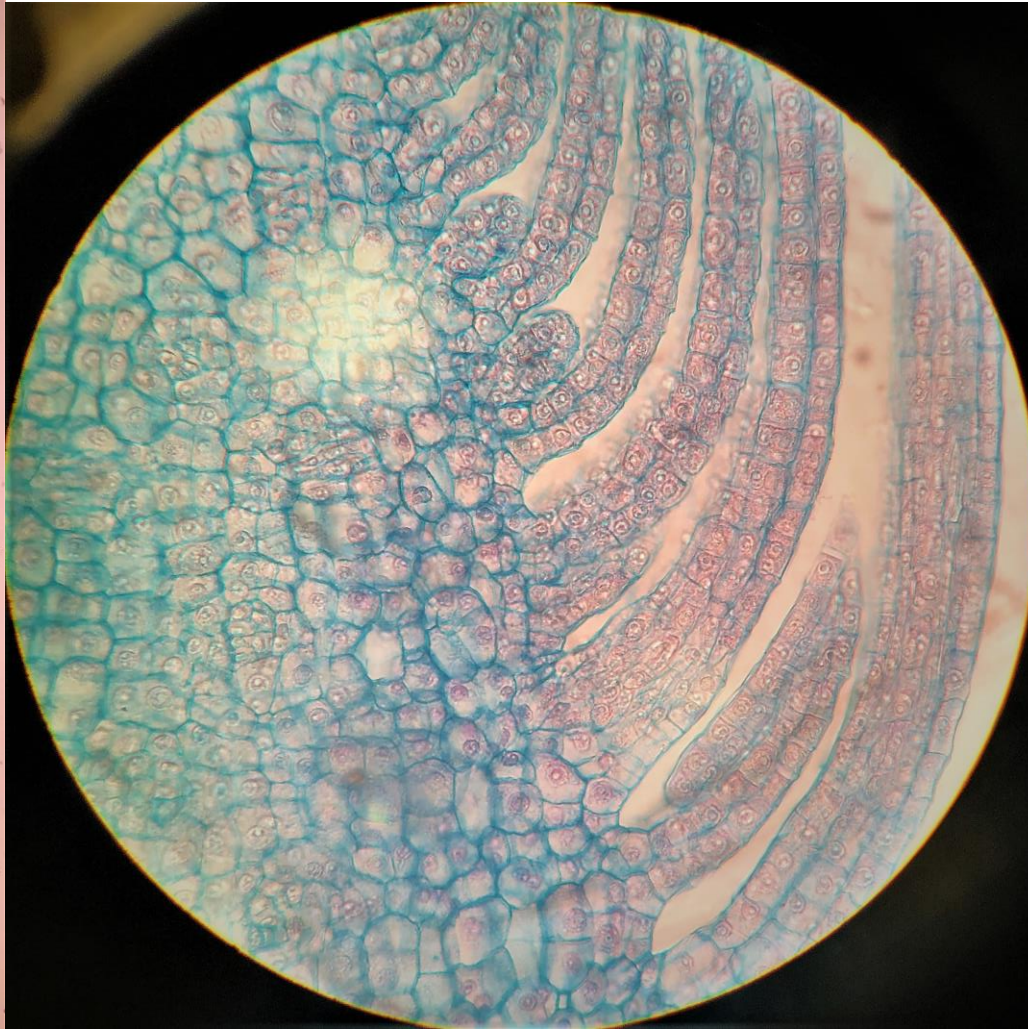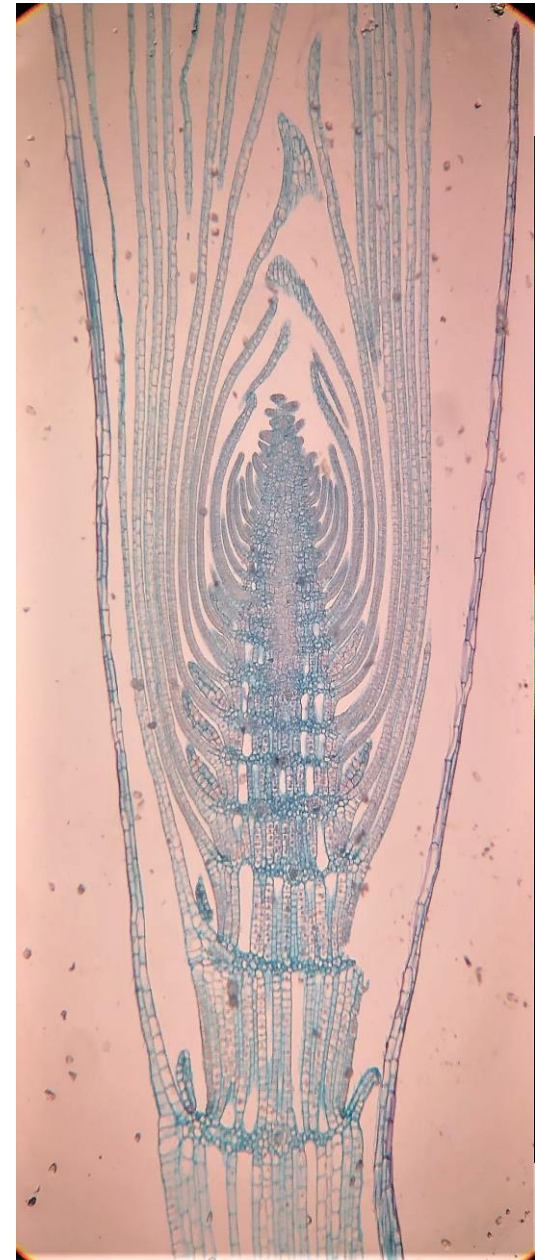


Εργαστηριακή άσκηση 6

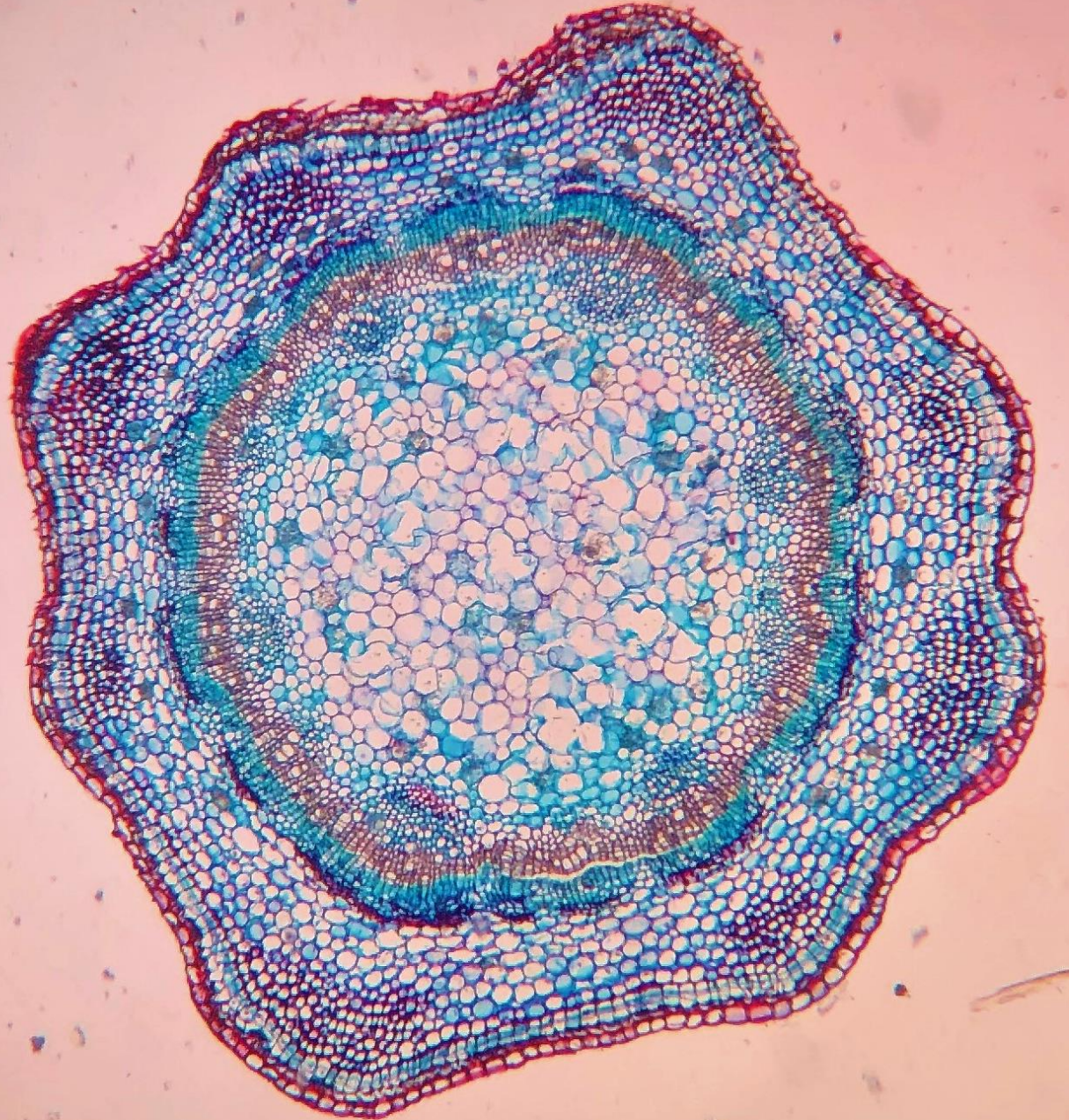Οι ιστοί και τα όργανα των  
σπερματοφύτων - Ο βλαστός

# Μεριστωματικοί Ιστοί ή Μεριστώματα (As121e)

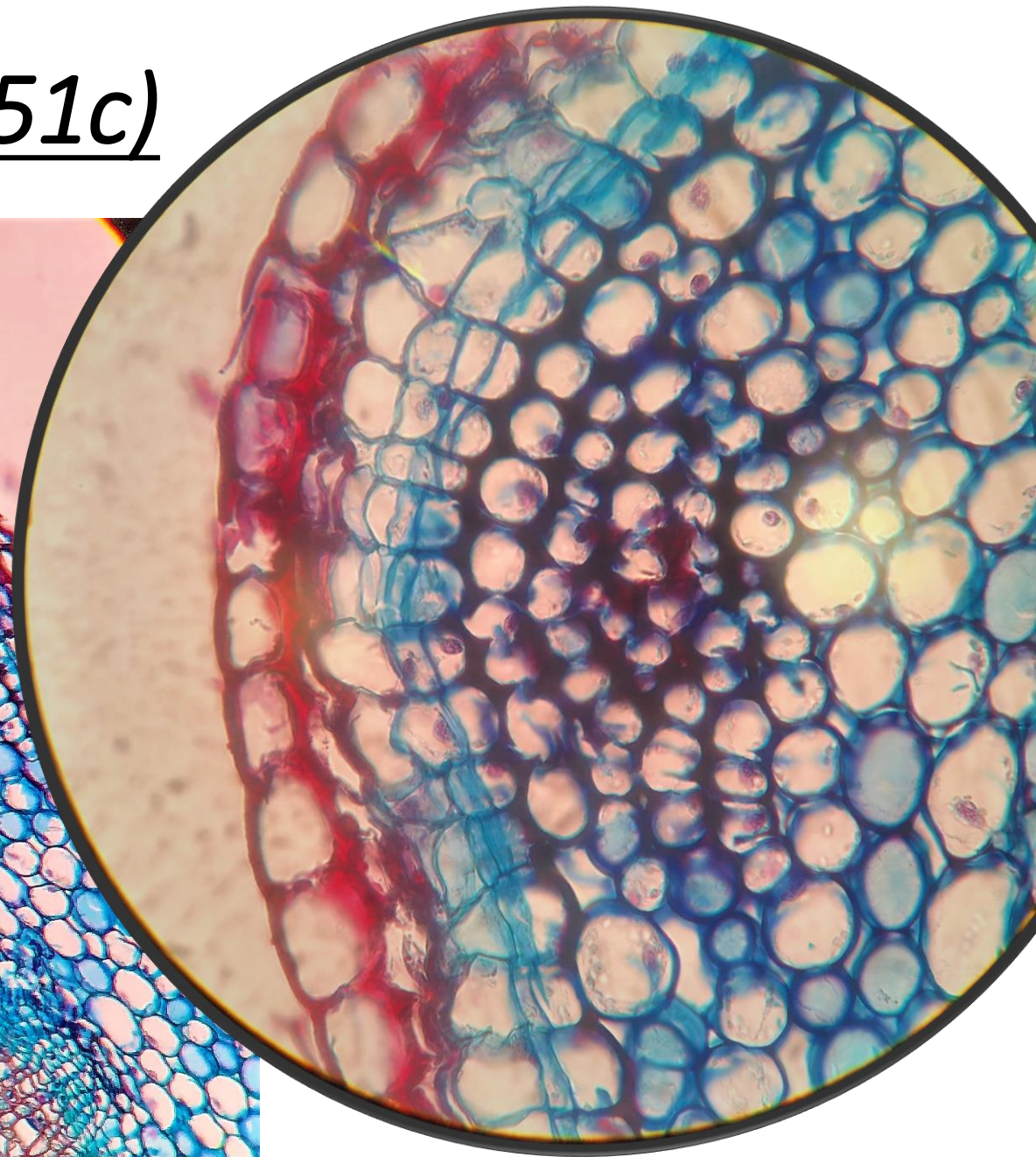
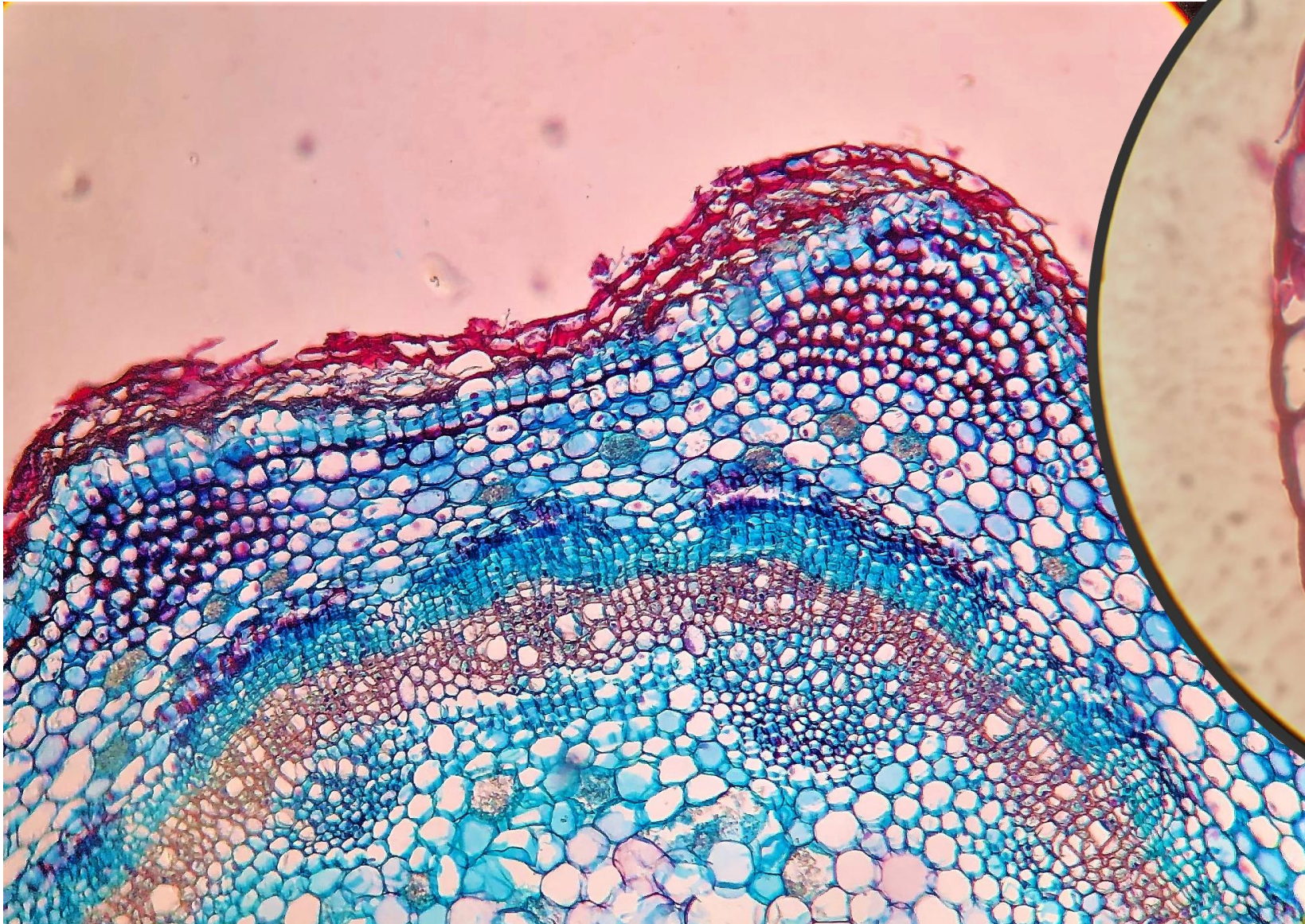


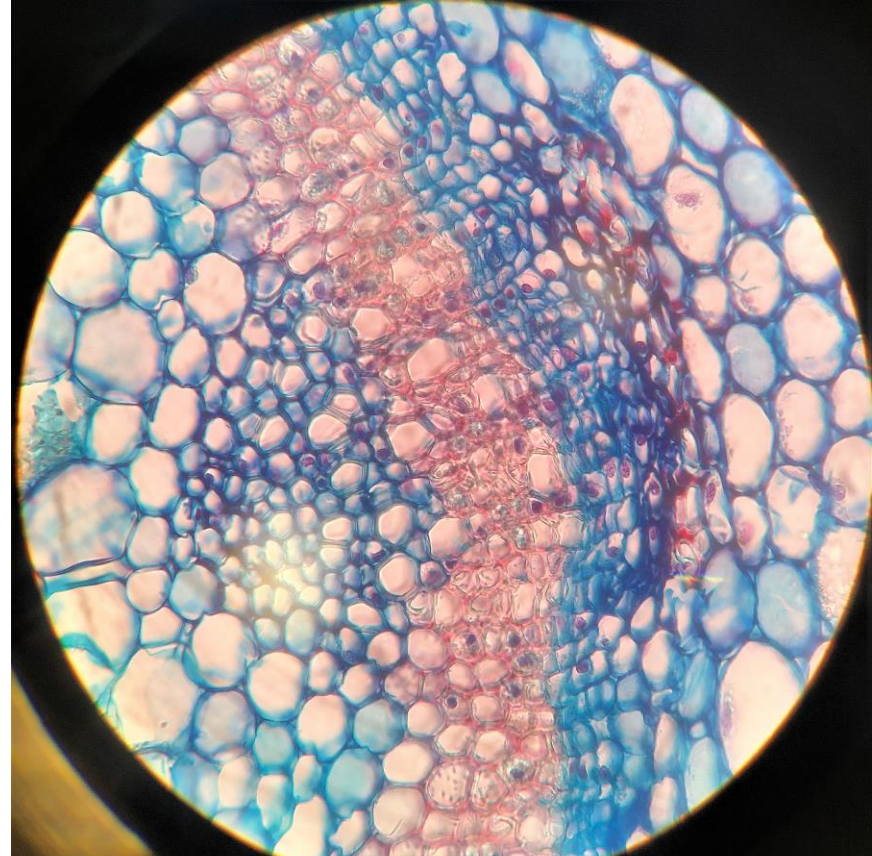
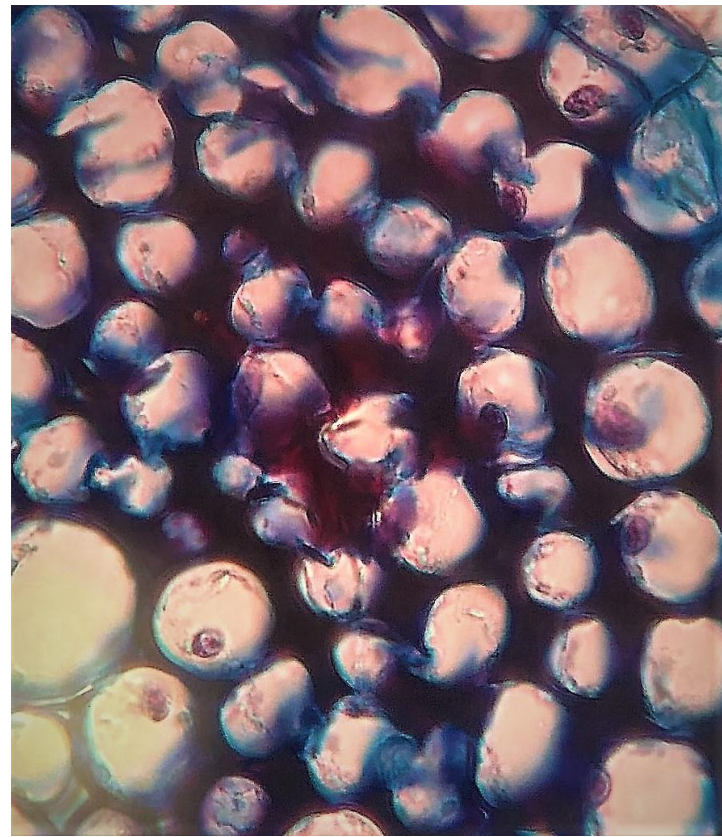
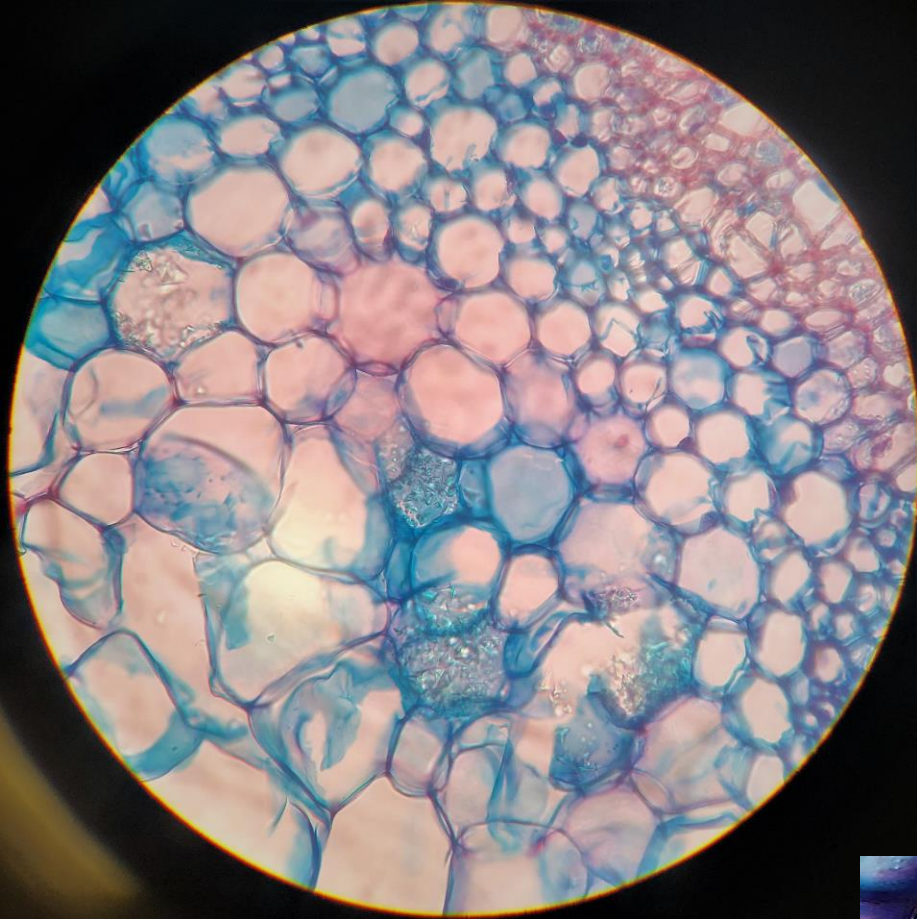# Μόνιμοι ιστοί

- Επιδερμικός ιστός ή επιδερμίδα
- Παρεγχυματικός ιστός
- Στηρικτικός ιστός
- Αγωγός ιστός

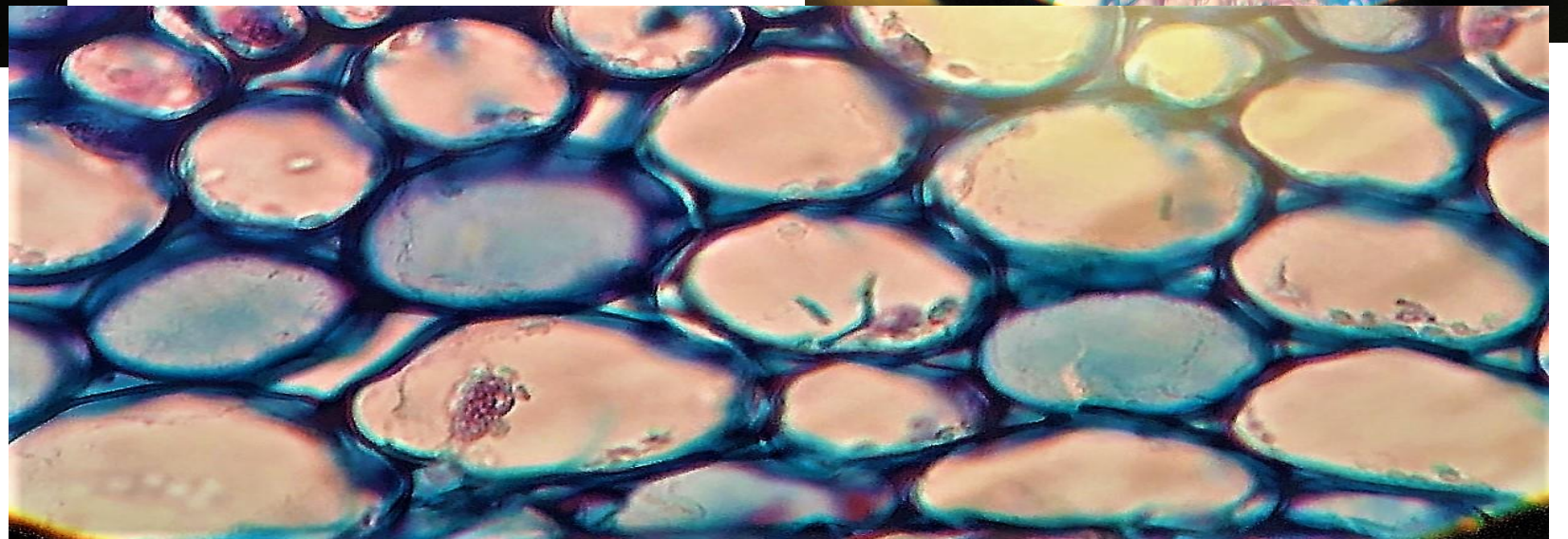


Τομή νεαρού βλαστού (As1451c)

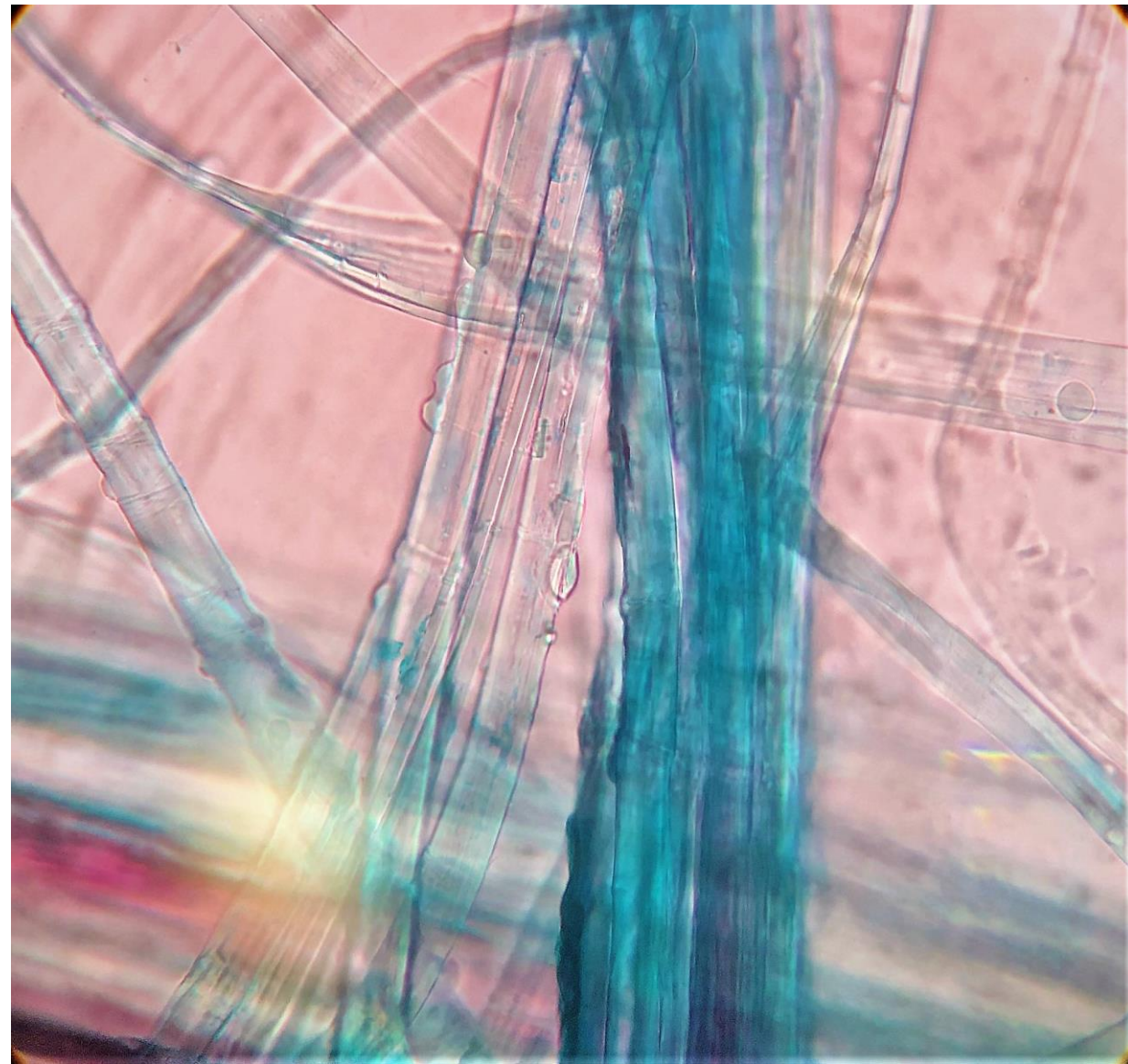
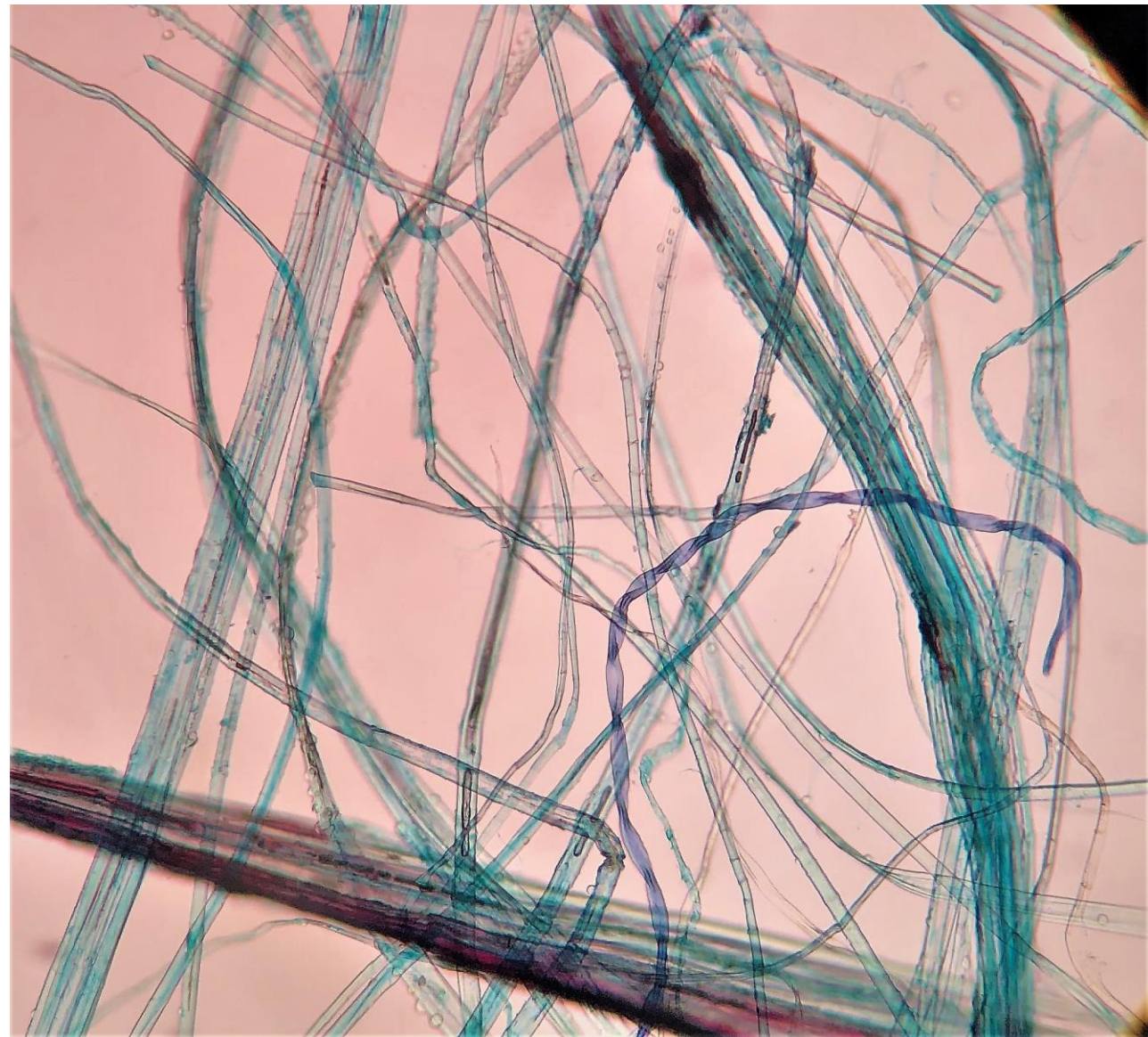


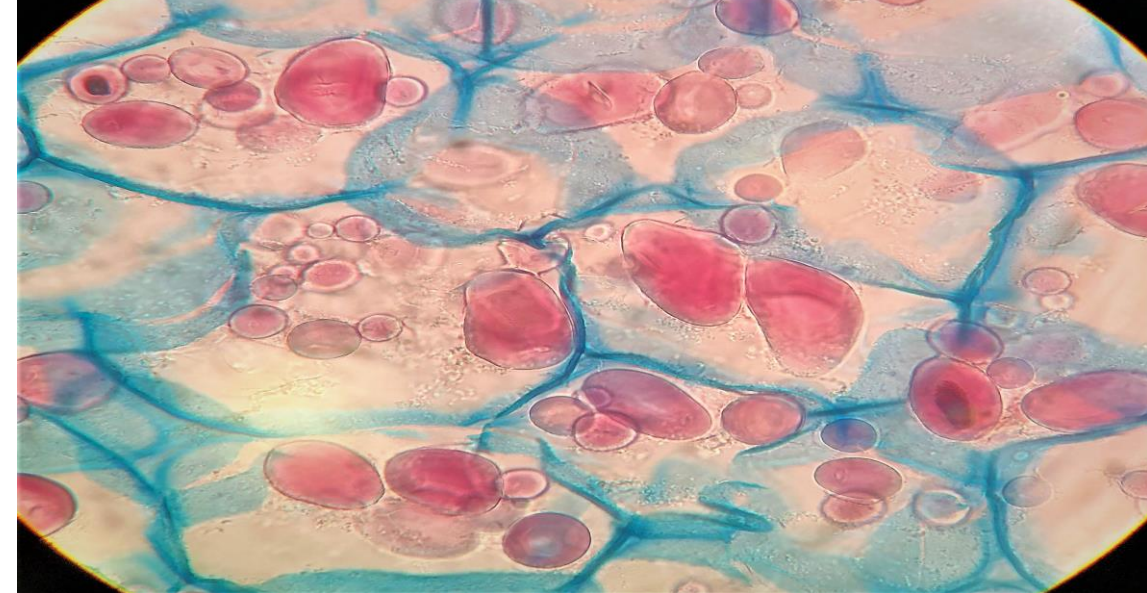


(As1451c)

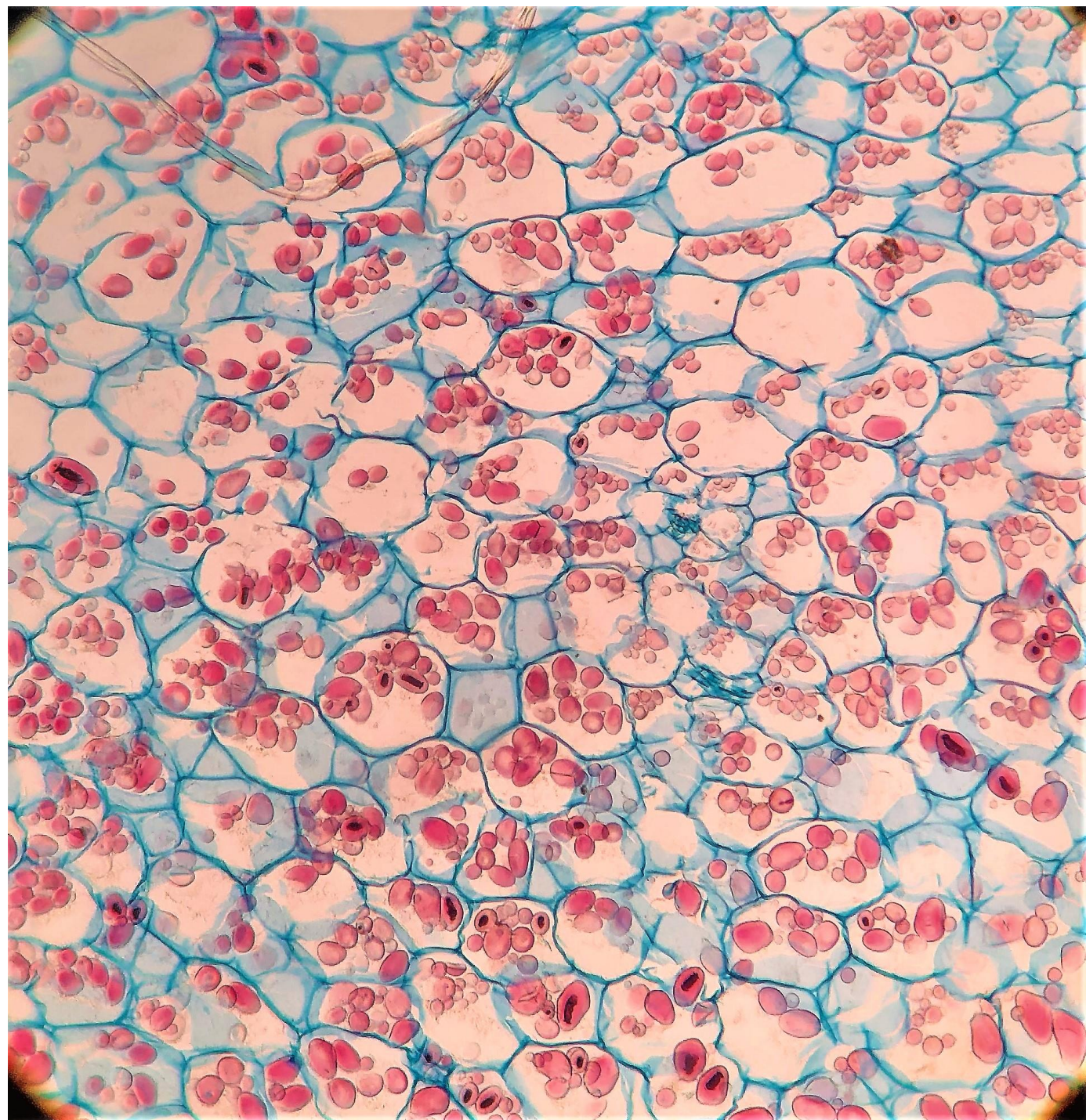
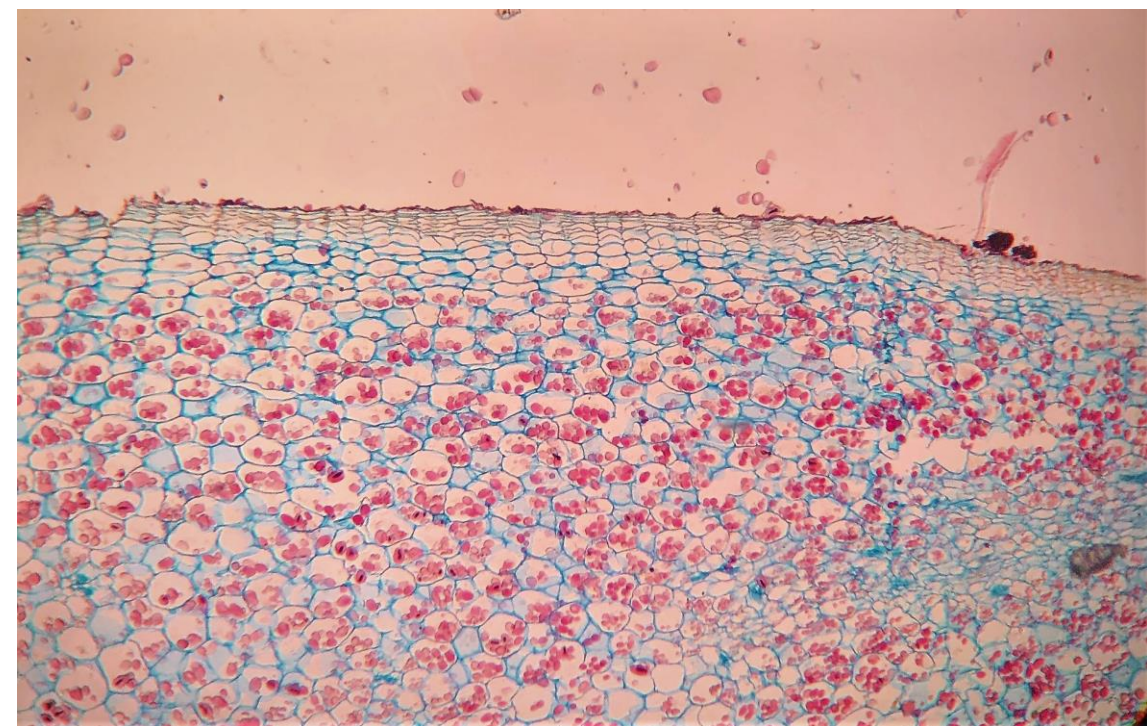


# Σκληρογχυματικές ίνες (As147b)





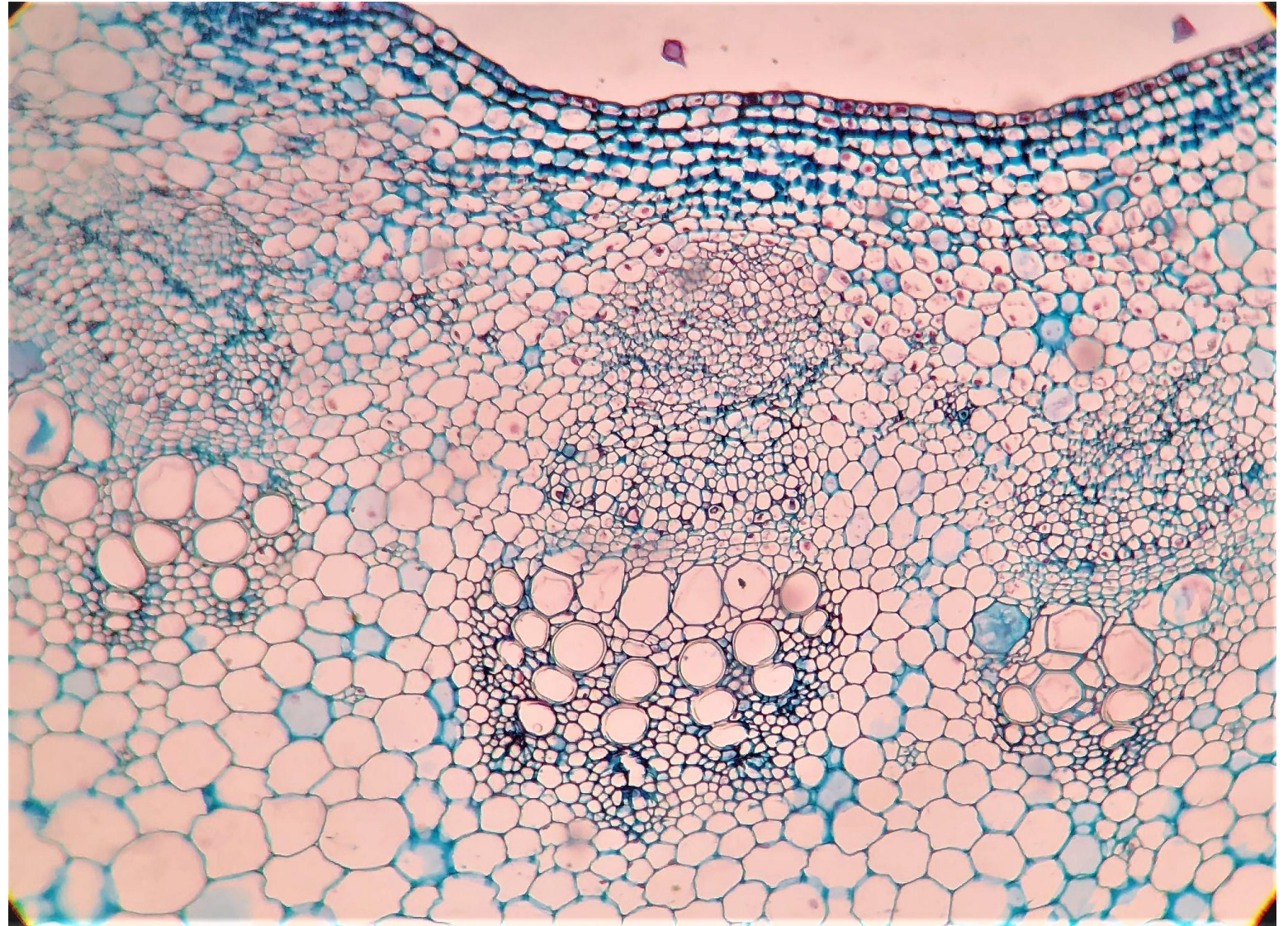
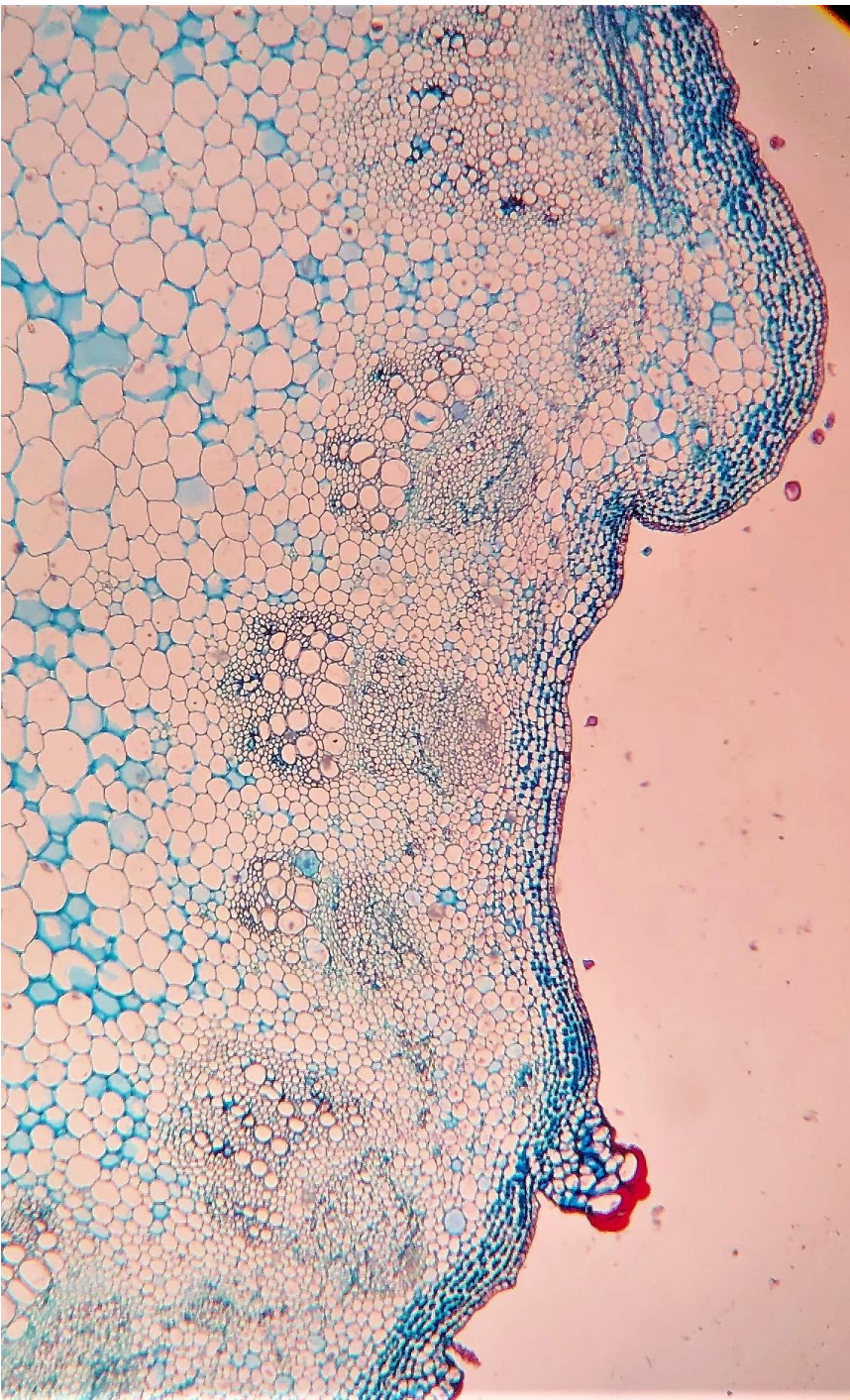
Παρέγχυμα πατάτας (As132c)



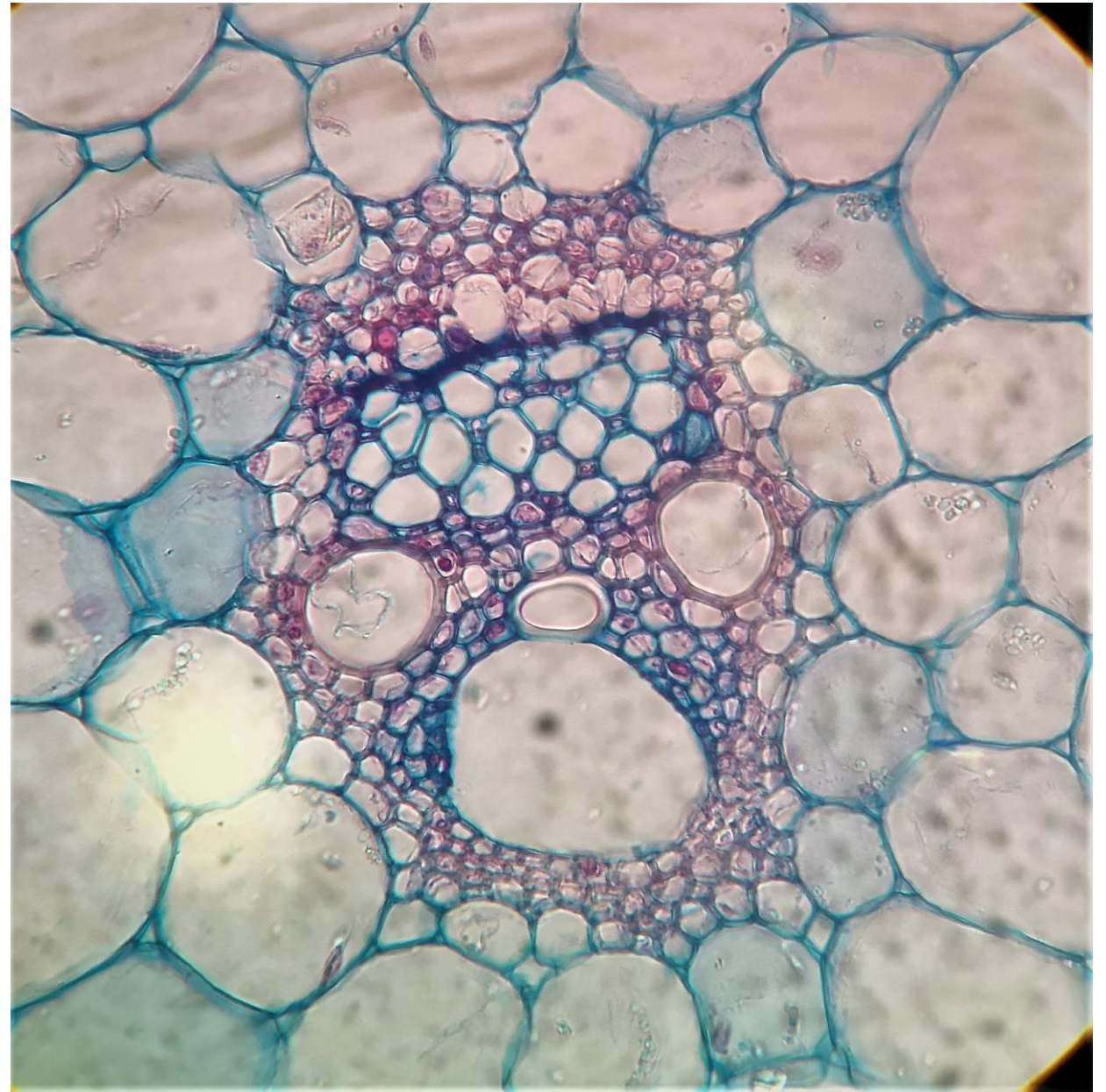
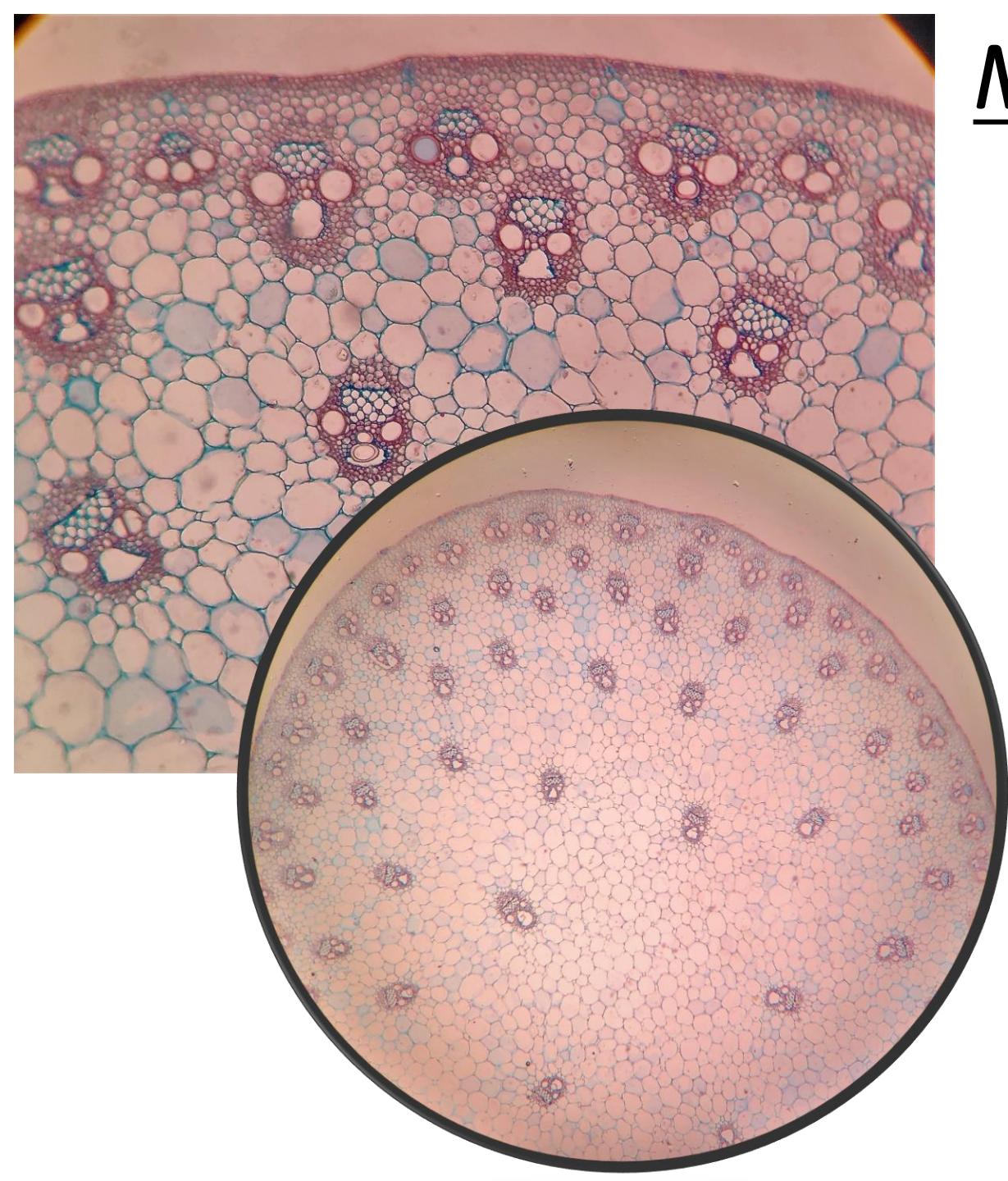
# Διαφορές δικότυλων-μονοκότυλων



# Δικότυλα φυτά (As343c)



# Μονοκότυλα φυτά (As311c)



# Δευτερογενής αύξηση (Gy125c)

