

Y

μ

·

2013-2014

1

- . PhD,
- 23, 24310-47015
- μ e-class
- . PhD,
- . PhD,

μ μ

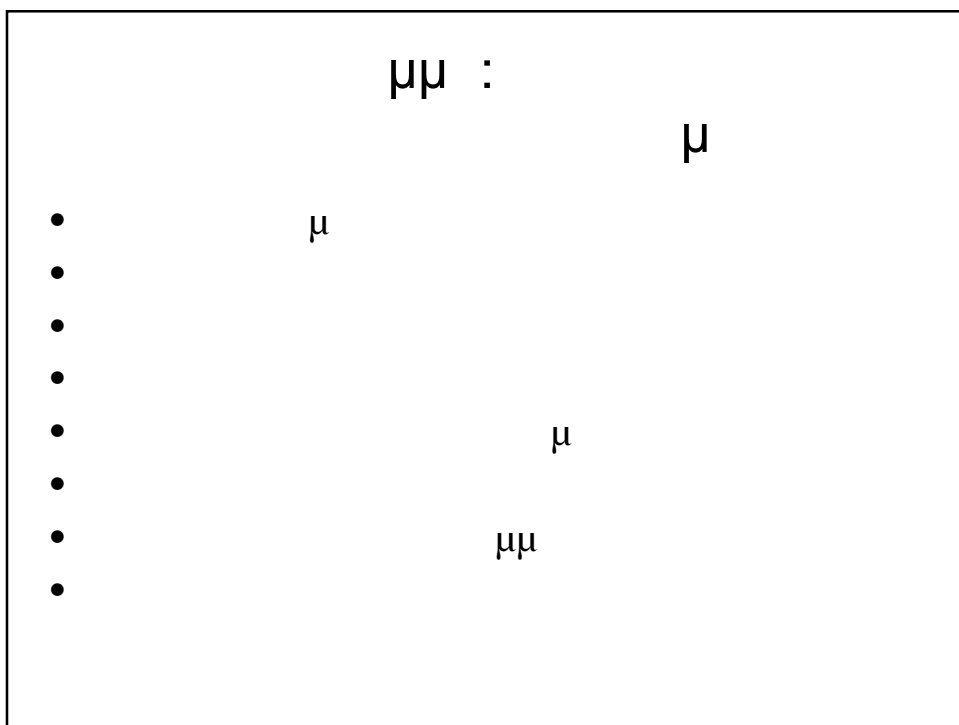
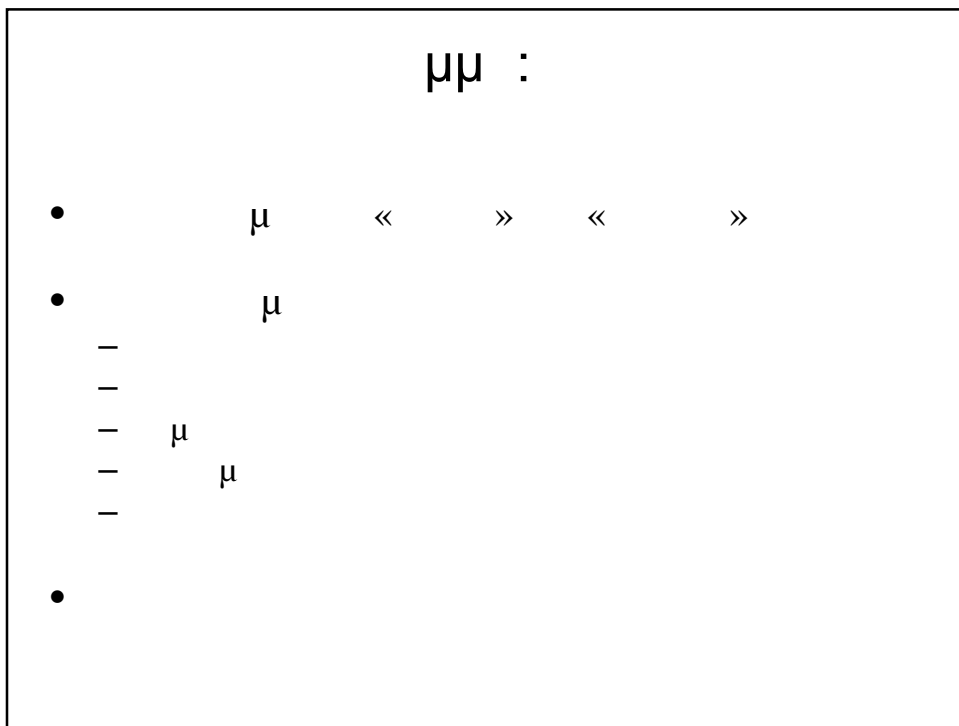
- :6
- : 0958
- :

- 13256873 erck - 3
Beers and Jones

- 12861054 Sharkey

‘ΕΙΔΙΚΟΙ ΟΜΟΙΟΤΗΤΕΣ - special populations

- ▶ ΗΛΙΚΙΩΜΕΝΟΙ - the elderly
- ▶ ΥΠΕΡΒΑΡΕΙΟΙ ΚΑΙ ΠΑΧΥΣΟΜΑΤΗ - overweight and obese
- ▶ ΠΑΣΧΟΝΤΕΣ ΑΠΟ ΧΡΟΝΙΑΣ ΠΑΘΗΣΗΣ - chronic disease patients
- ▶ ΓΥΝΑΙΚΕΣ - women
- ▶ ΠΑΙΔΙΑ - children
- ▶ ΑΤΟΜΑ ΜΕ ΑΝΑΠΗΡΙΕΣ - people with disability
- ▶ etc

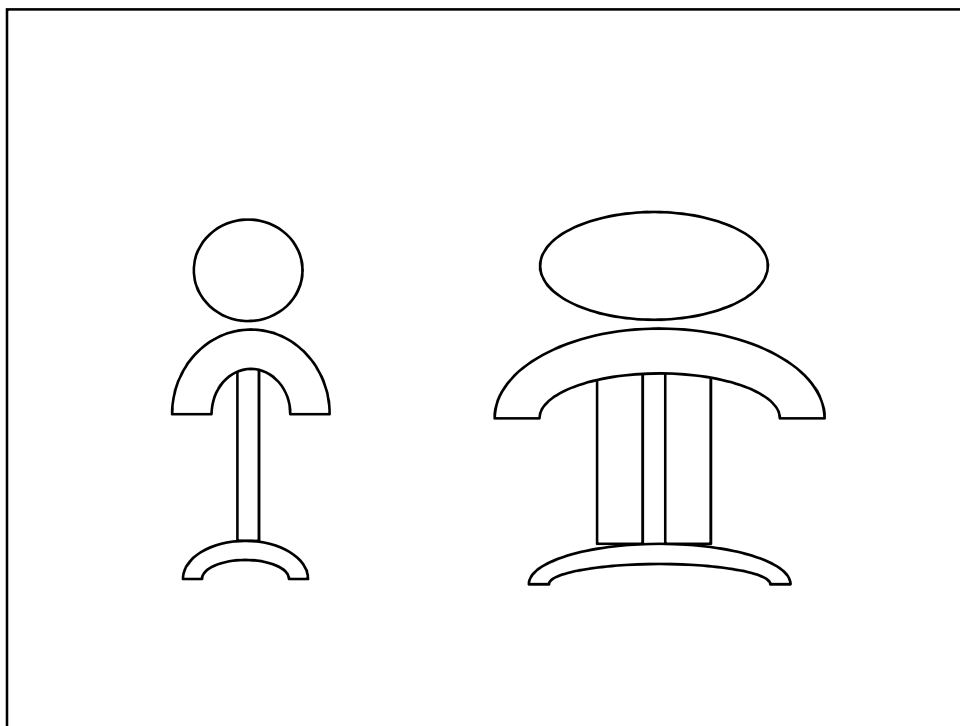


$\mu\mu :$

- μ ()
-
- $\&$
- μ
- μ
- $\mu - \mu\mu \mu$
- μ
-

$\mu\mu :$

- ;
- $\&$
-
-
-
- ;
-
-



μμ :



- μ μ
-
-
-
-
- μ
- μ
- μμ
- μ

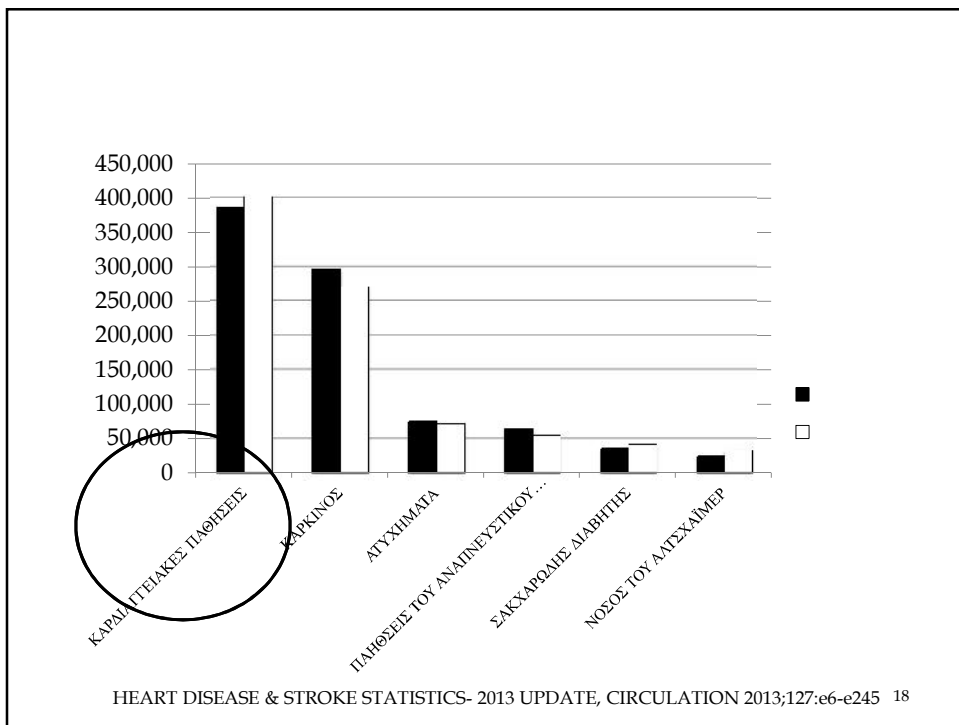

μμ :

- μ ;
- μ μ ;
- μ μ ;
- μμ
- μ μ

μμ :

-
-
- μ μ μ ,
- ()
- μ μ DEXA ()
- μ :
- T score = μ 30 (+1 -4)
- score = μ μ (+1 -4)
- BMD = bone mineral density – μμ (gr/cm)
- +1 =
- -1 =
- -1 -2,5 =
- -2,5 =





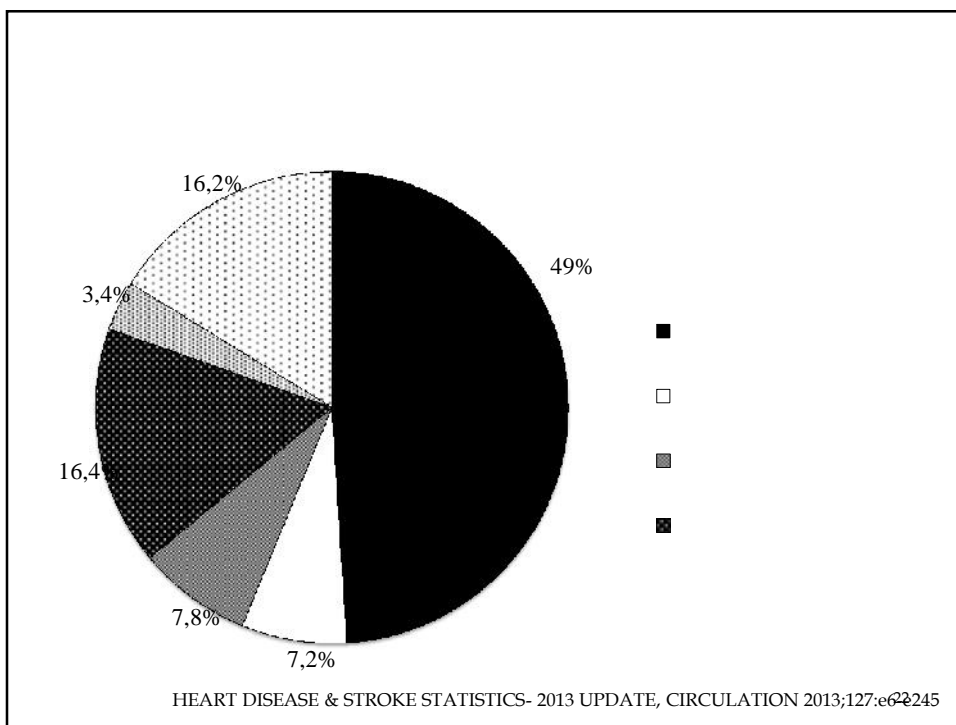
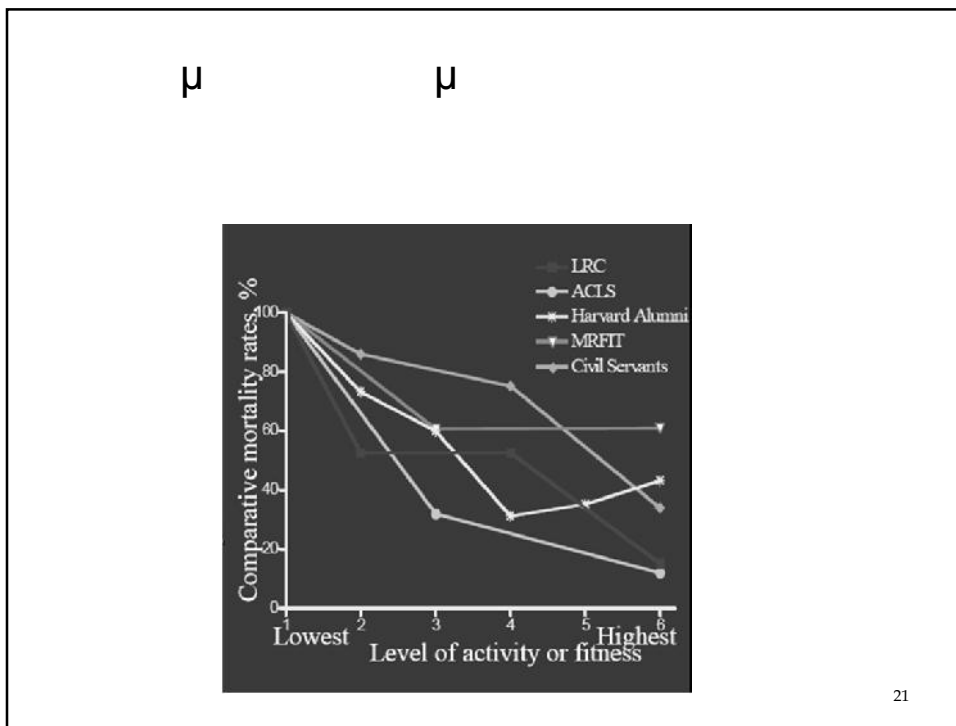
-
- 25 . 2020
- 6-
HIV/AIDS
- 4
- 5

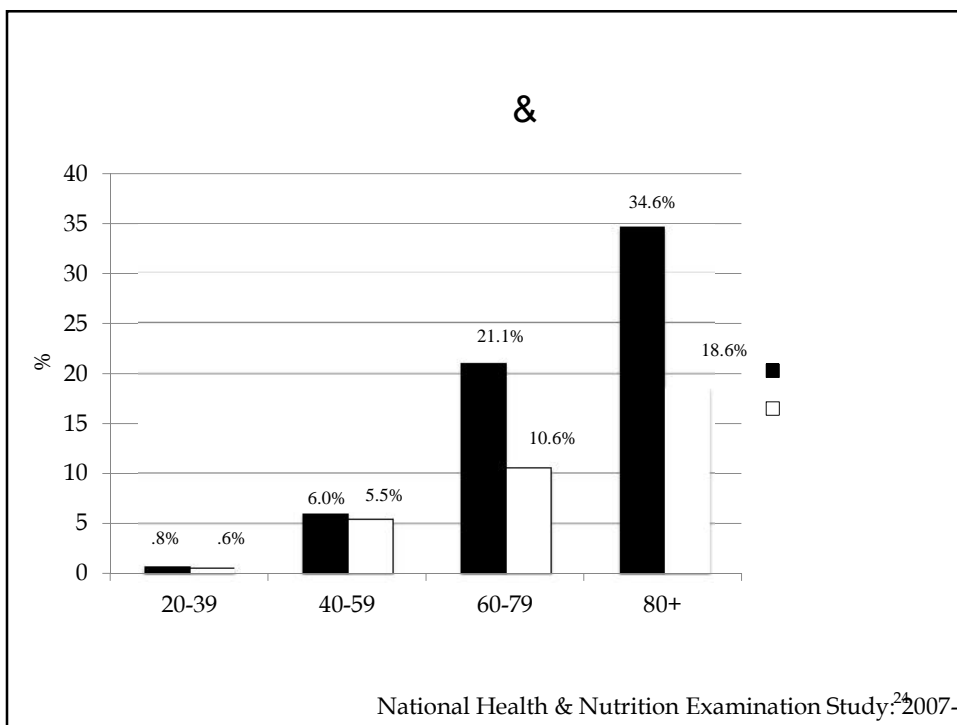

19

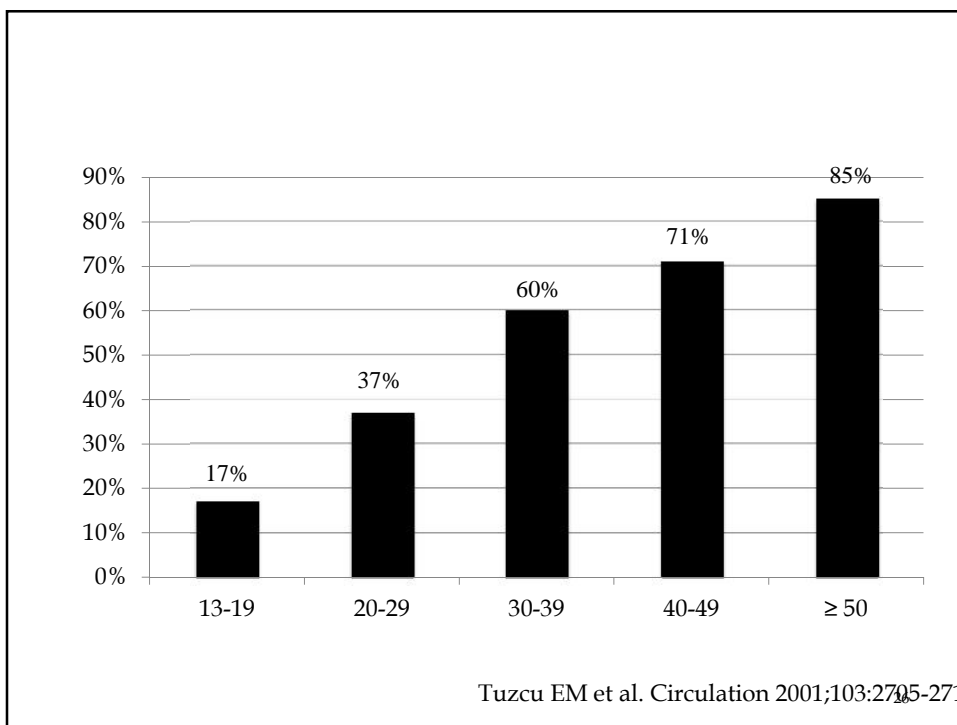

- ✓
-
- LDL
- HDL
-
- ✓
- ✓
- ✓
- ✓


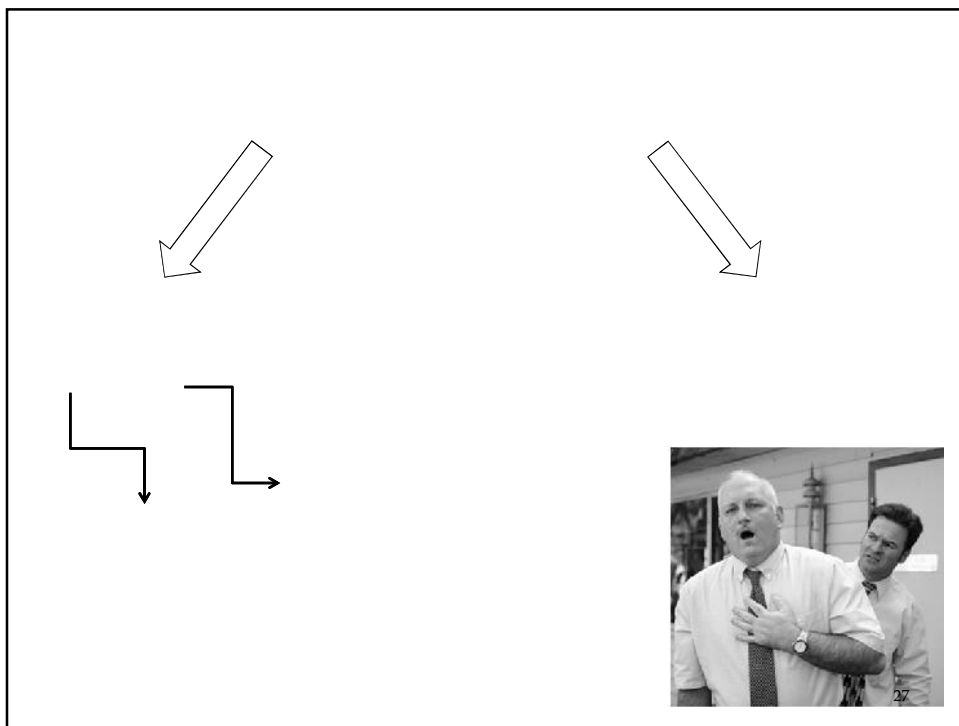
- ✓
- ✓
- ✓

20










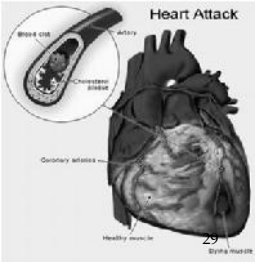
-
-
-
-

)

&

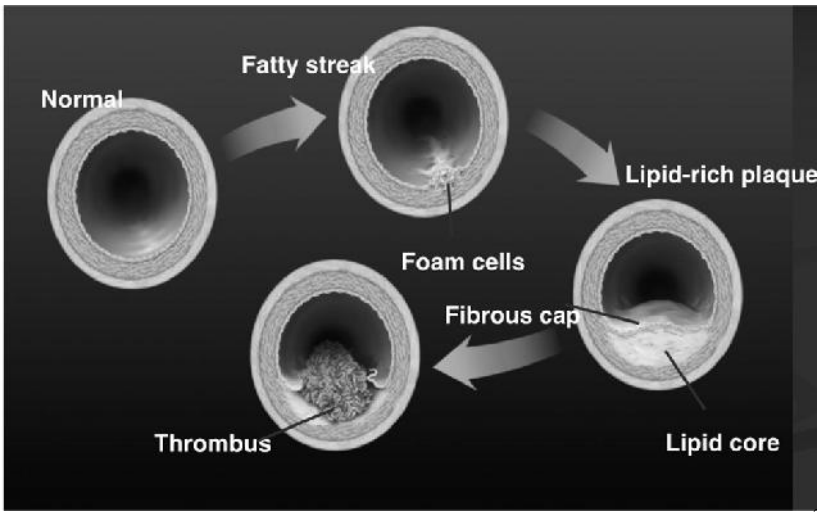


Αρτηρία της καρδιάς με πλήρη έμφραξη (πλάκα από συσπαστικό πηχρωτό αίματος (θρόμβου) σε περιοχή με βλάβες αθηροσκλήρωσης. Η περιοχή της καρδιάς που αρδεύεται με αίμα από την συγκεκριμένη αρτηρία παθαίνει μόνιμη βλάβη (μυρραγία μυοκαρδίου).



Heart Attack

Block site
Artery
Coronary artery
Healthy muscle



Normal

Fatty streak

Lipid-rich plaque

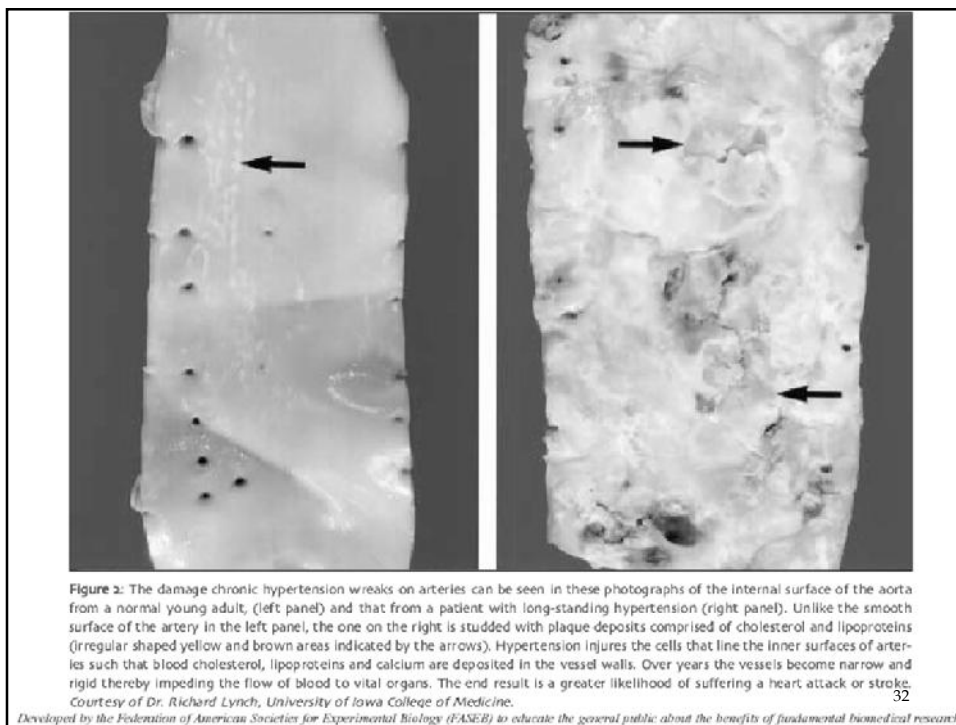
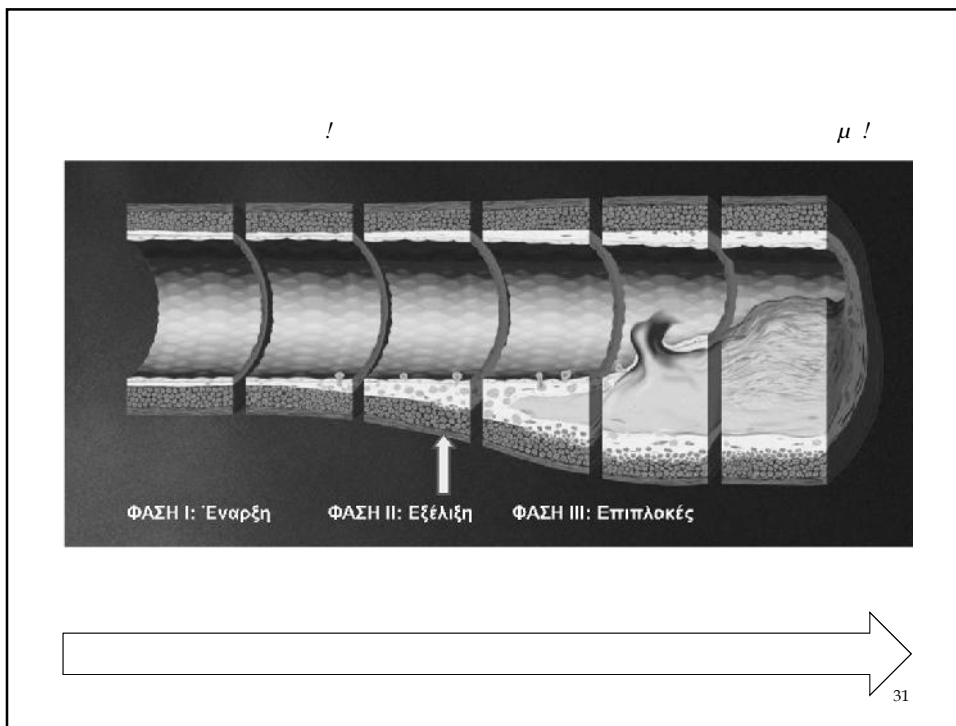
Foam cells

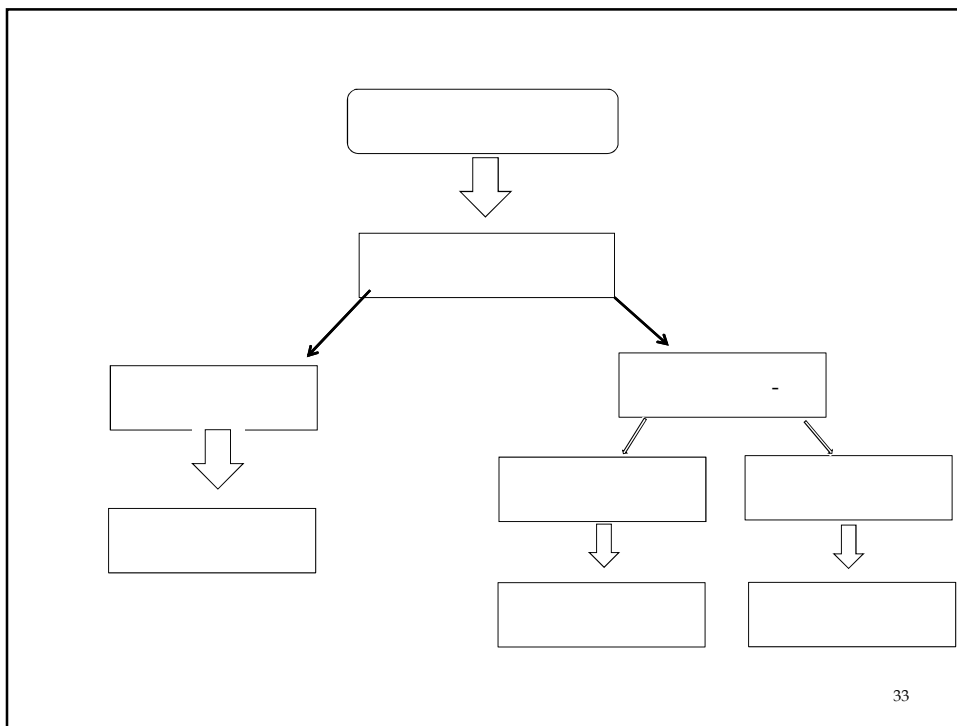
Fibrous cap

Lipid core

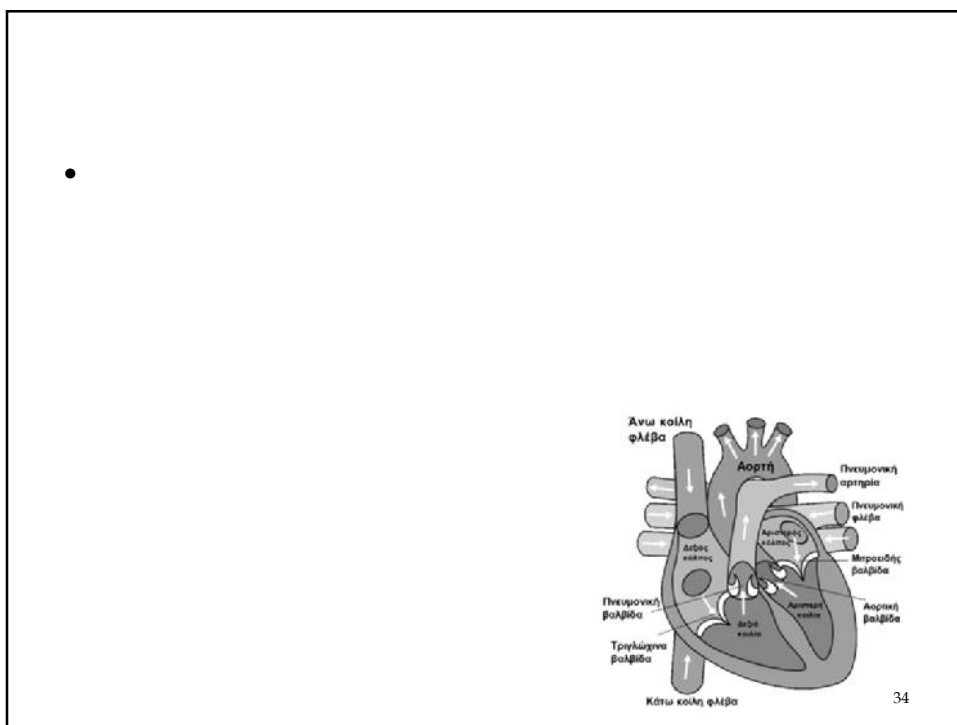
Thrombus

30





33



34

